

THE POWER OF FJO

**Functional Jaw Orthopedics
& Orthodontics**

YOU TOO can achieve these results in your general practice

Examples of actual patients treated by
GENERAL DENTISTS using the services of
RIDEAU ORTHODONTIC for **COMPREHENSIVE**
Functional Jaw Orthopedic Treatment
PRIOR to fixed bracket therapy or any
Invisalign™ template type treatment

- NON-SURGICAL
- NO BICUSPIDS EXTRACTED
- AVERAGE TREATMENT TIME 18 MONTHS!

WHY REFER YOUR PATIENTS AND INCOME?

ONLY ONE PATIENT per week at \$5,500 x 48 wks = \$264,000
Average *Full Lab Fees \$1,500 per patient x 48 = \$72,000

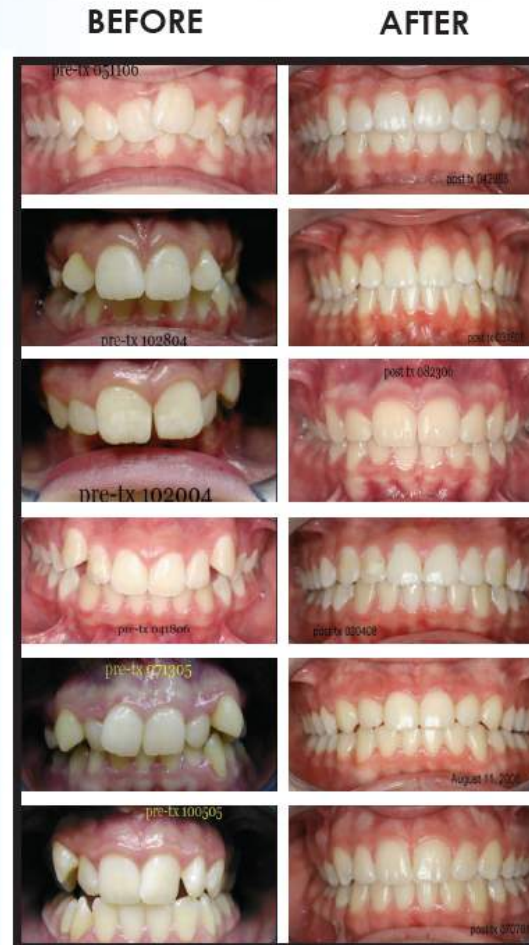* Includes: Case Evaluation, Cephalometric Tracing, Study Models,
FJO Devices, Indirect Brackets/Archwires & Retainers

Average Chair Time Income over 18-24 months:
\$4,000 per patient x 48 = \$192,000

Average visits per patient:

Class I crowded (30%) 10-15 visits over 18-24 months
Class II crowded (70%) 15-20 visits over 18-24 months

REFER difficult cases, surgical cases
or if you anticipate compliance issues.



**Serving the dental
profession since 1972**

www.orthodontic.ca

Rideau Orthodontic Mfg. Ltd.

CONSISTENT, QUALITY, RELIABILITY

Serving the Dental Profession
Since 1972

HOME LABORATORY SUPPLIES EDUCATION **CASE EVALUATIONS** PRESENTATIONS FEEDBACK LINKS

A UNIQUE DETAILED HYPOTHETICAL
CASE EVALUATION SERVICE



Links

- ▶ You Too Can Achieve These Results
- ▶ Records Required
- ▶ Pre-Evaluation Questionnaire
- ▶ Mx Space Shortage Analysis
- ▶ TMJD Questionnaire
- ▶ FORMS
- ▶ Informed Consent
- ▶ Crowded Teeth
- ▶ 2nd Molar Replacement
- ▶ 2nd Molar Tx by an Orthodontist
- ▶ Compliance
- ▶ Ortho-Grid
- ▶ Photo-Grid
- ▶ Range of Motion
- ▶ Disclaimer

Each request for a Case Evaluation requires complete patient records including a
Pre-Evaluation Questionnaire

General Dentists who wish to correspond electronically must provide all records by e-mail to lab@orthodontic.ca using the format outlined under

▶ Records Required



griffiths@orthodontic.ca

One method of communication
is appreciated for New and Ongoing Cases (by e-mail or via the laboratory)

Each request will be reviewed by

Emmett Griffiths, President of Rideau Orthodontic Mfg. Ltd.

A typed response based on 43 years of experience will be provided.

**ALL DENTAL DEVICES ARE LASER WELDED TO ELIMINATE TOXICITY
FROM THE EROSION CAUSED BY UNRELIABLE SOLDER JOINTS**

CLEARBOW RETAINERS...FIXED or REMOVABLE EXPANSION...ALF...INDIRECT BRACKET TEMPLATES...
INDIRECT TRIPODING FOR VERTICAL... TMJD SPLINTS...CUSTOM NIGHT GUARDS/MOUTHGUARDS...THERMO-GUARD™...
ANTI-SNORING/BRUXING...POSITIONERS...STUDY MODELS...CEPHALOMETRIC ANALYSIS...EDUCATIONAL VIDEOS

The Importance of Functional Jaw Orthopedics PRIOR to Fixed Brackets or Invisalign® type treatment

A number of clients have expressed an interest in coordinating Orthopedic/Orthodontic Study Club Groups of approximately 10 dentists to share information/treatment planning.

I could offer my one-day program including group discussions using projection of records.

If you are interesting in organizing a group, please contact me directly at griffiths@orthodontic.ca



General Dentist Case Presentations

All case presentation slides are displayed with permission by the doctor(s) and patients.

Replication or distribution of this material is strictly prohibited.

Rideau Orthodontic Mfg. Ltd.

69 Beckwith Street, North Smiths Falls, ON Canada K7A 2B6

1-800-267-7982

www.orthodontic.ca
orthodontic@orthodontic.ca

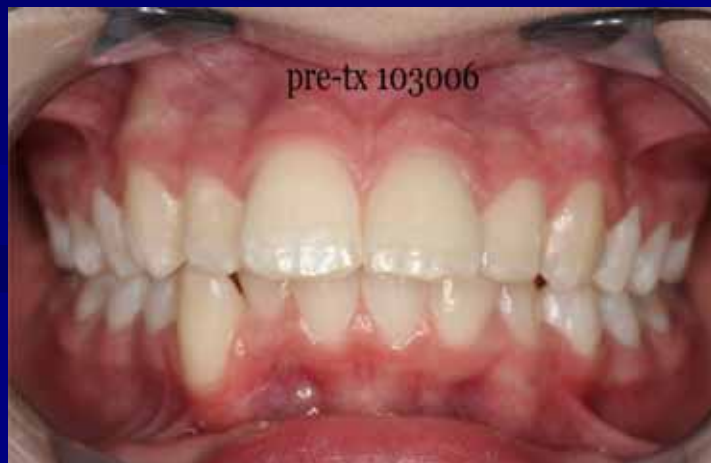Emmett Griffiths, President
griffiths@orthodontic.ca

Serving the dental profession since 1972

Class I Molar Twin Block Treatment

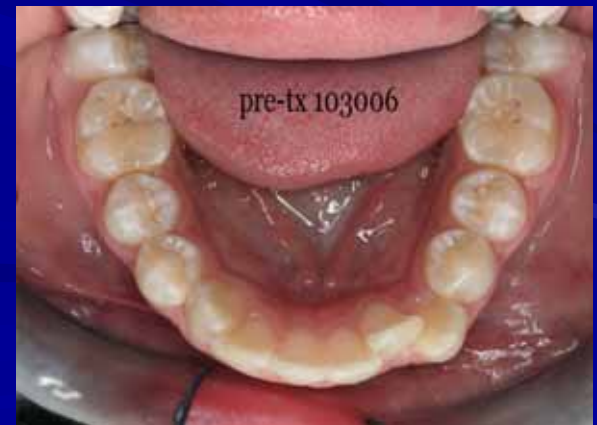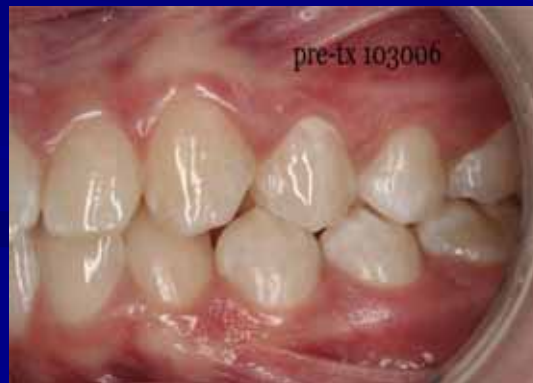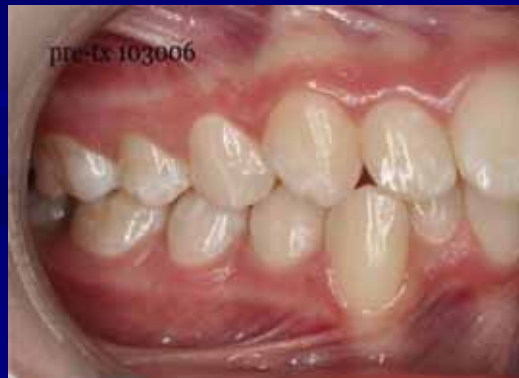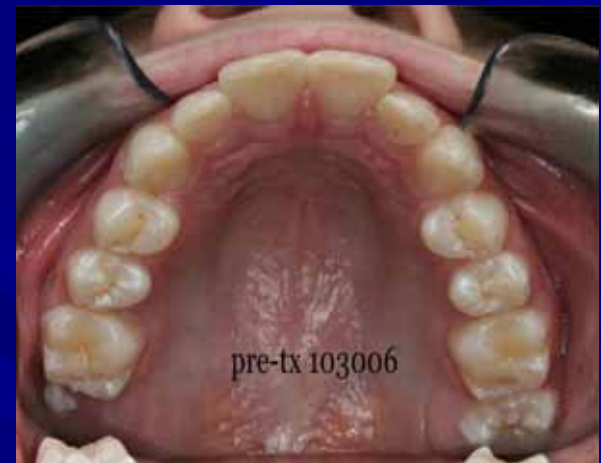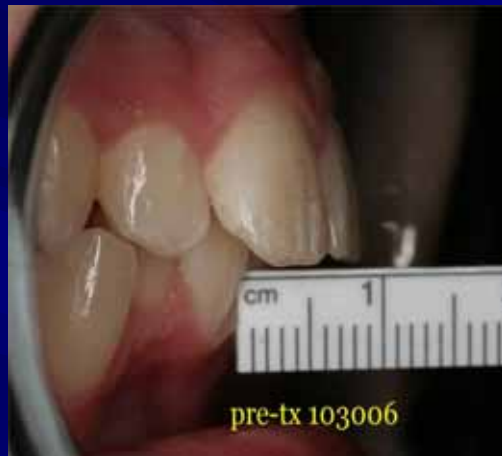Class I

Scotia: 12 years of age



- Class I full tooth
- Overjet 5 mm
- Overbite 30%
- Class I facial profile

Class I Full Tooth Scotia: 12 years of age Pre-treatment



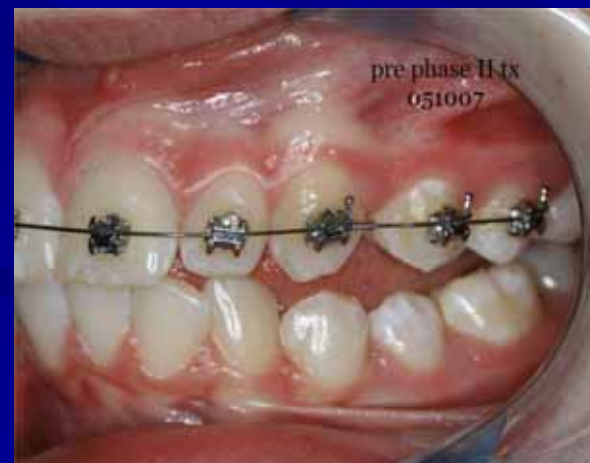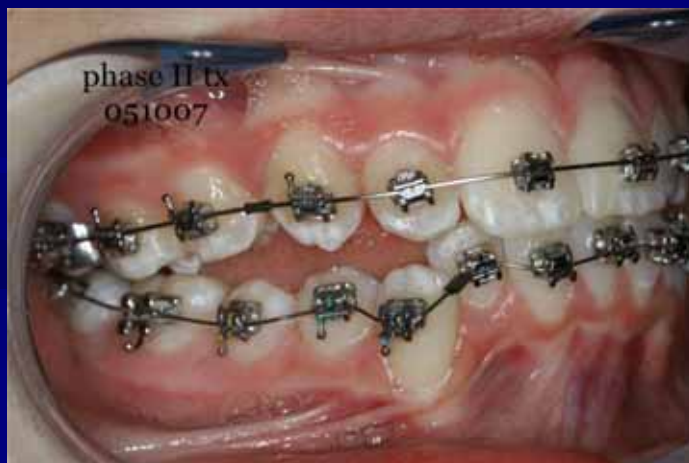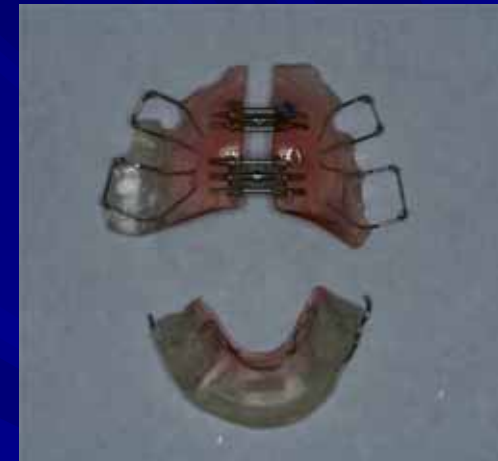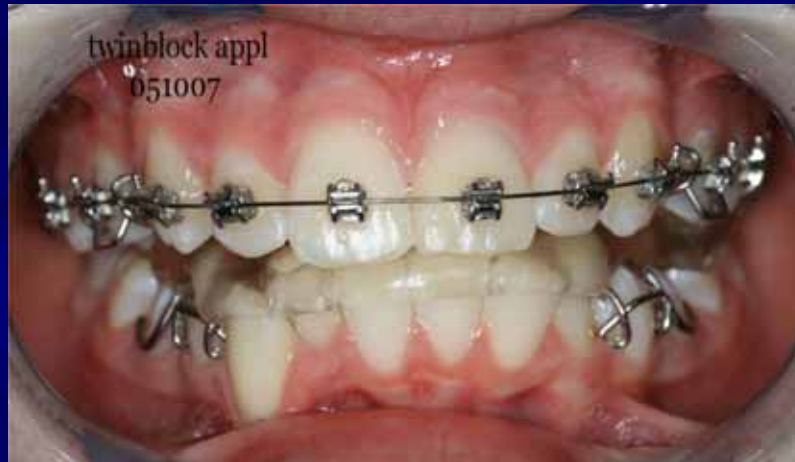Class I Full Tooth

Scotia: 12 years of age

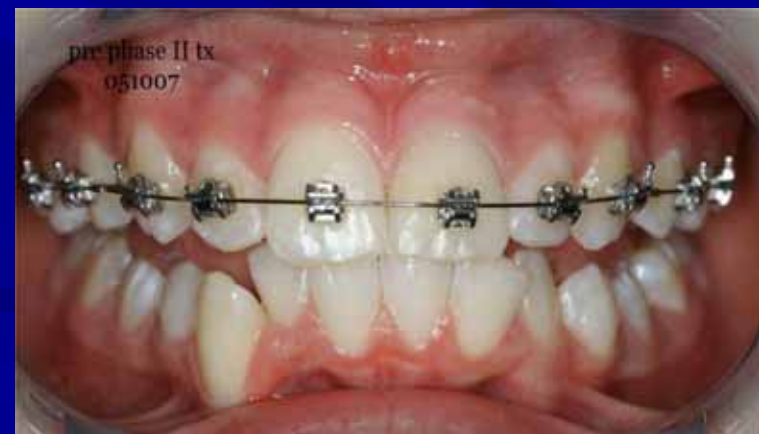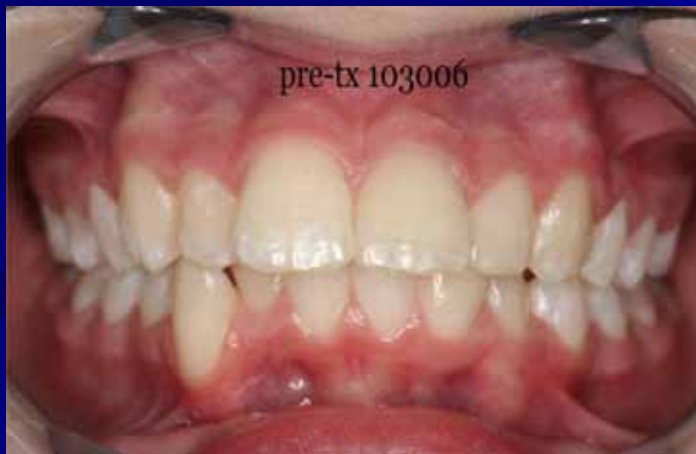Pre-treatment



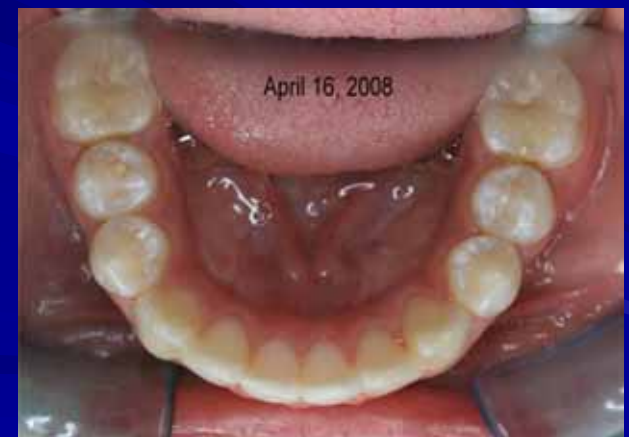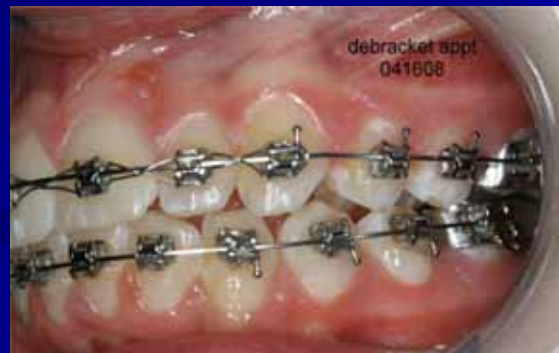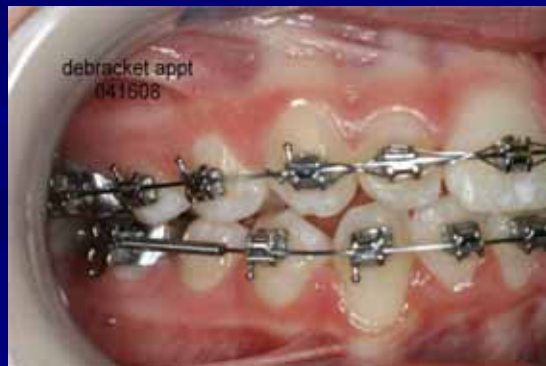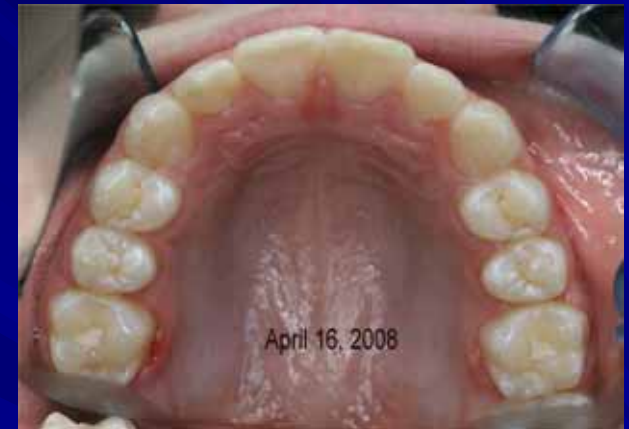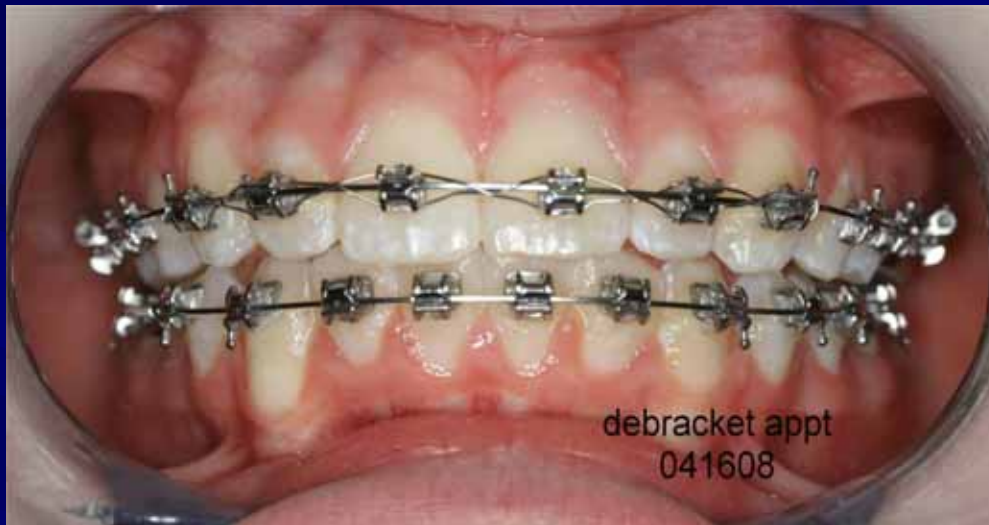Scotia: Mid treatment Post Twin Block 5 month active wear



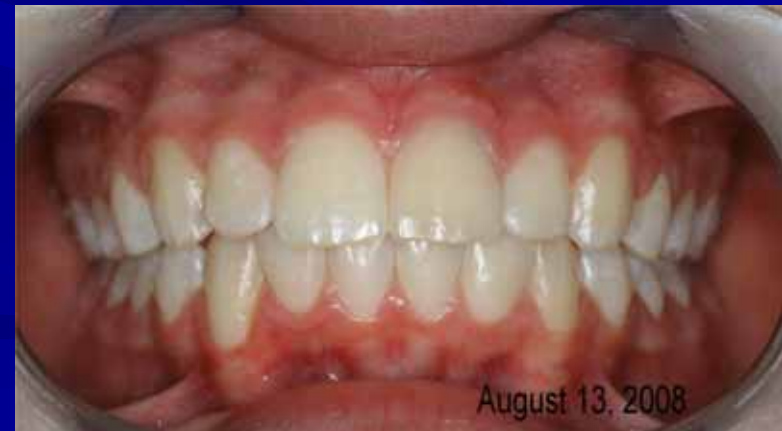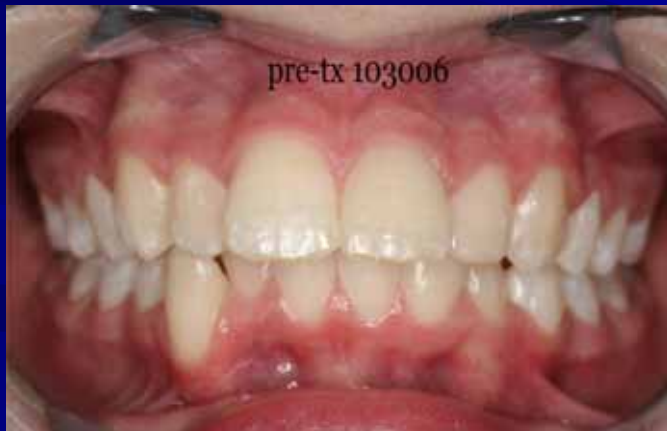Scotia: Pre & Mid treatment



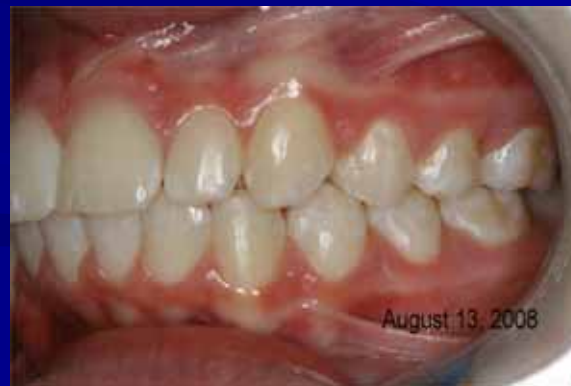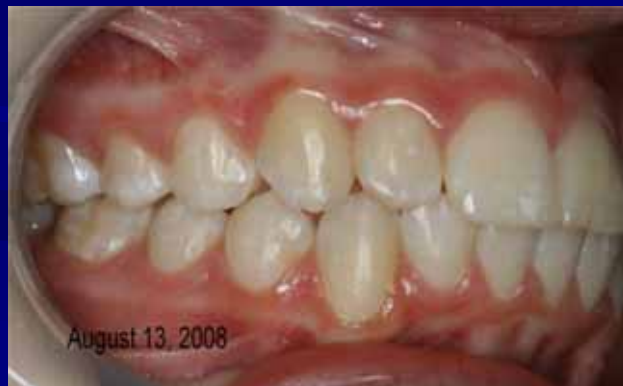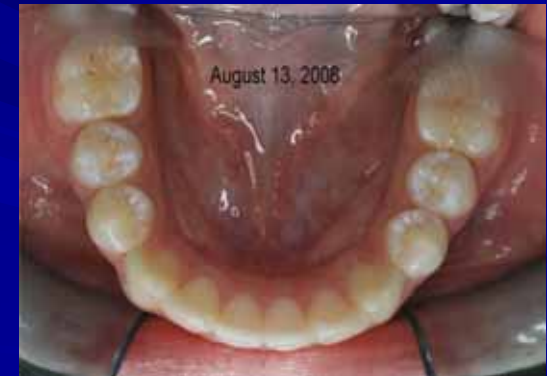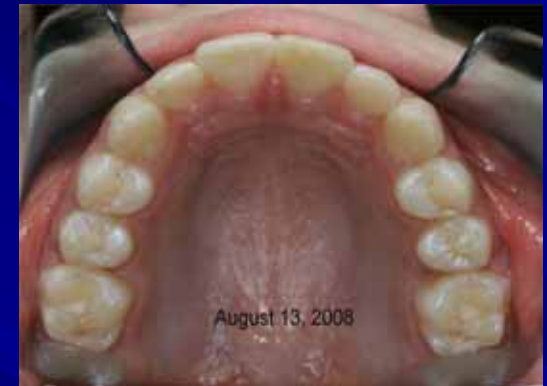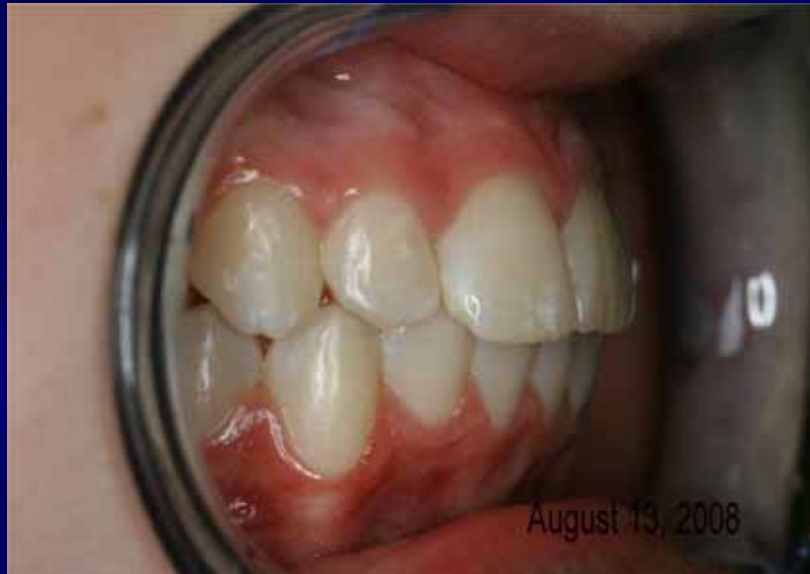Scotia: 11 months full bracket Tx



Scotia: 16 months active Tx

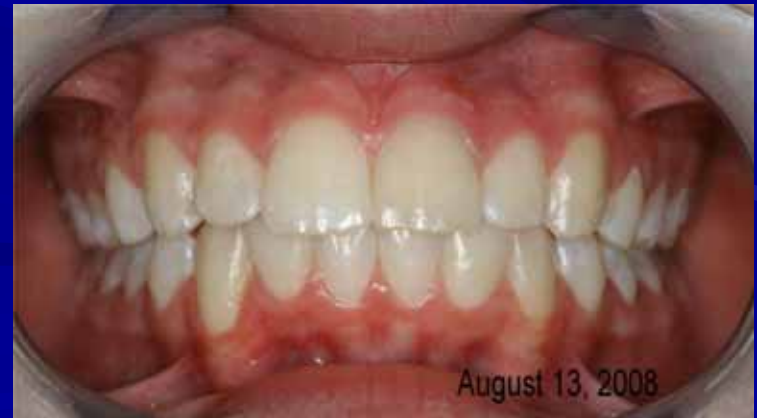

Scotia: Post Treatment



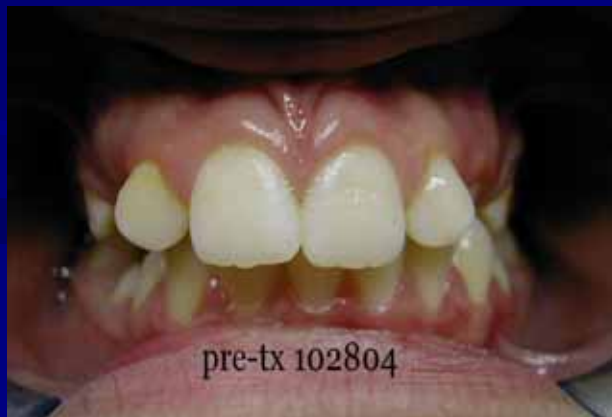Scotia

- Twin Block with upper brackets 5 months
- Full brackets/upper TPA 11 months
- Positioner for retention
- May 2008 modeling contract in Toronto



Class I

Jenna: 11 years of age

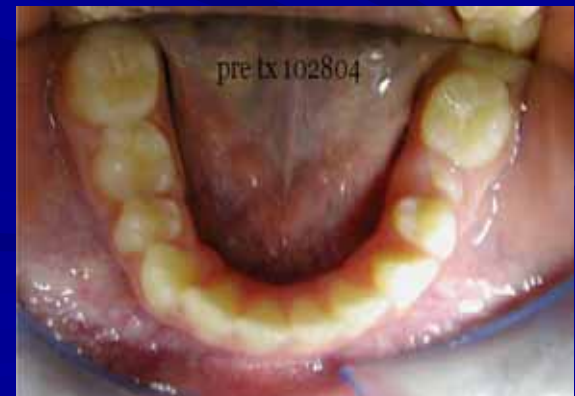
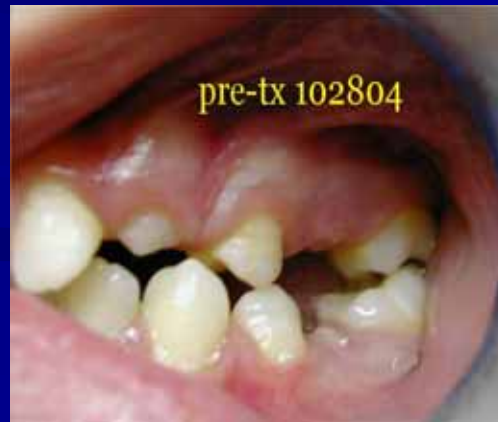
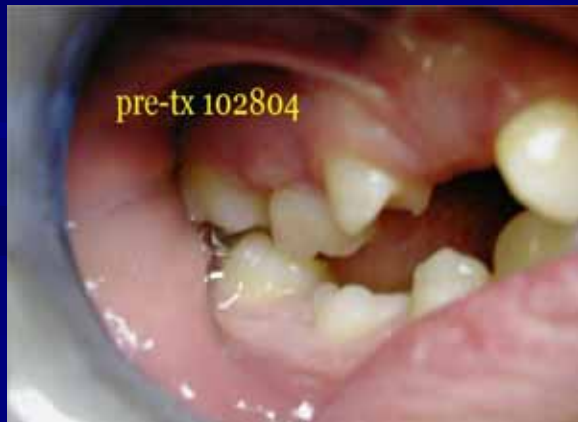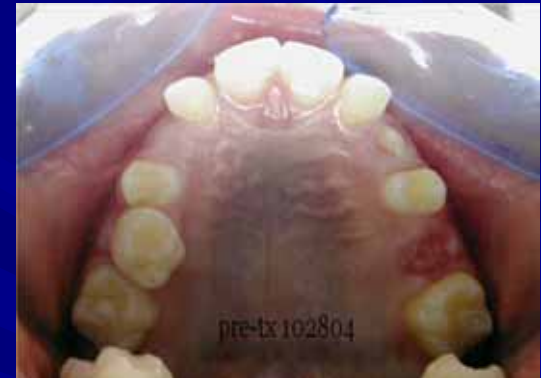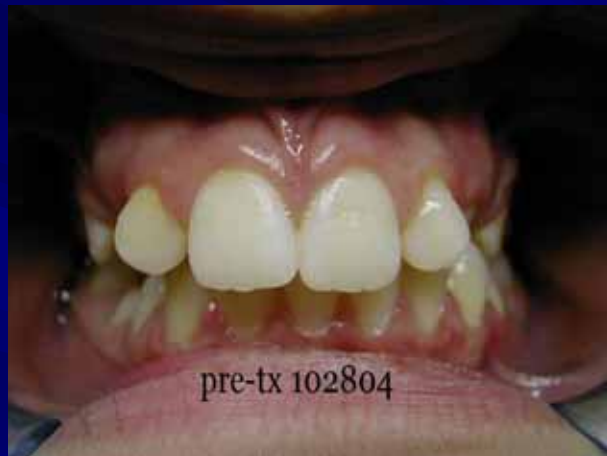- Class I full tooth
- Overjet 3mm
- Overbite 50%
- Class I facial profile
- Headaches 2-3x week
- Concerns:
Crowding/overbite

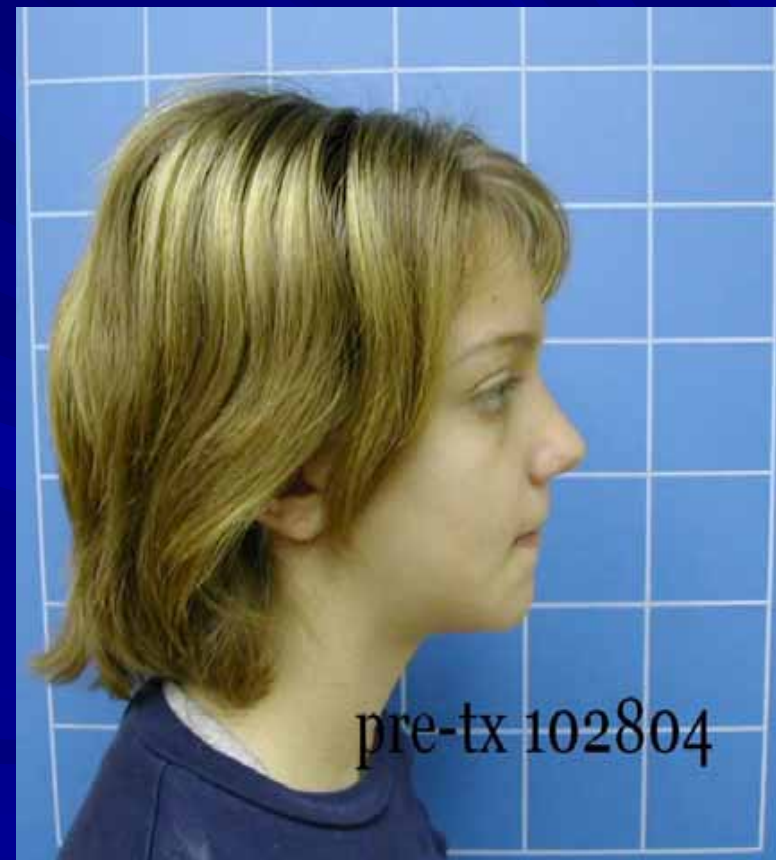Class I Full Tooth

Jenna: 11 years of age

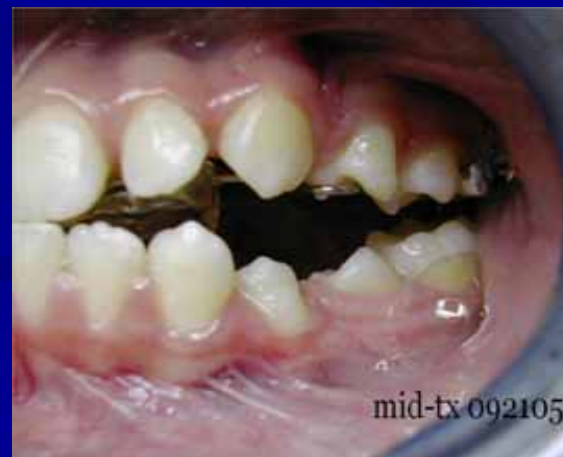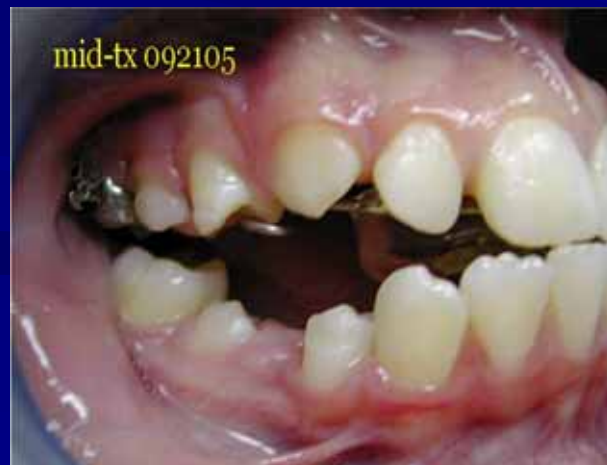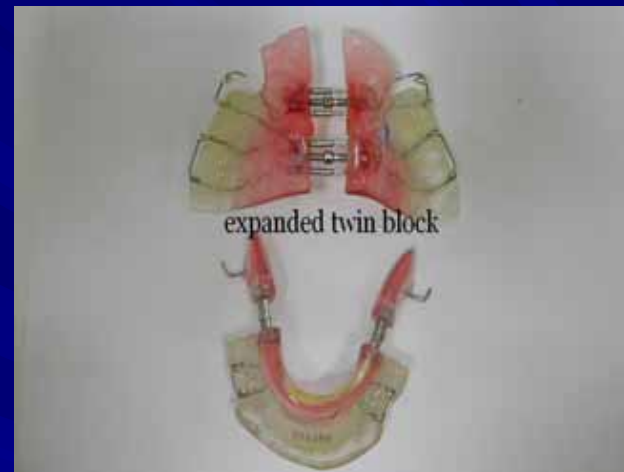
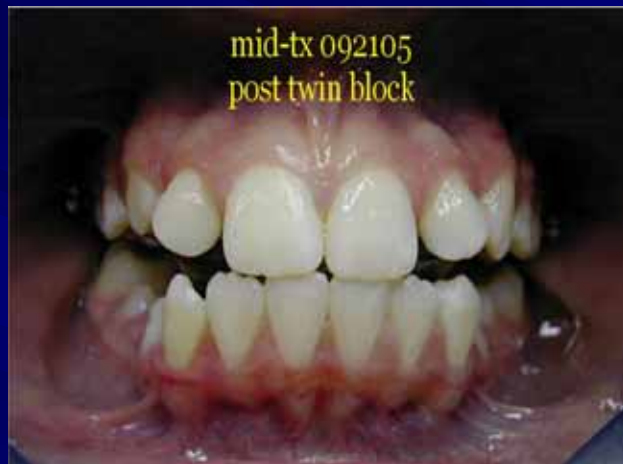Pre-treatment



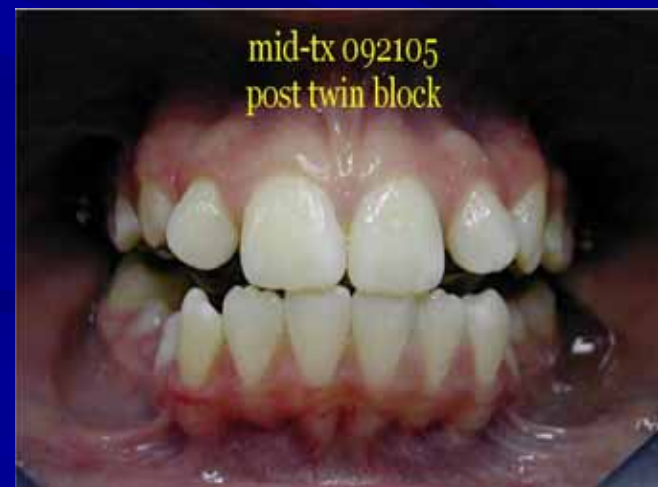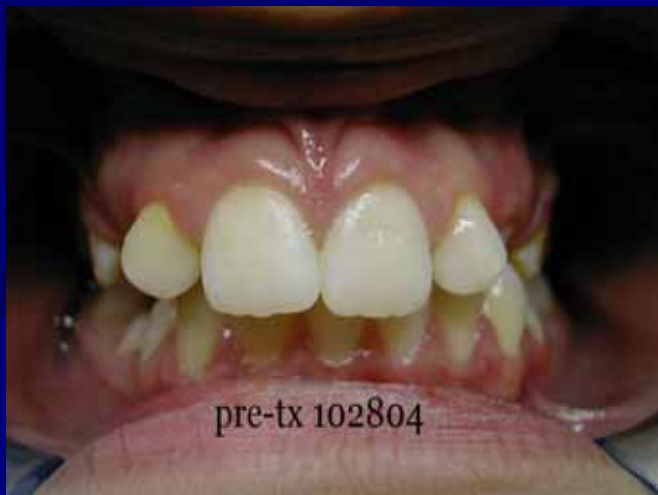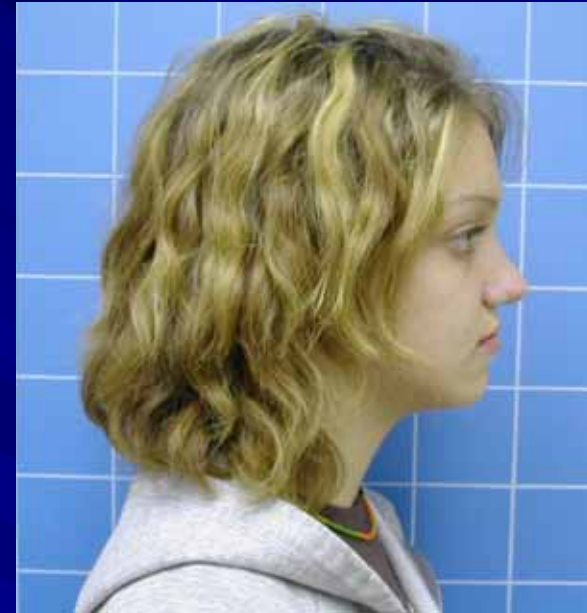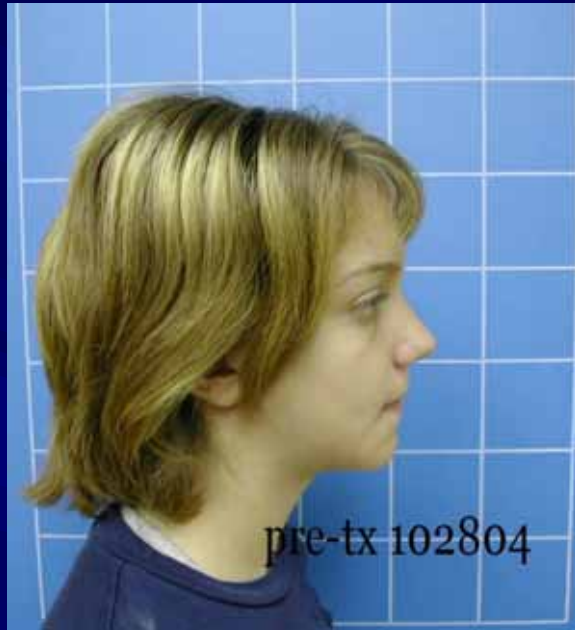Class I Full Tooth
Jenna: 11 years of age
Pre-treatment



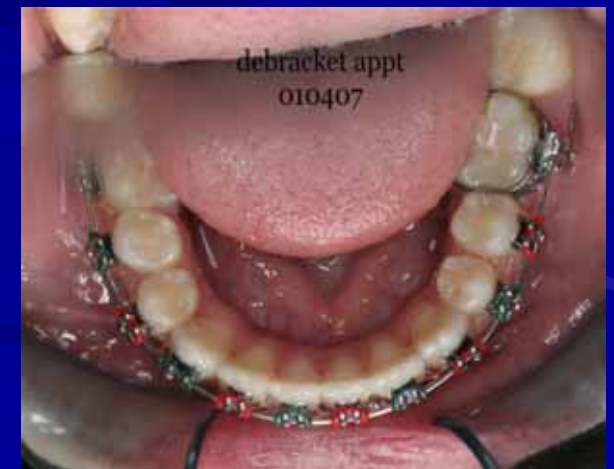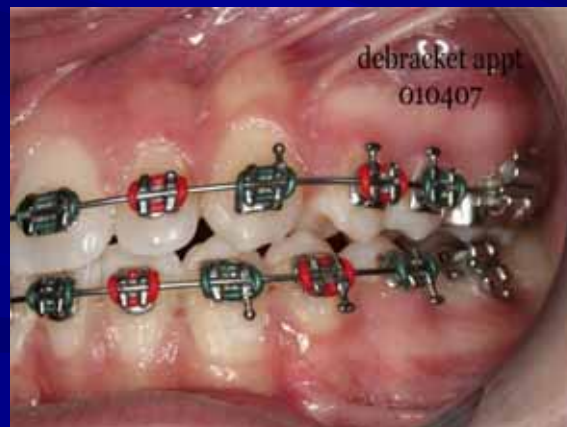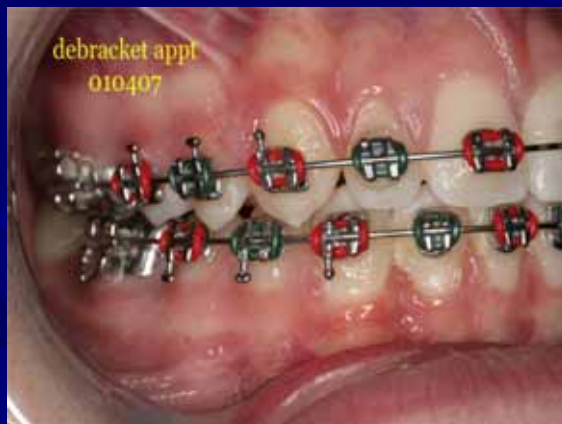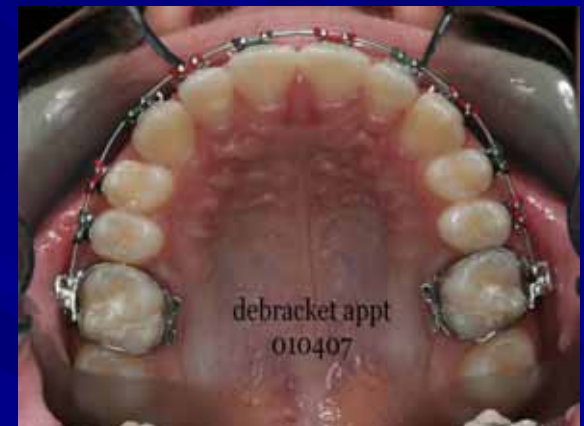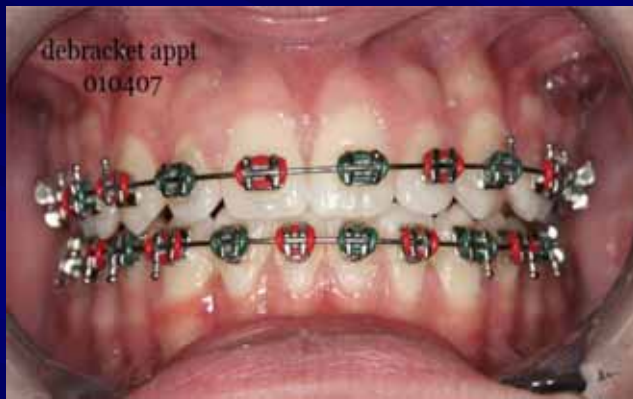Jenna: Post Twin Block 9 months of active wear



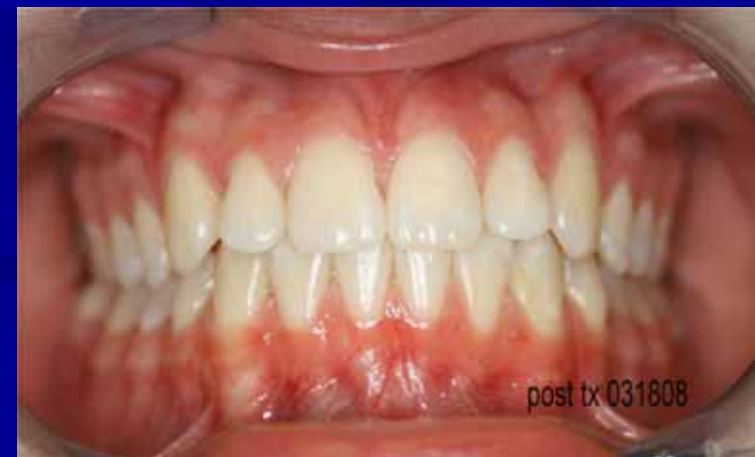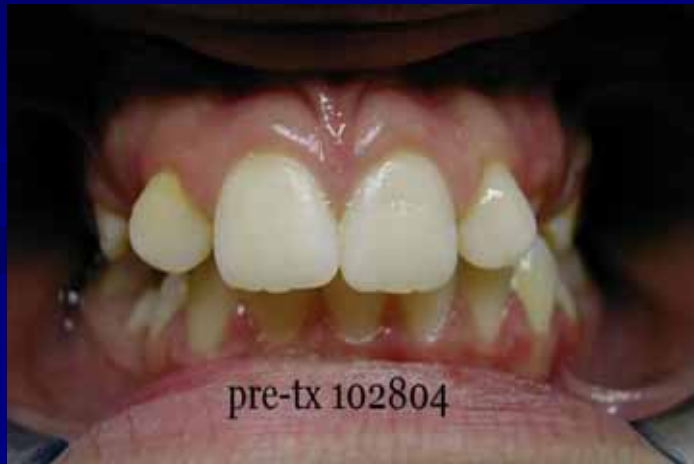Jenna: Pre & Mid treatment



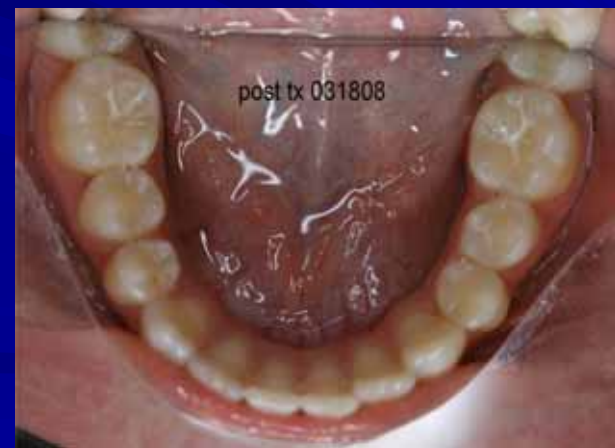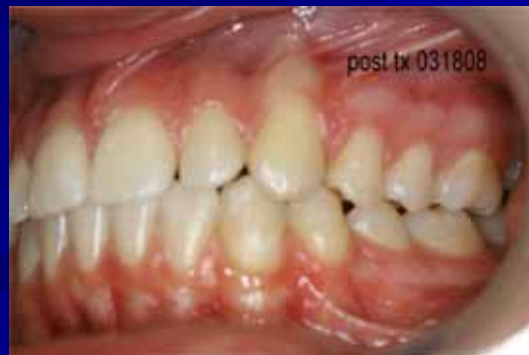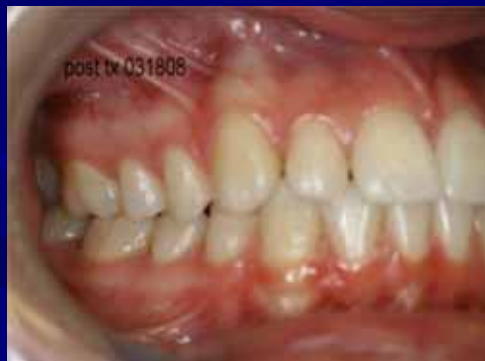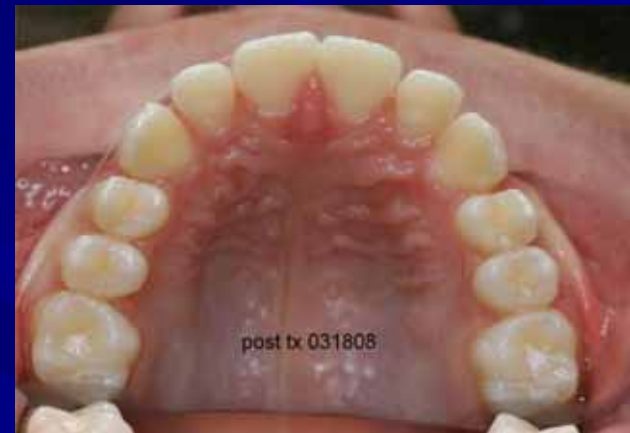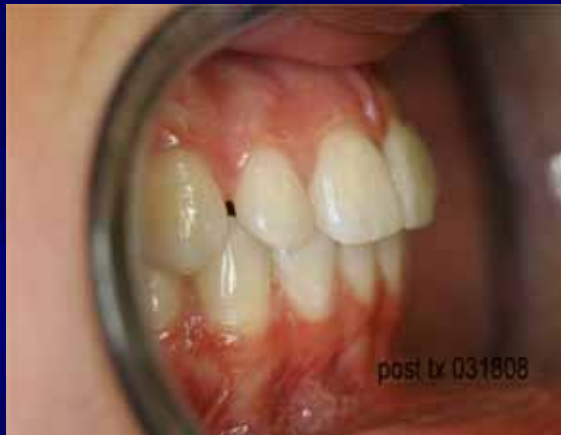Jenna: 12 months of bracket Tx



Jenna: 24 months of active Tx

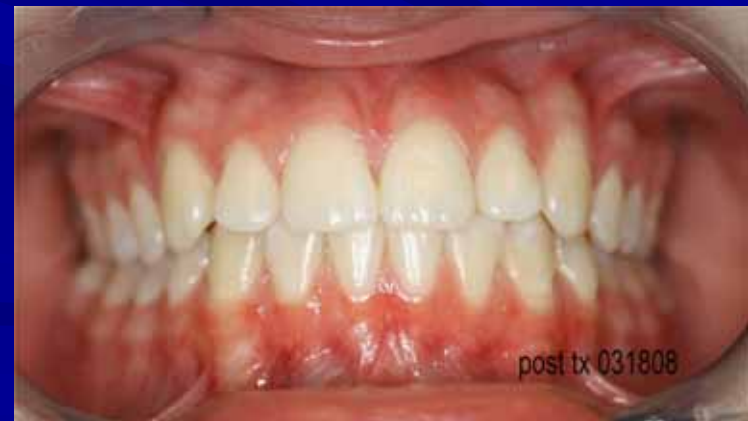

Jenna: Post treatment photos



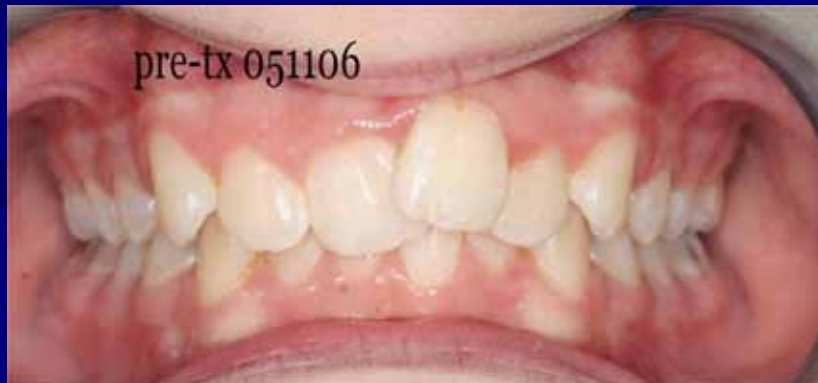Jenna

- Twin Block 9 months
- Rick-a-nator 3 months prior to full brackets
- Full brackets 12 months
- Intra oral vertical box elastics
- Positioner for retention (patient wore for a few months, did not see Jenna for 9 months)
- Presently upper slipcover/lower bonded 3x3



Class I

Jesse: 11 years of age

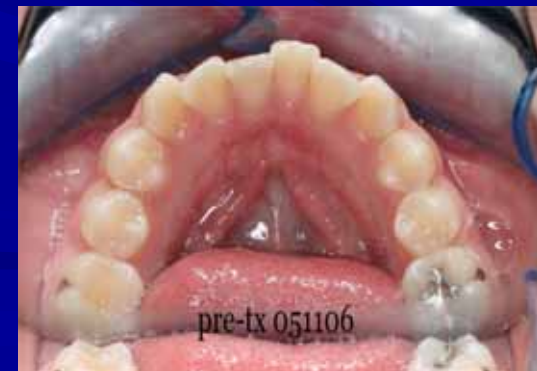
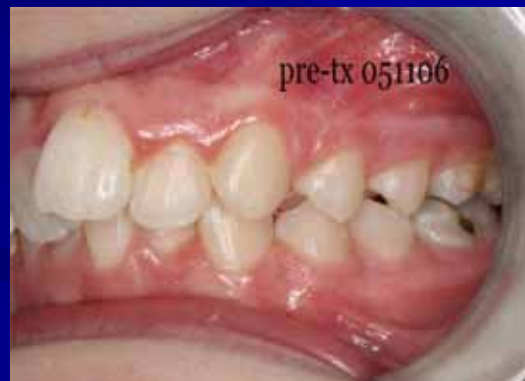
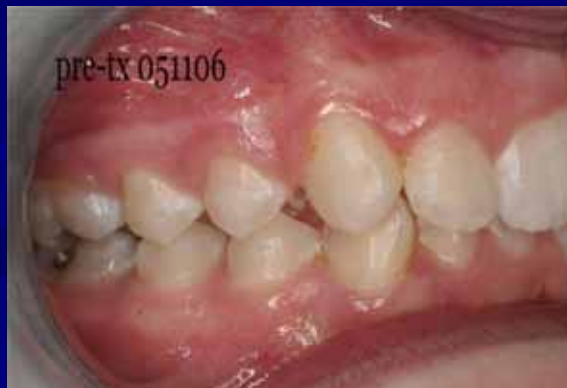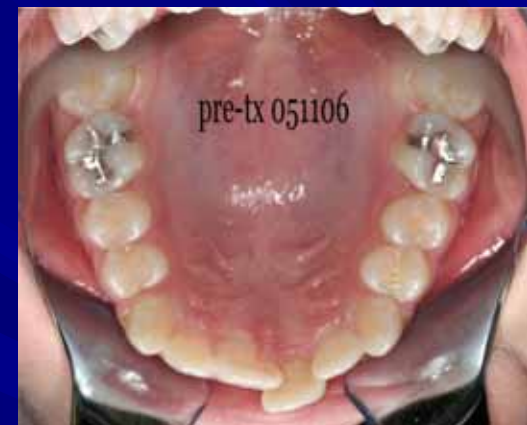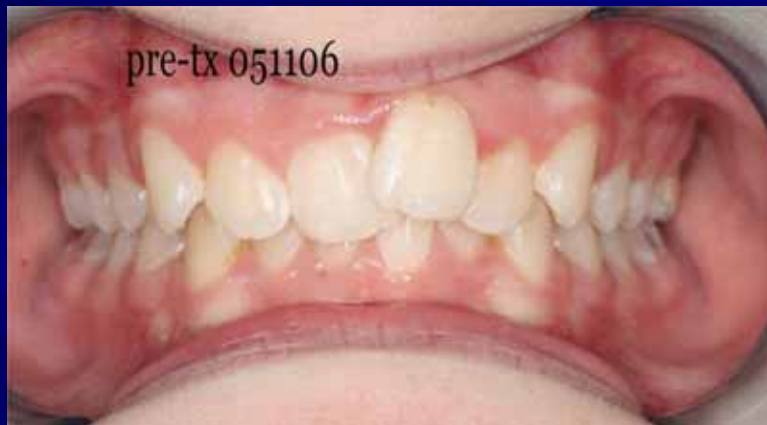- Class II ½ tooth left
- Class I full tooth right
- Overjet 4mm
- Overbite 50%
- Class II facial profile
- Headaches 2x week
- Concerns: Headaches, crooked teeth

Class I

Jesse: 11 yrs of age

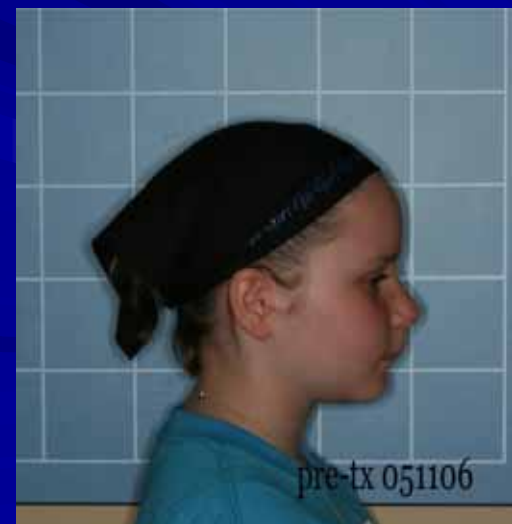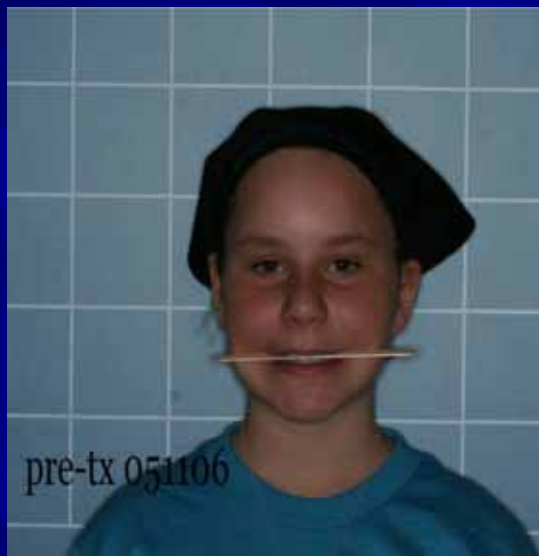
Pre-treatment



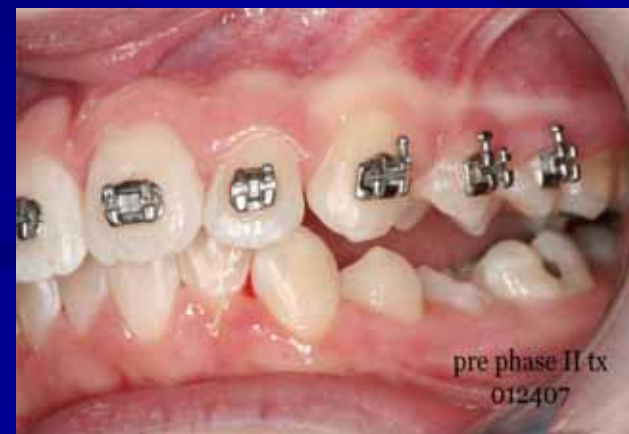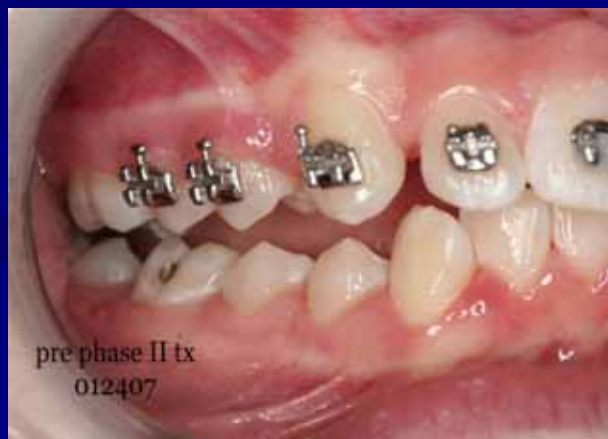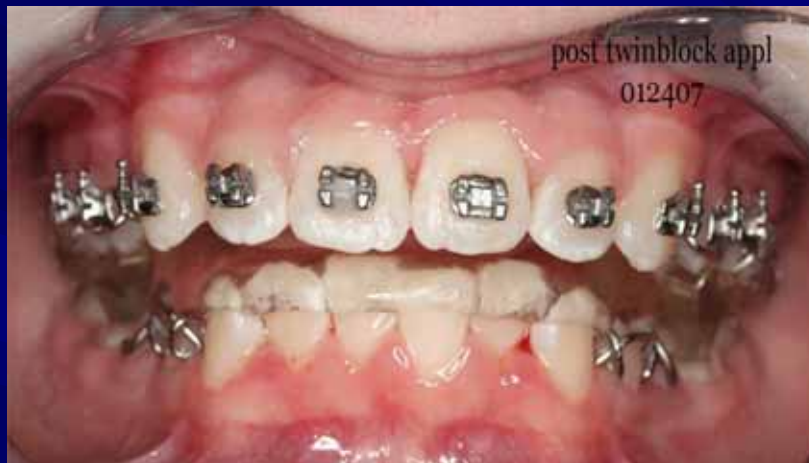Class I

Jesse: 11 yrs of age

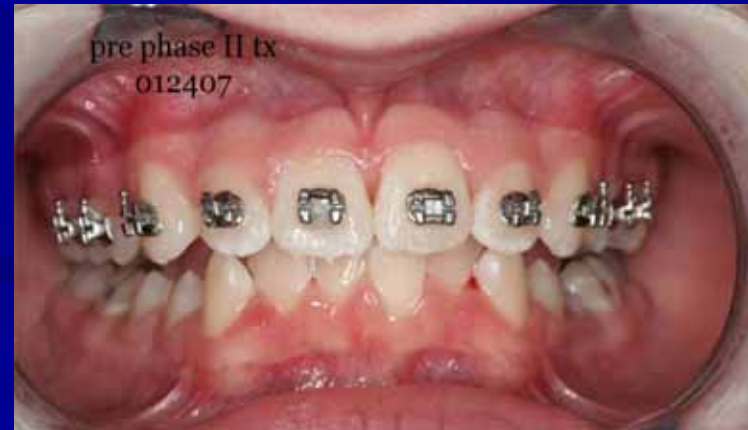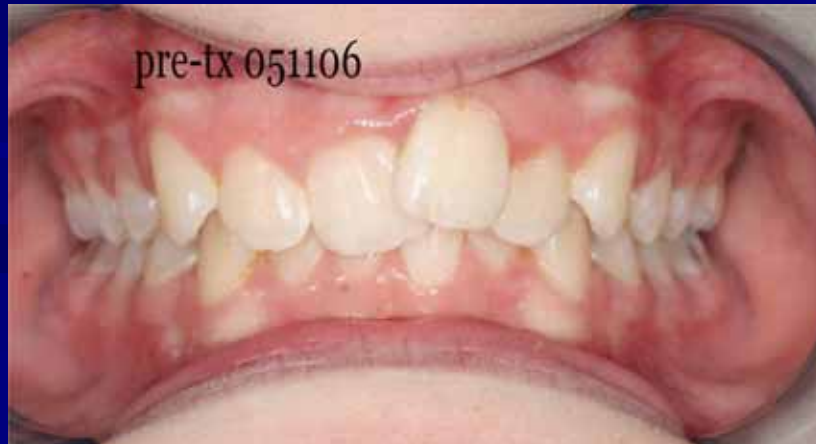Pre-treatment



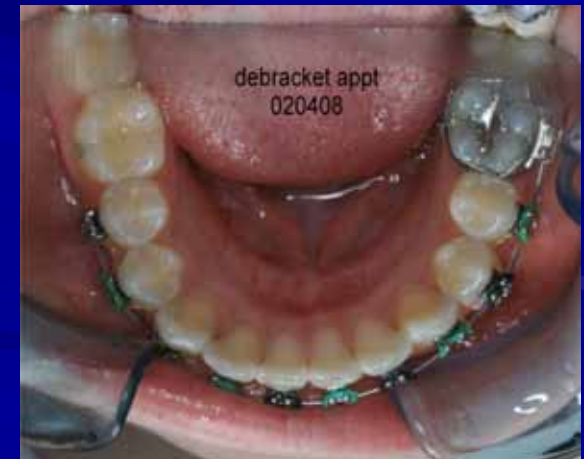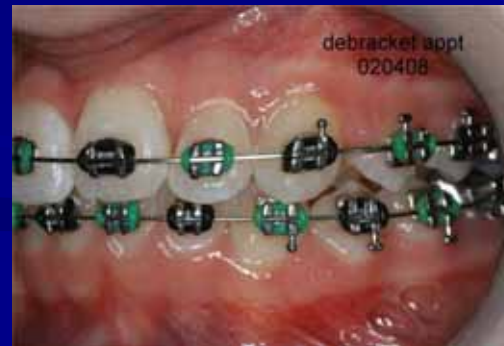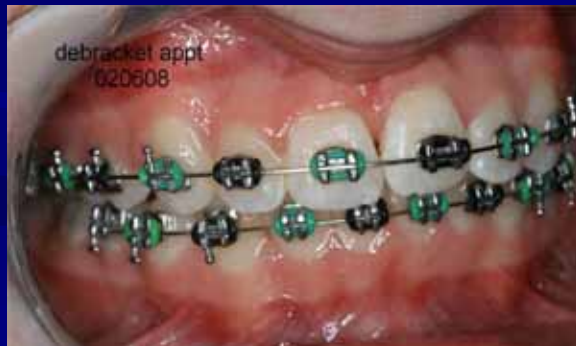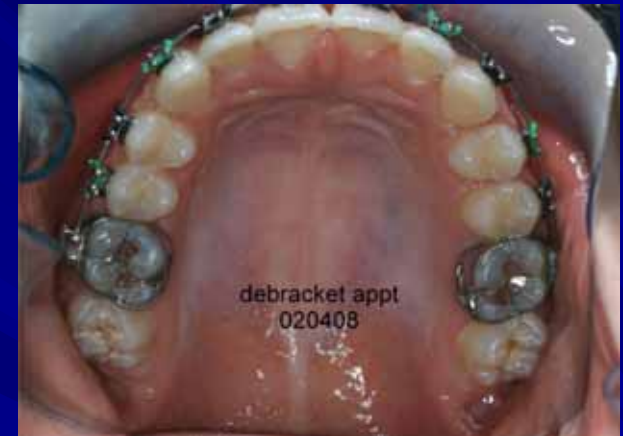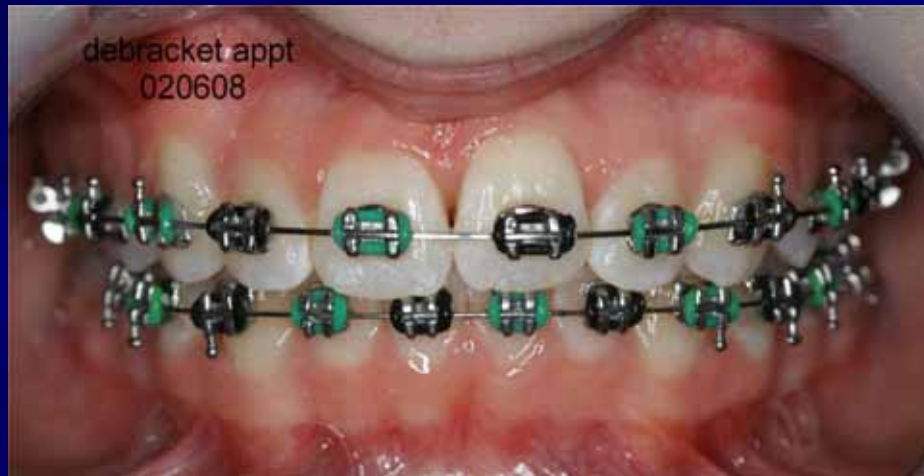Jesse: Post Twin Block 7 months of active wear



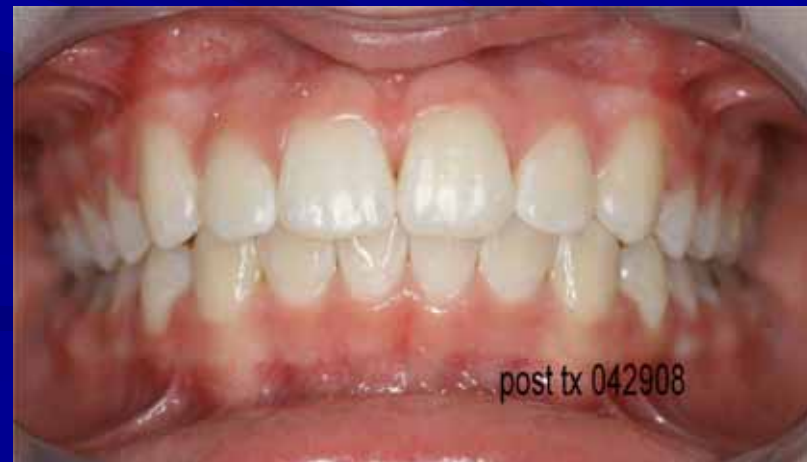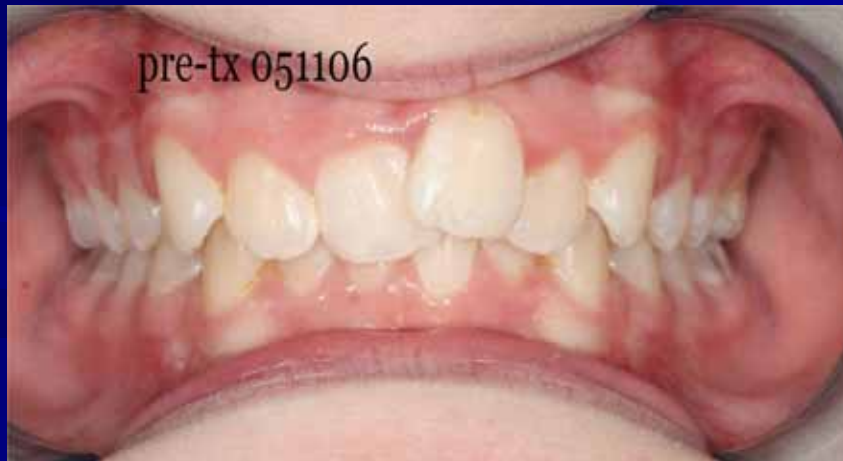Jesse: Pre & Mid treatment



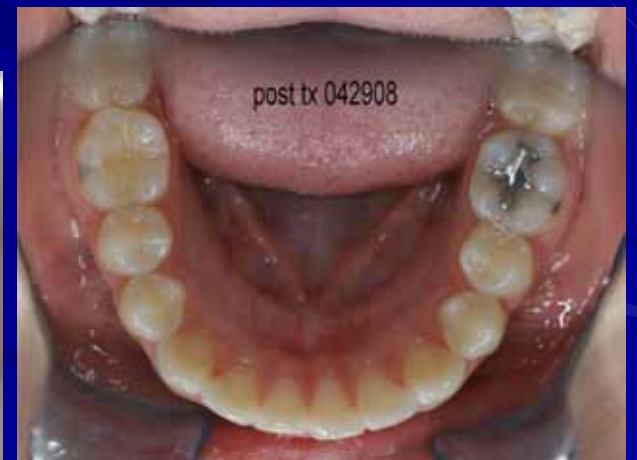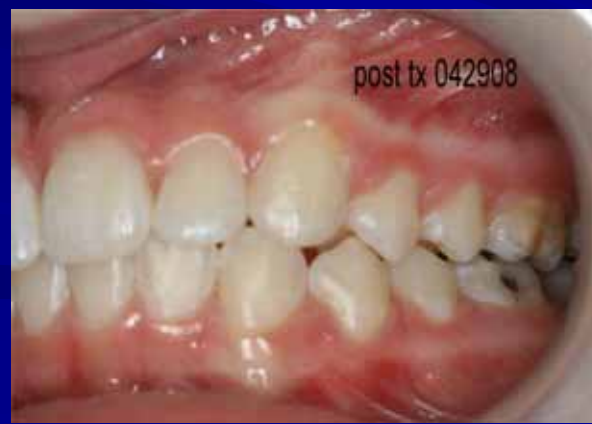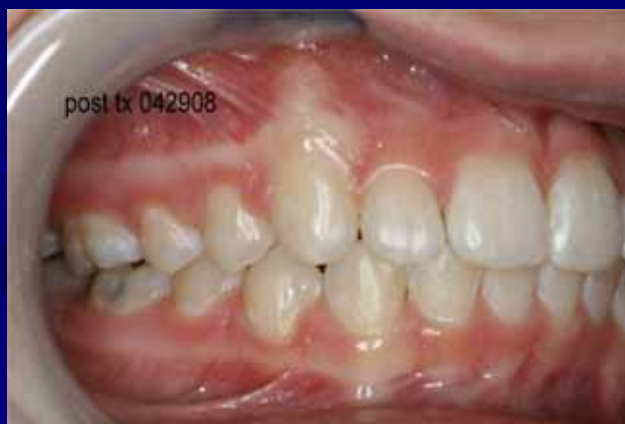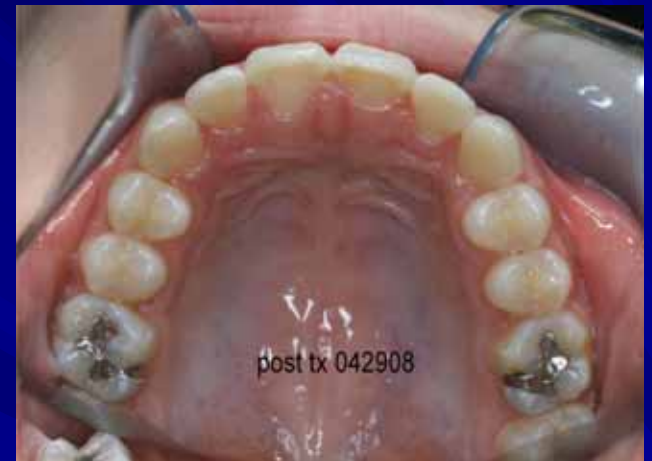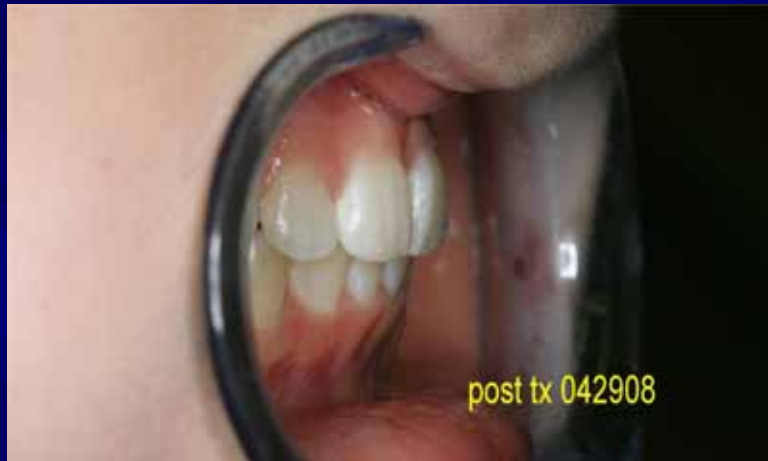Jesse: 11 months of bracket Tx



Jesse: 18 months of active Tx

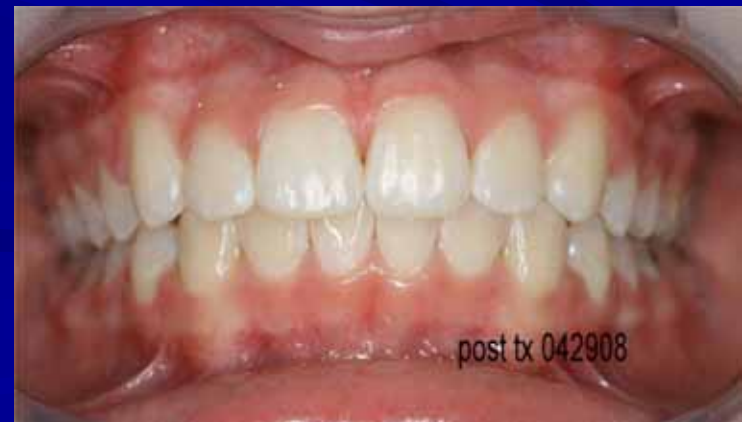

Jesse: Post Tx photos



Jesse

- Twin Block/upper brackets 7 months
- Full brackets/upper Hawley bite ramp
- Hawley bite ramp 7 months
- Brackets 13 months
- Positioner for retention
- No headaches



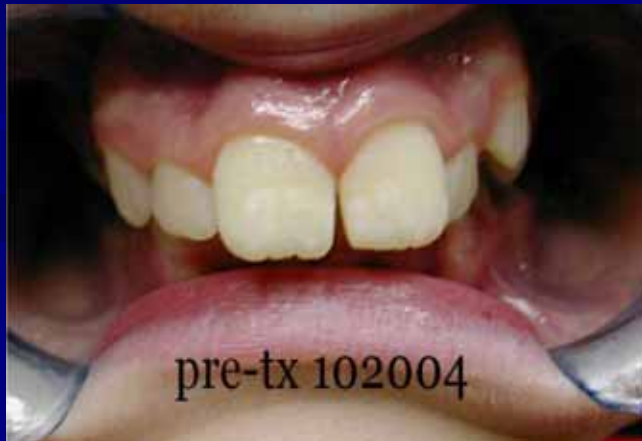Class II molar Twin Block Treatment

Class II

Christine: 13 years of age



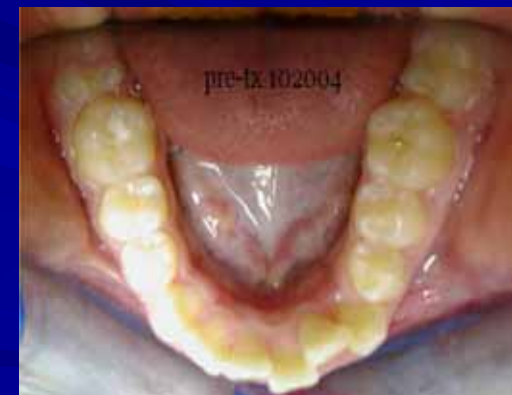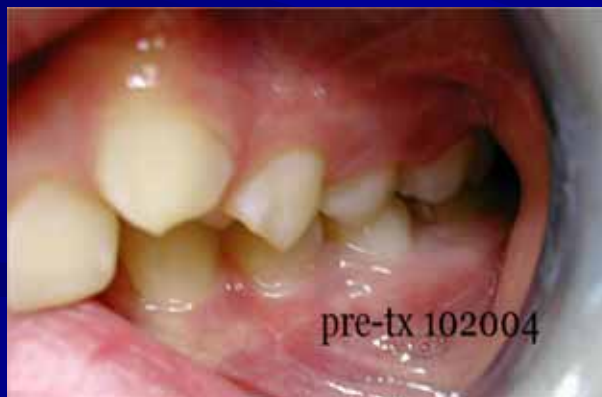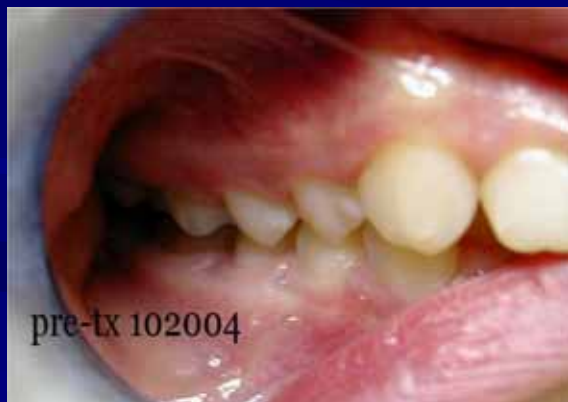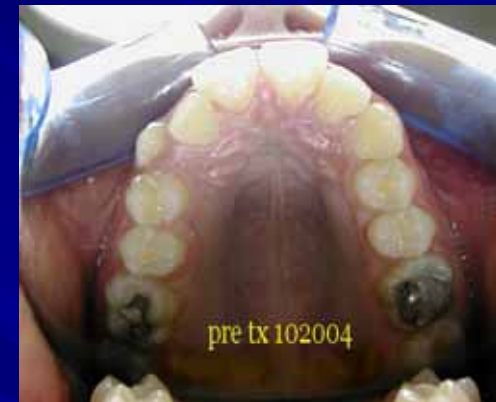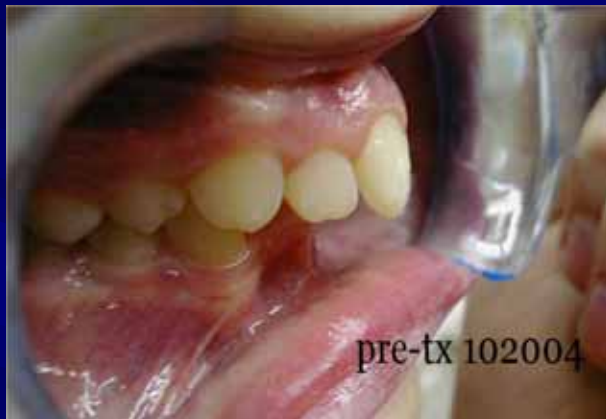- Class II full tooth
- Overjet 10 mm
- Overbite 100%
- Class II facial profile
- Occasional headaches



Class II

Christine: 13 years of age

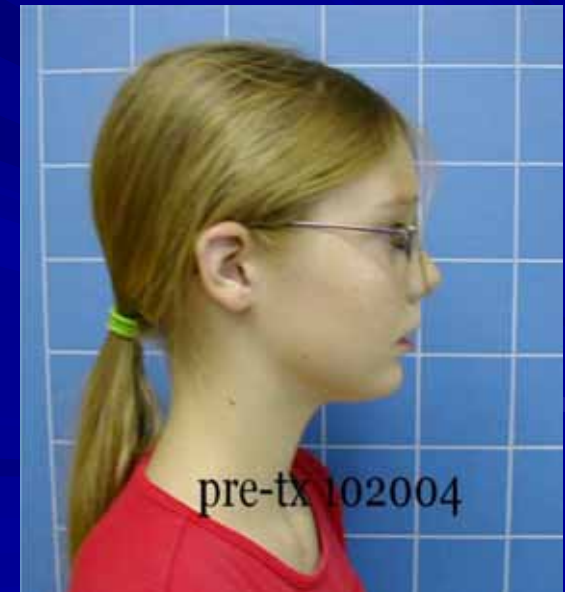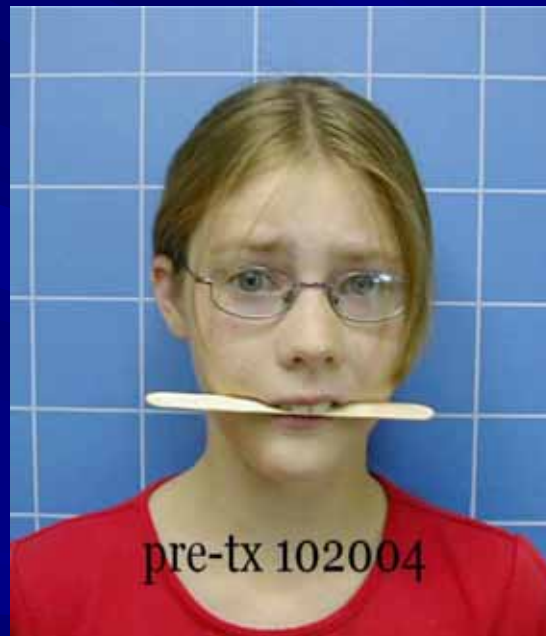Pre-treatment



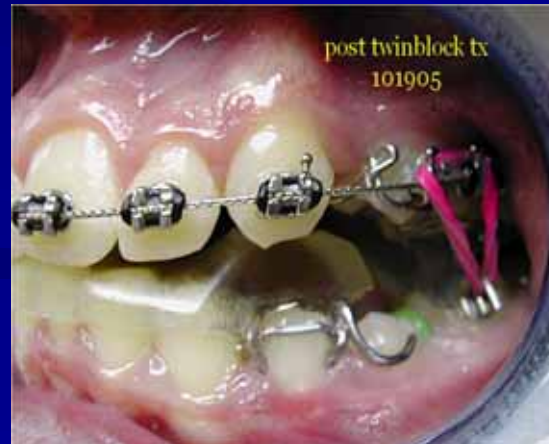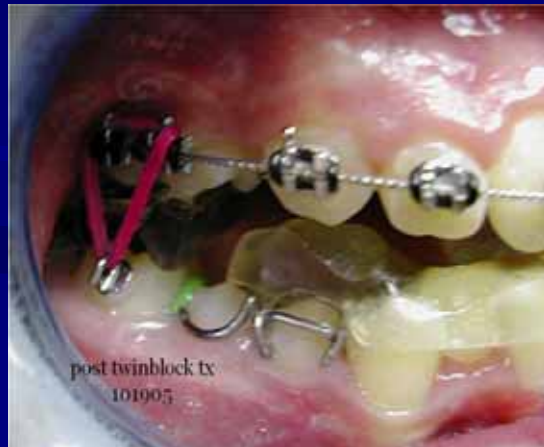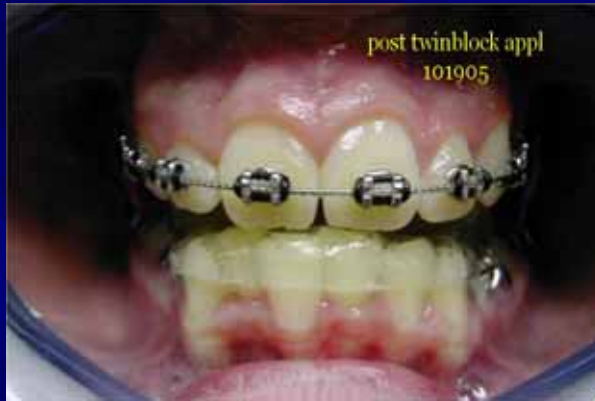Class II

Christine: 13 years of age

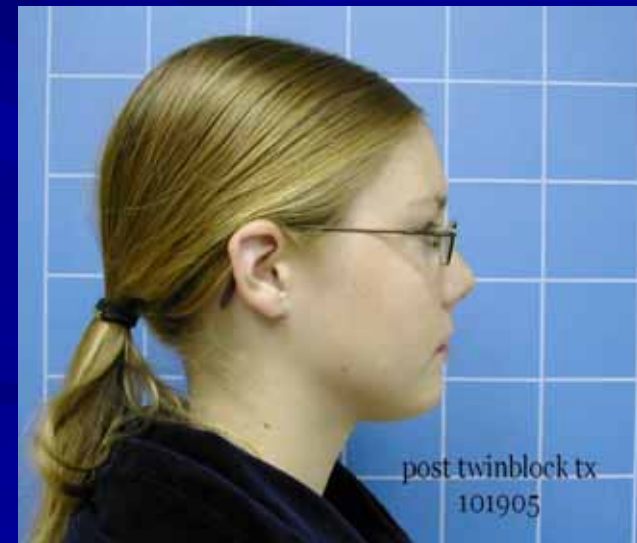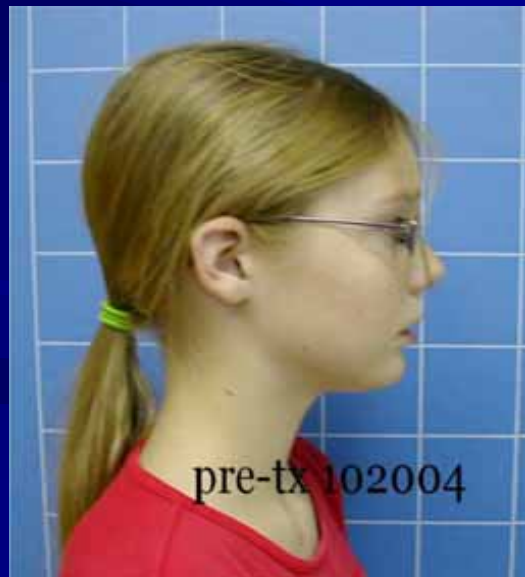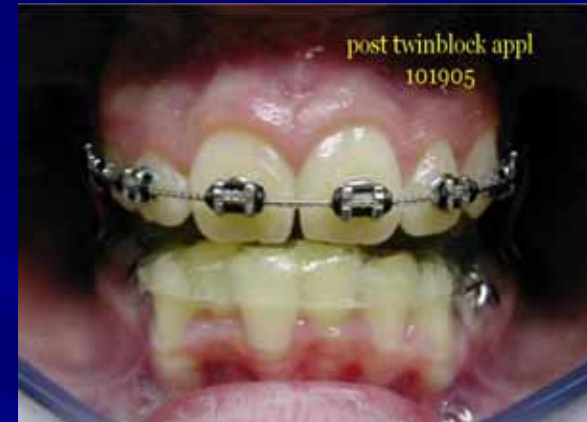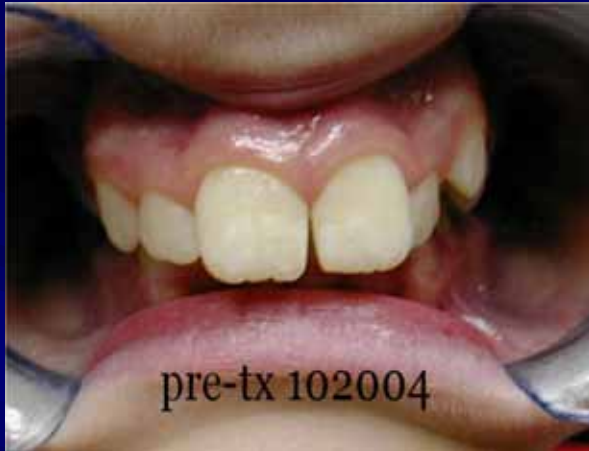Pre-treatment



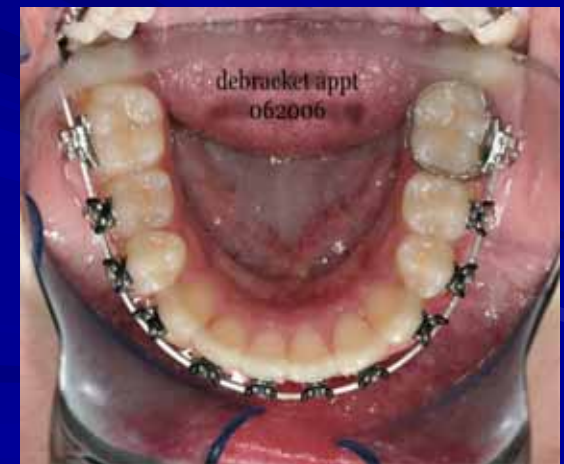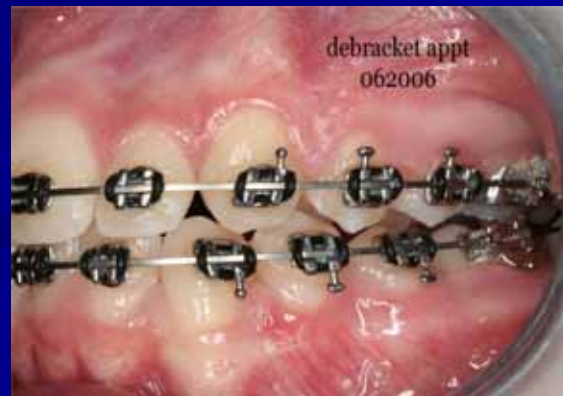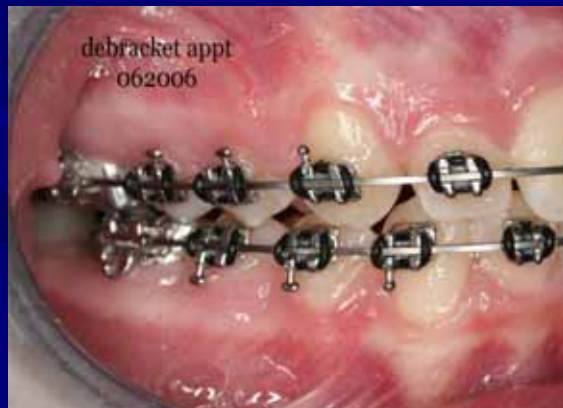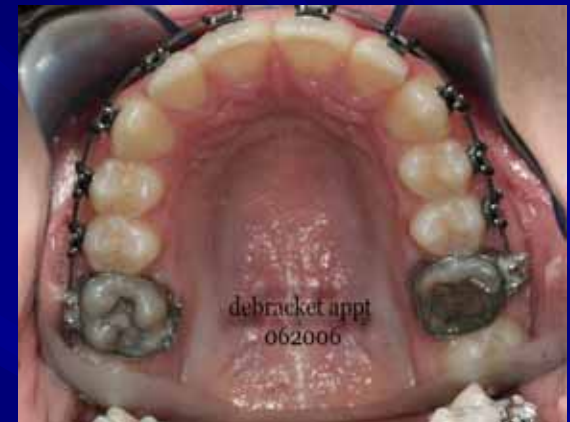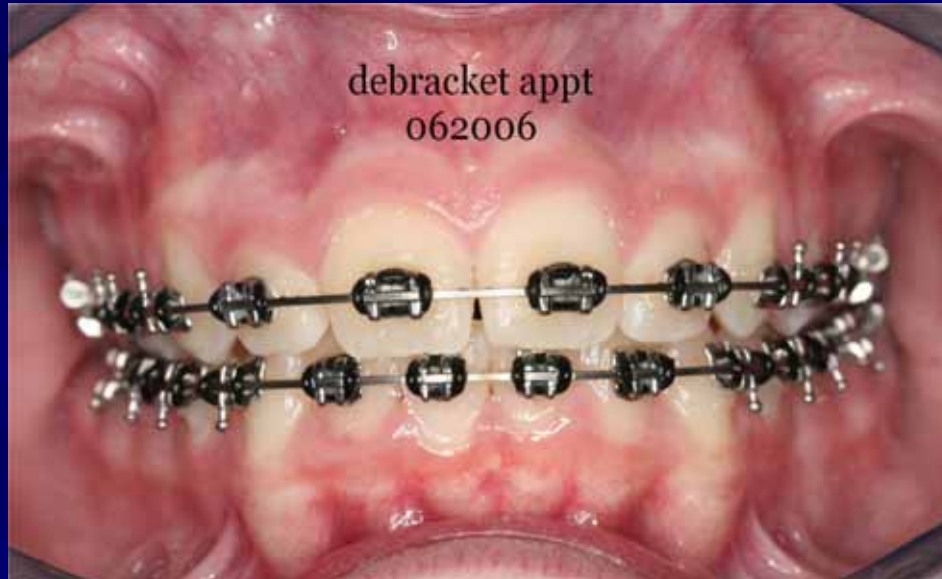Christine: Mid treatment Post Twin Block 9 months of active wear



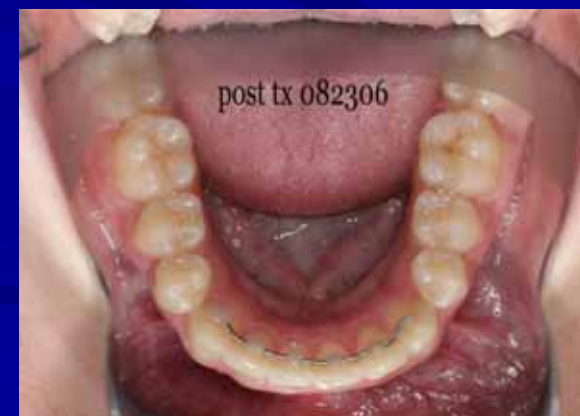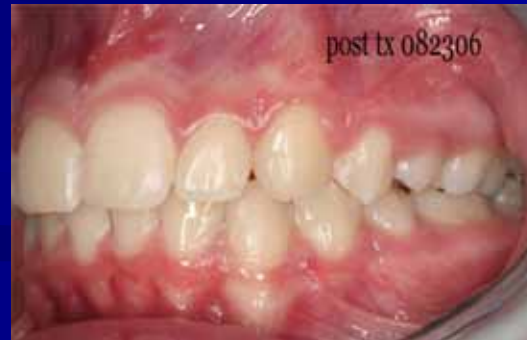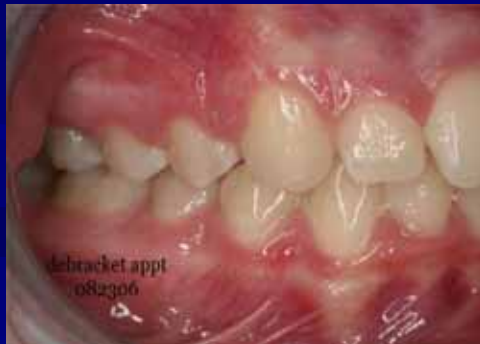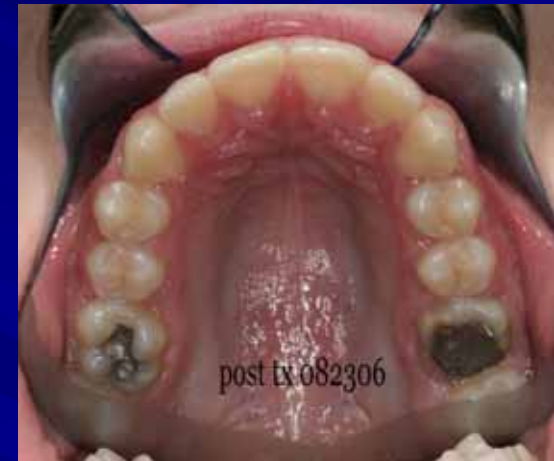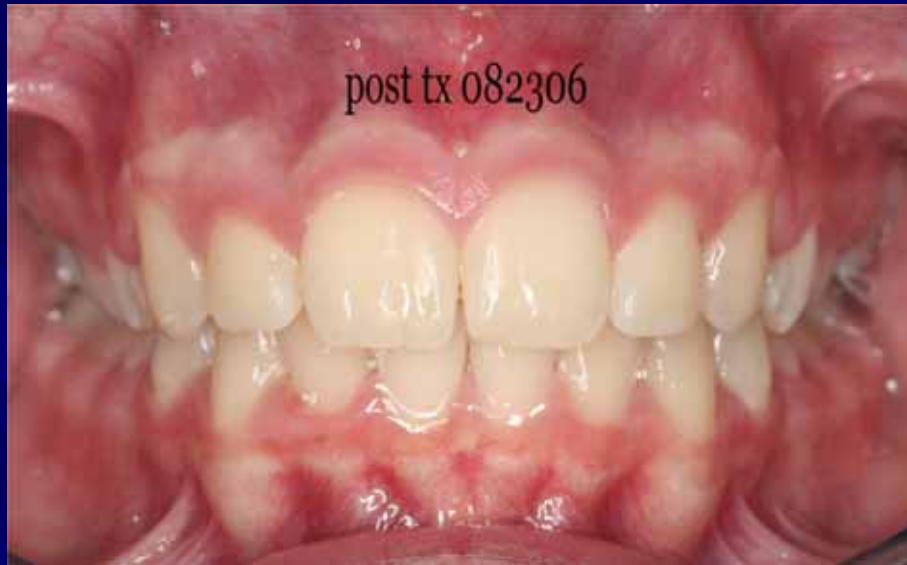Christine: Pre & Mid treatment



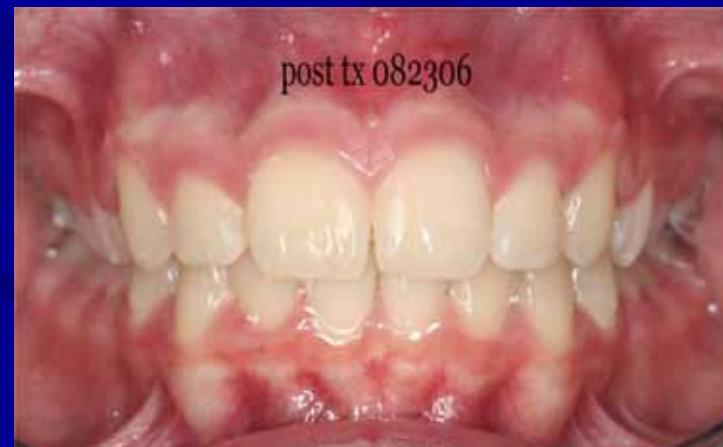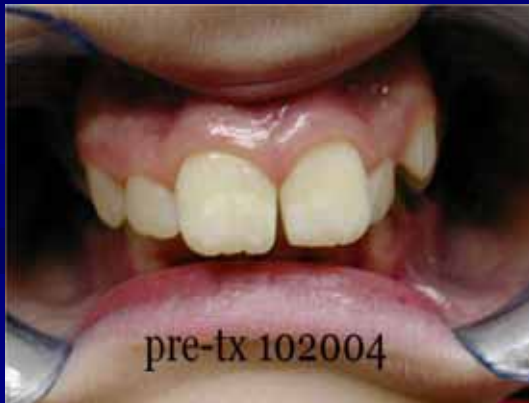Christine: 8 months full bracket Tx



Christine: Post Tx photos

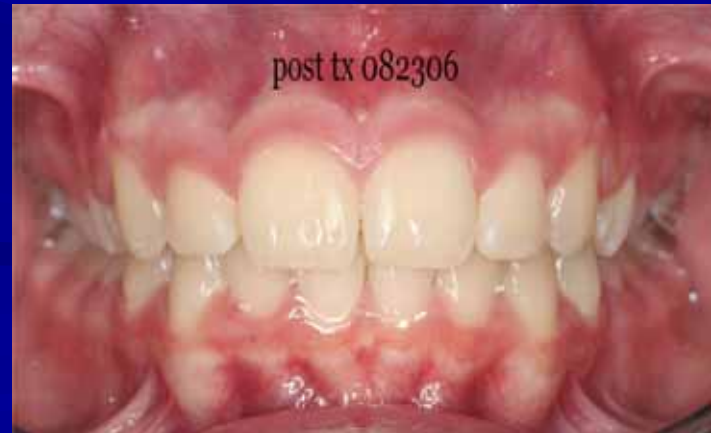

Christine: 17 months of active Tx



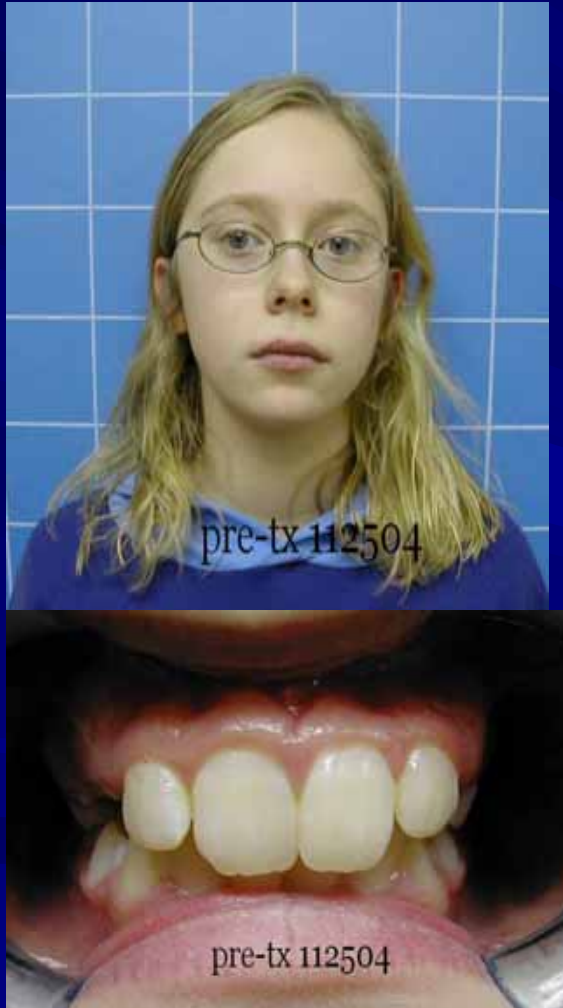Christine

- Twin Block with upper brackets 9 months
- Full brackets with Rick-a-nator 8 months
- Removed Rick-a-nator after 3 months
- Upper Hawley/lower 3x3 for retention



Class II

Grace: 10 years of age

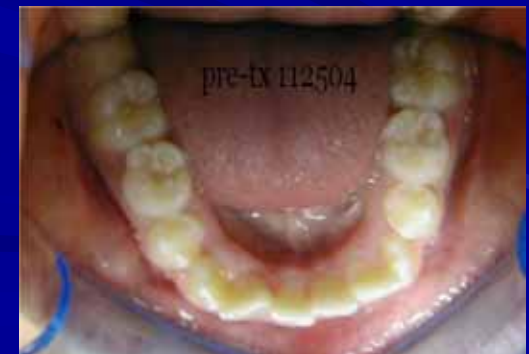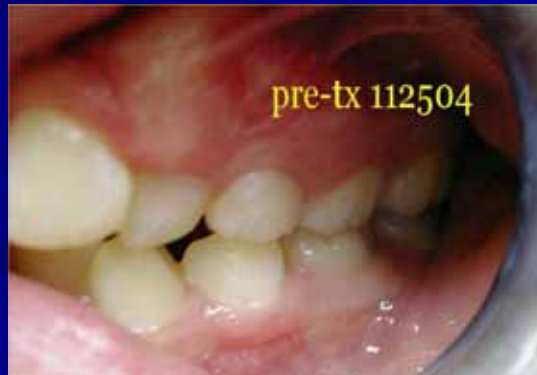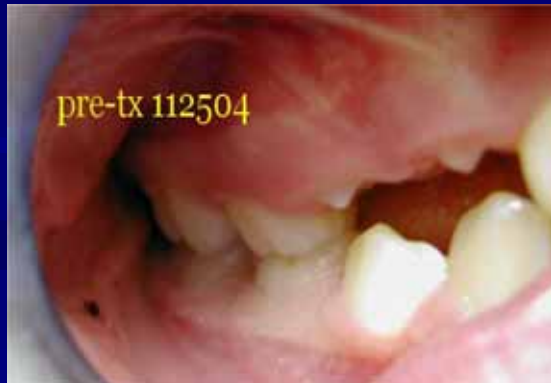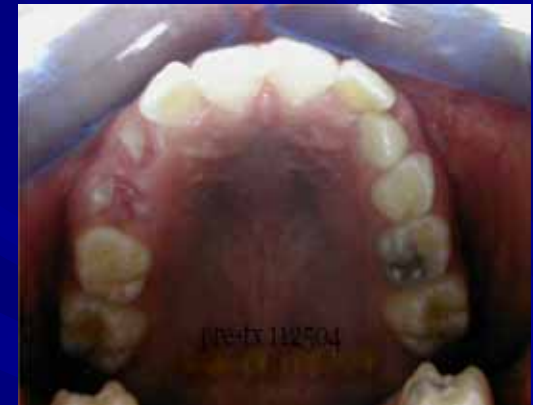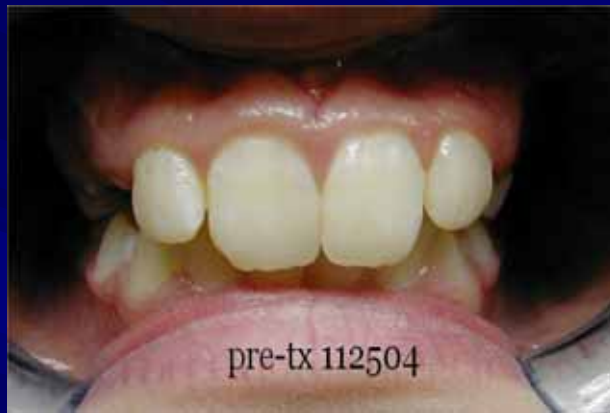


- Class II ½ tooth
- Overjet +3mm
- Overbite 70%
- Class I facial profile
- Concern: Overbite

Class II

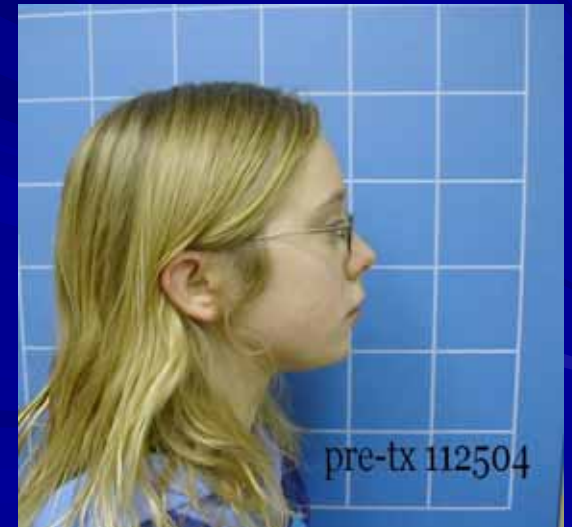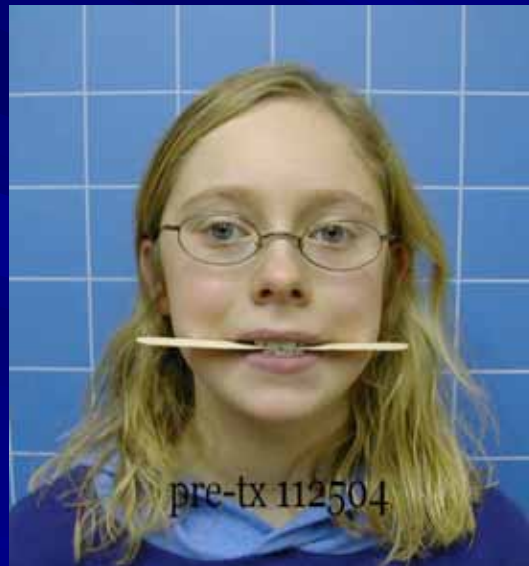Grace: 10 years of age

Pre-treatment

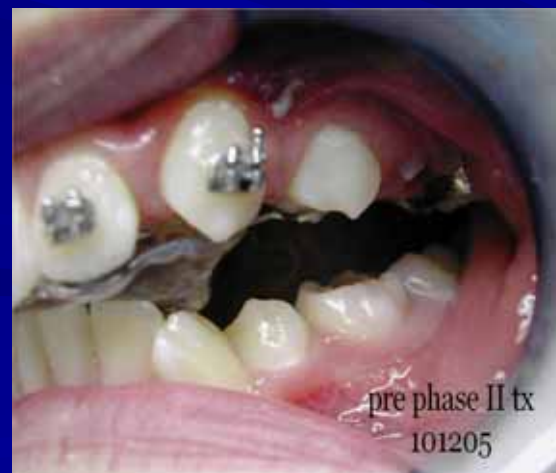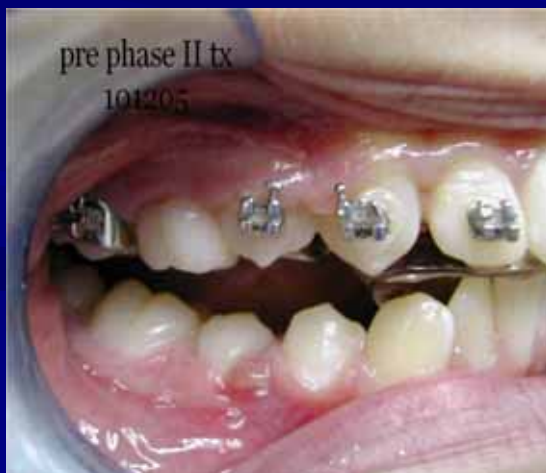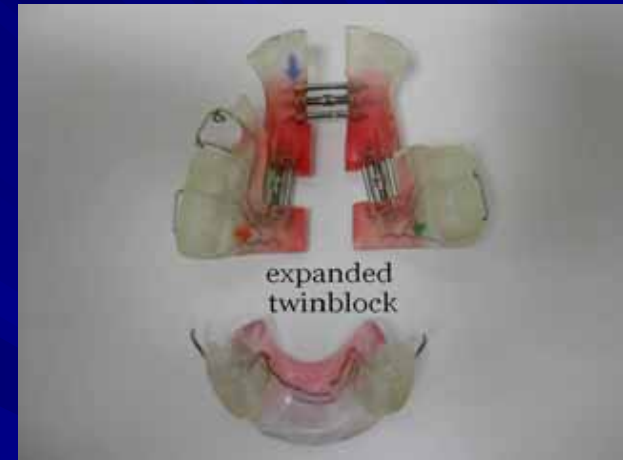


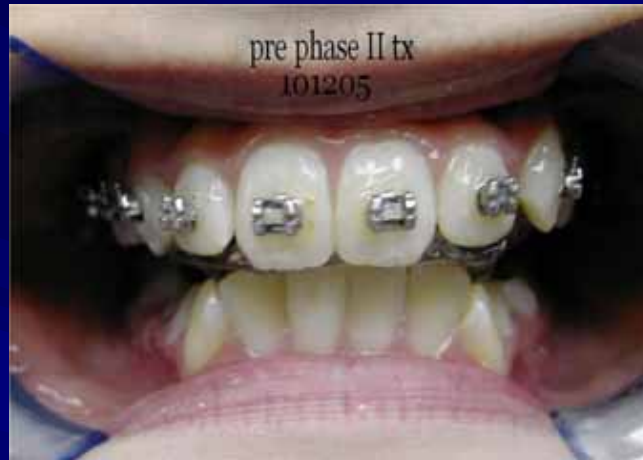Class II

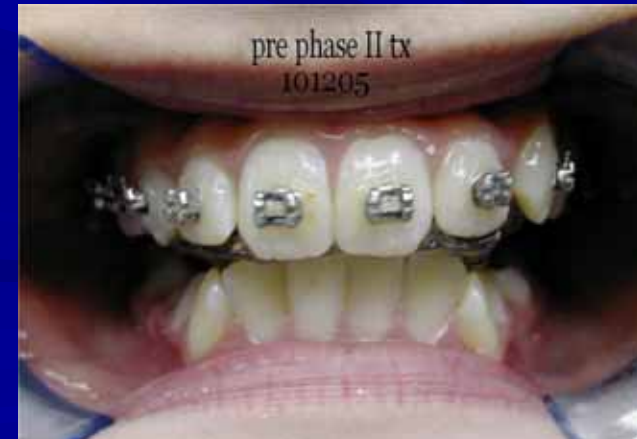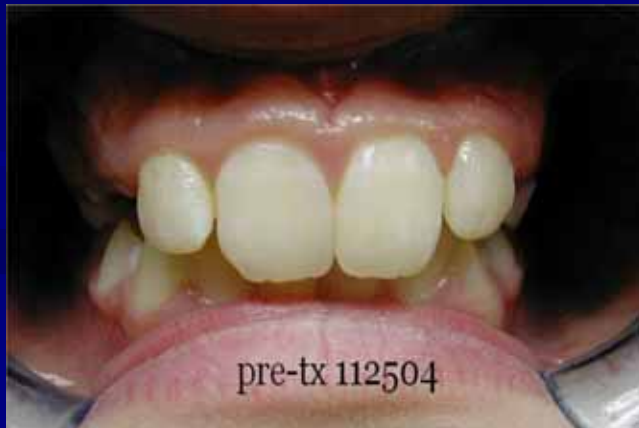Grace: 10 years of age



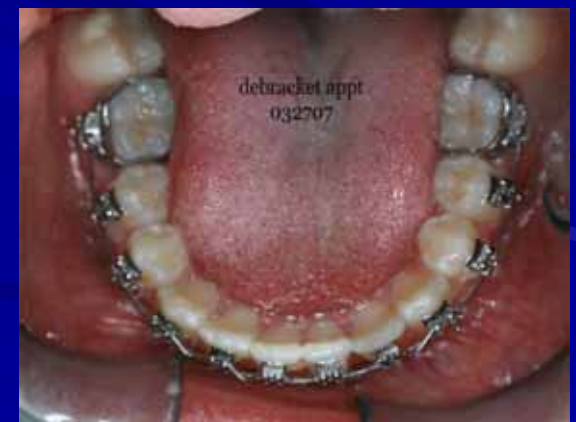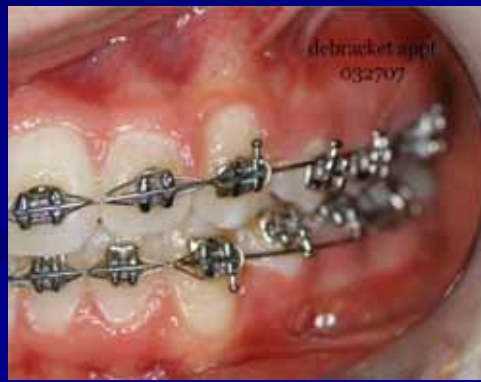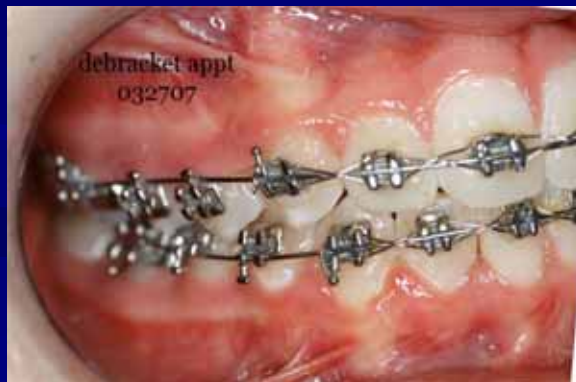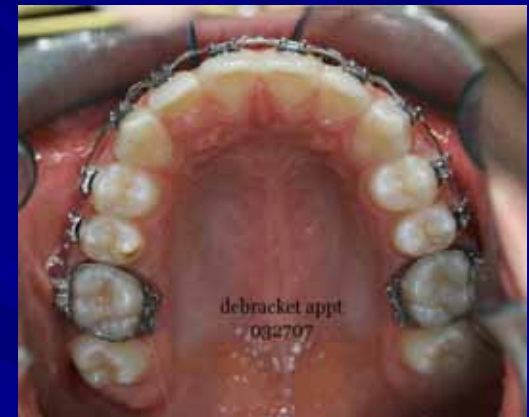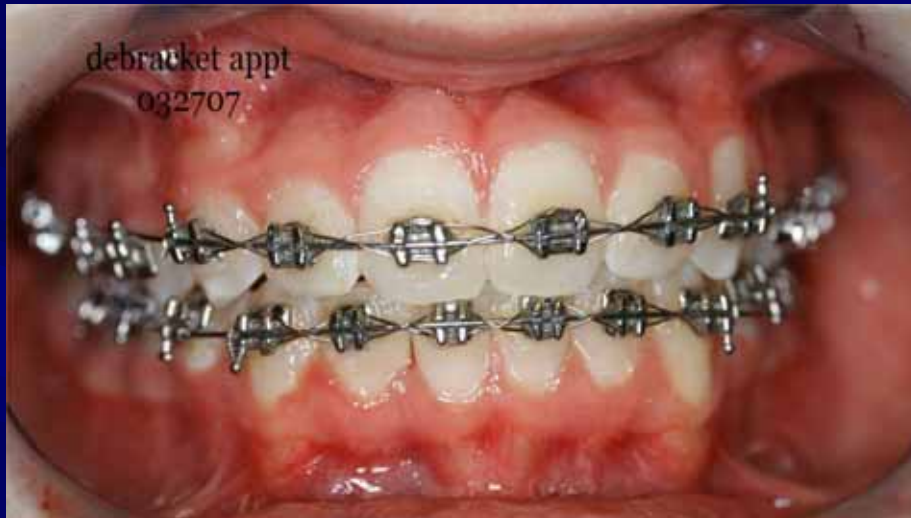Grace: Mid-treatment Post Twin Block 6 months active wear



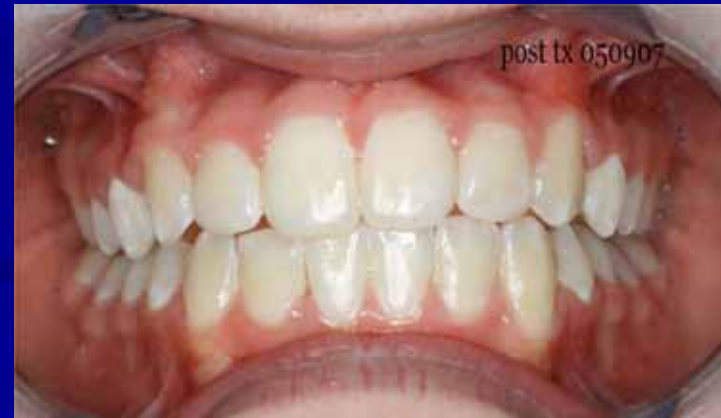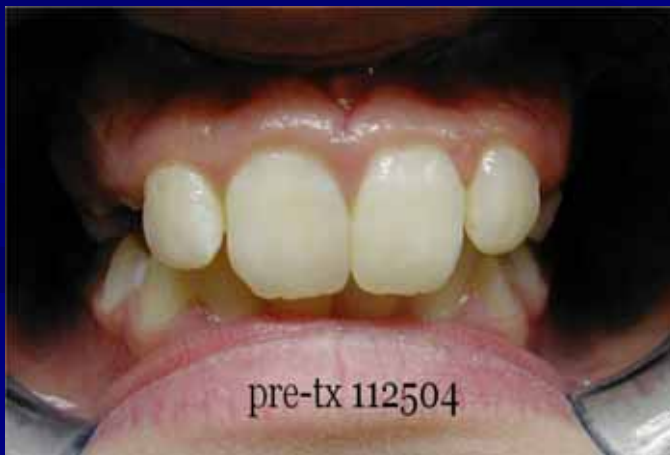Grace: Pre & Mid treatment



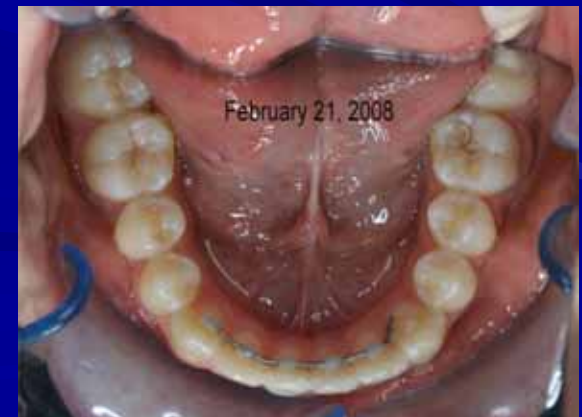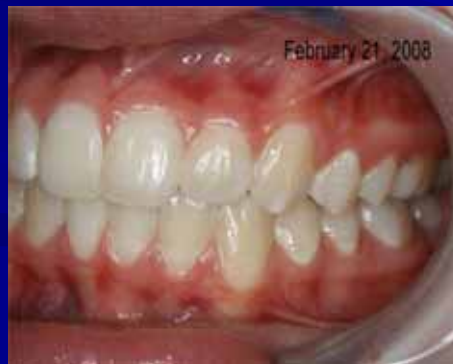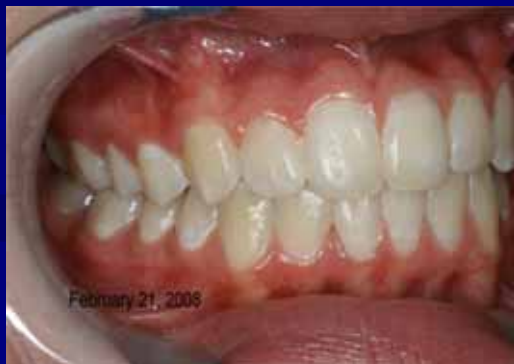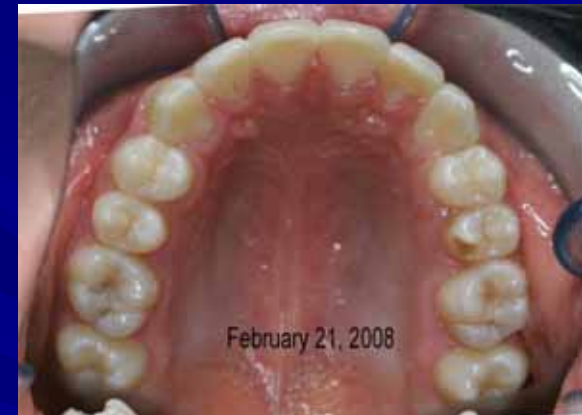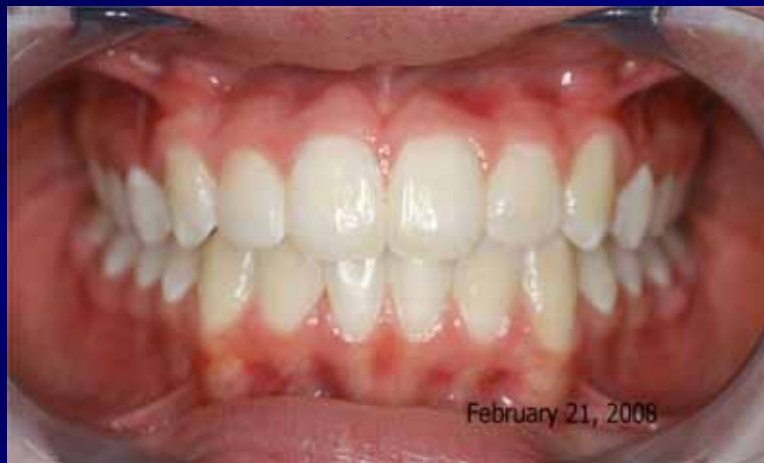Grace: 15 months full bracket Tx



Grace: 24 months of active Tx

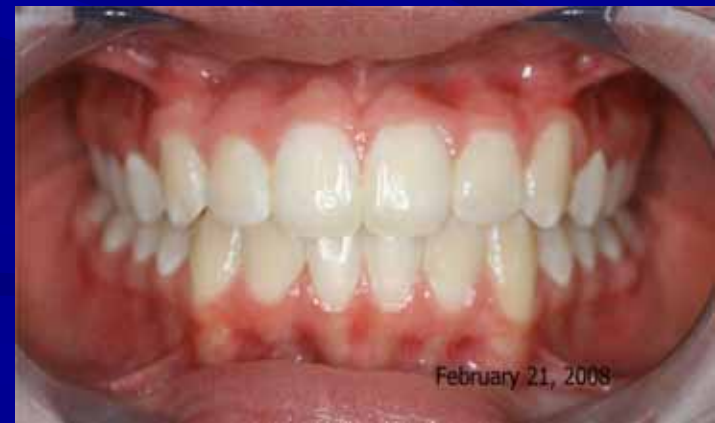

Grace: 11 months retention



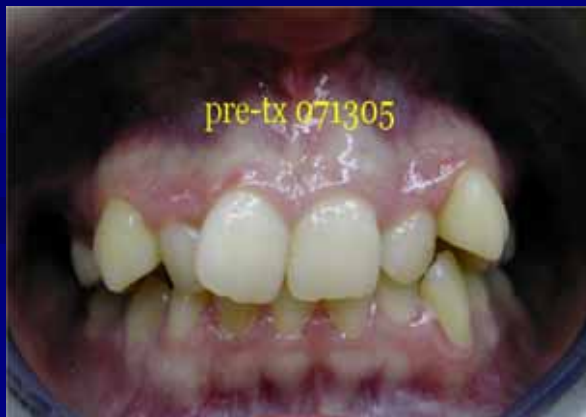Grace

- Twin Block/upper brackets 6 months
- Full brackets/upper Rick-a-nator 15 months
- Intra oral vertical box elastics
- Upper Hawley bite ramp & lower 3x3 for retention



Class II

Melissa: 14 years of age

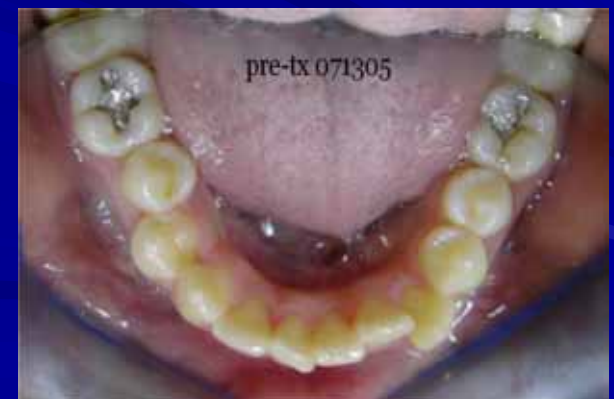
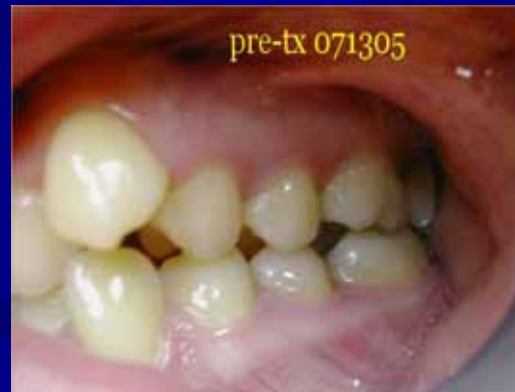
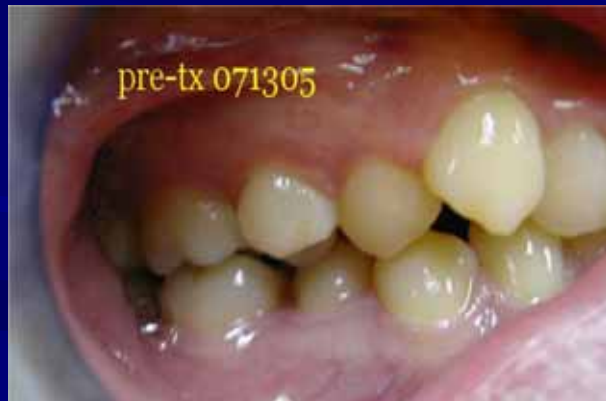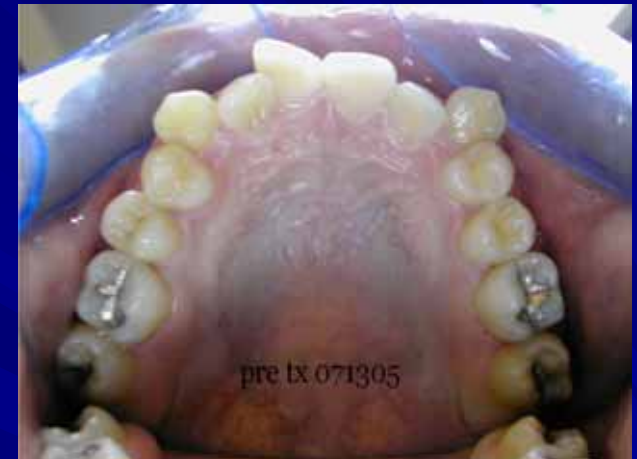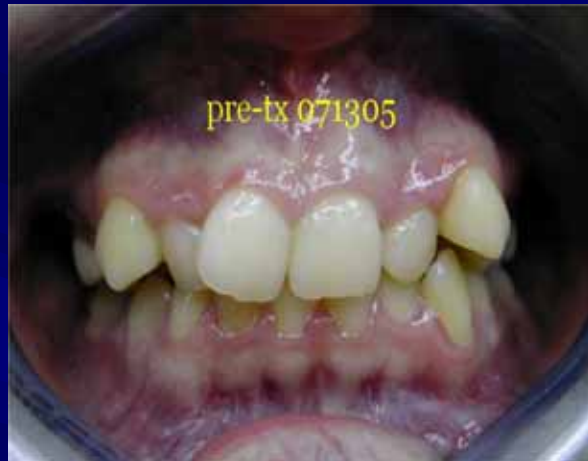- Class II full tooth
- Overjet 1 mm
- Overbite 50%
- Class II facial profile
- Concern: Wants straight teeth

Class II Full Tooth

Melissa: 14 years of age

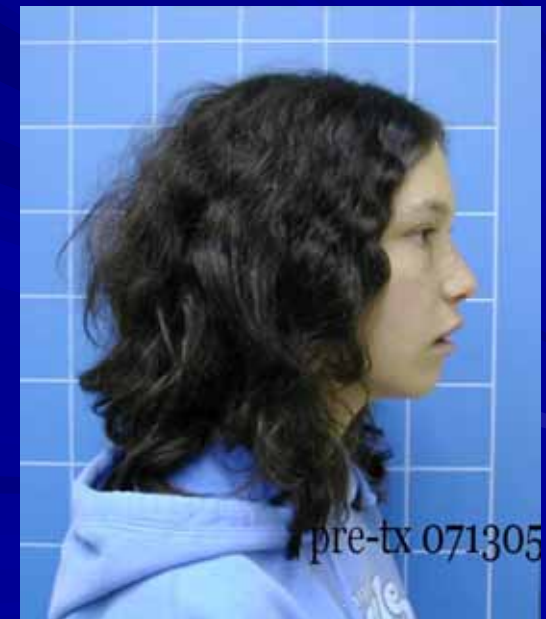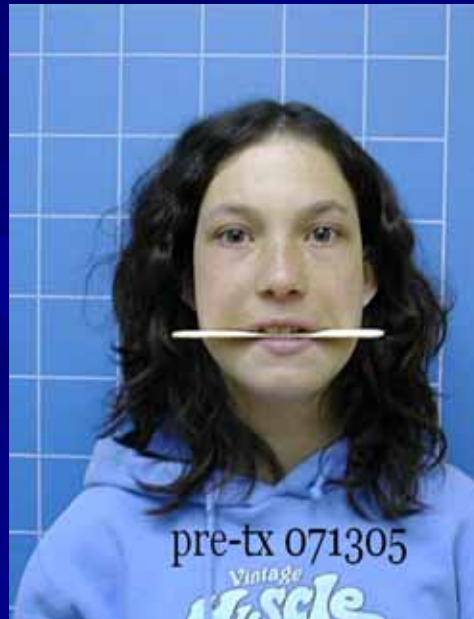Pre-treatment



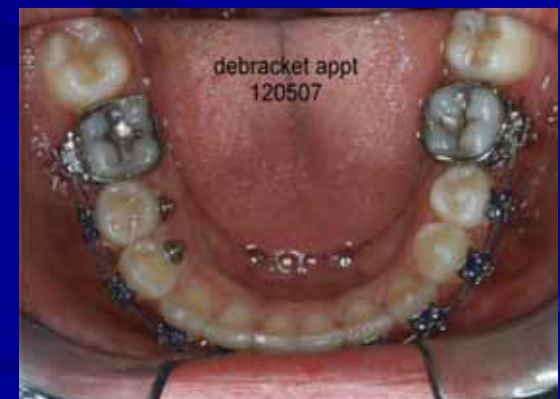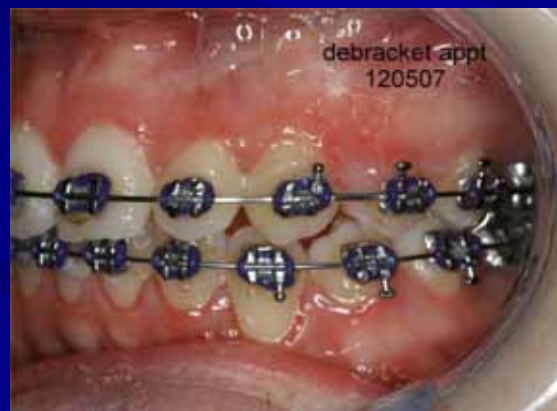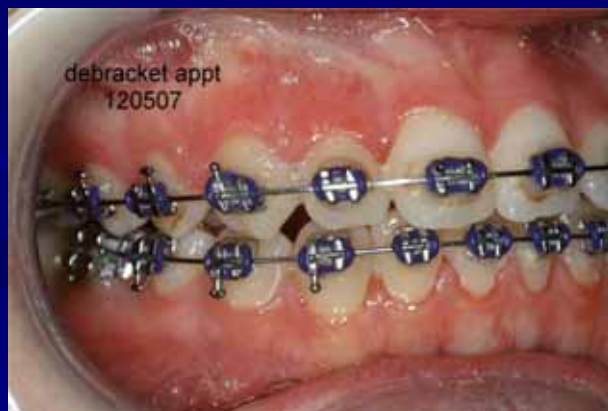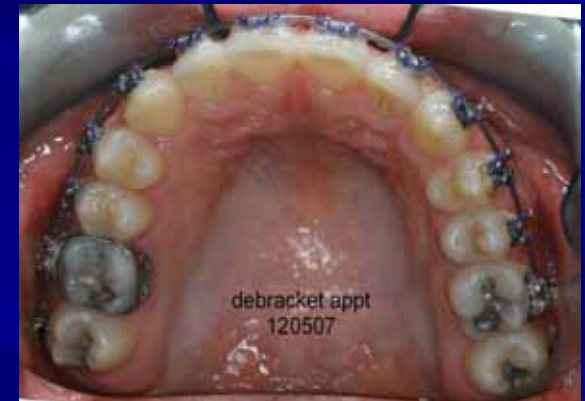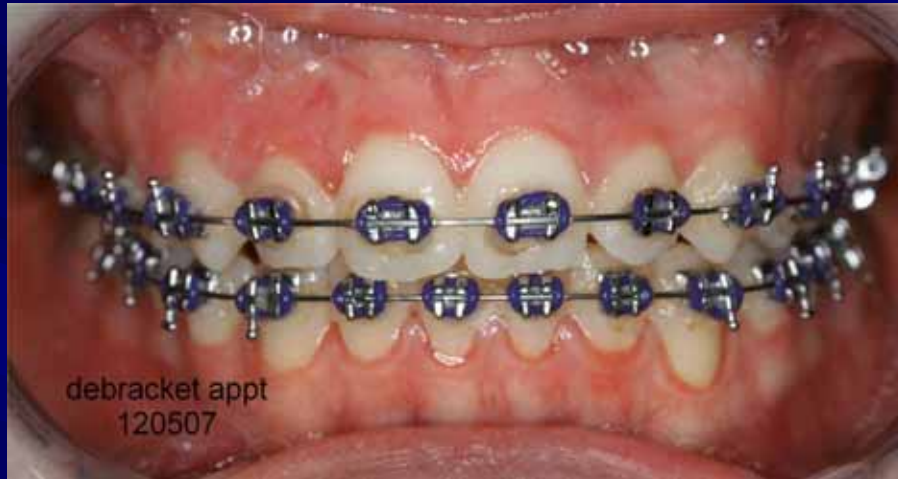
Class II Full tooth

Melissa: 14 years of age

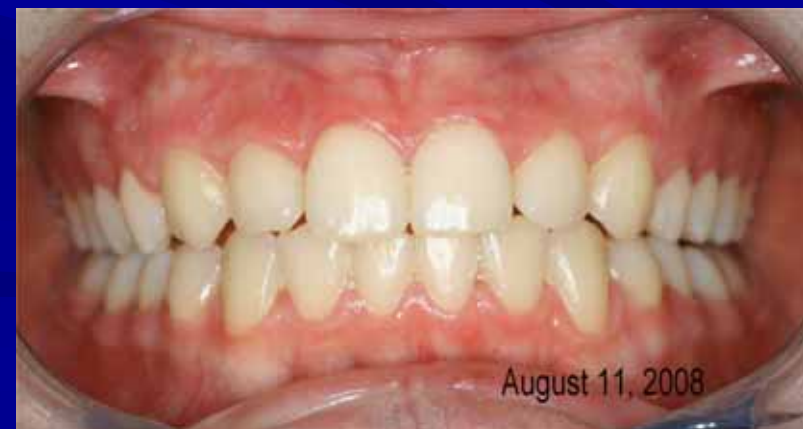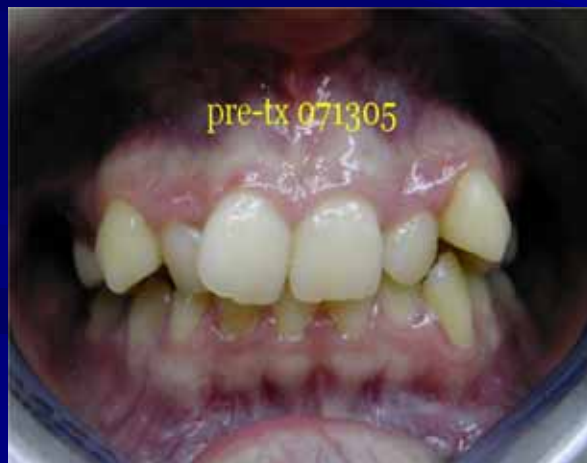Pre-treatment



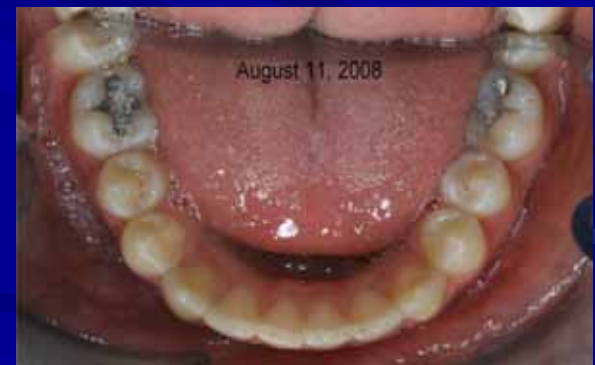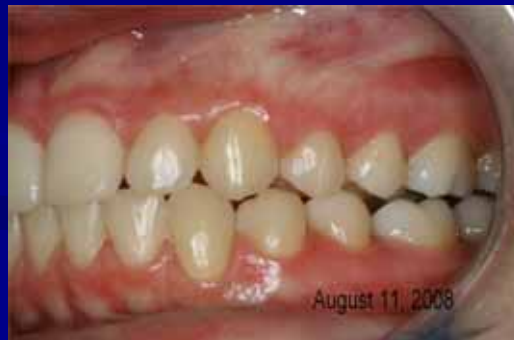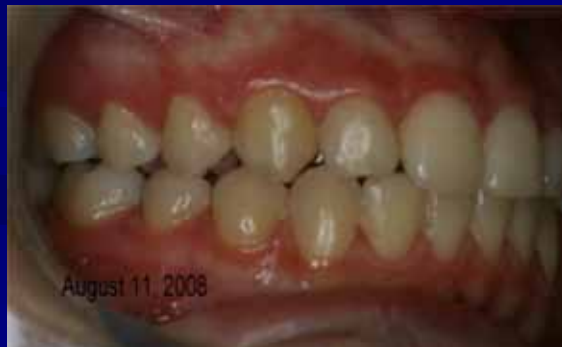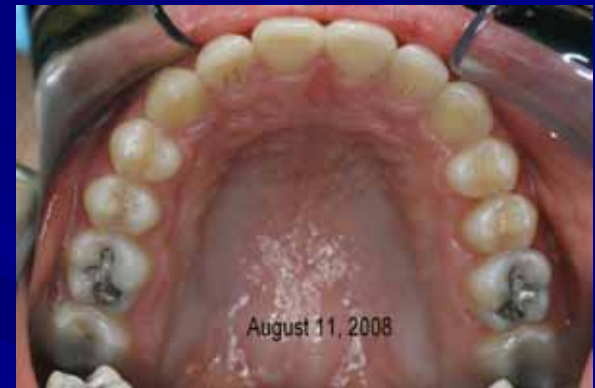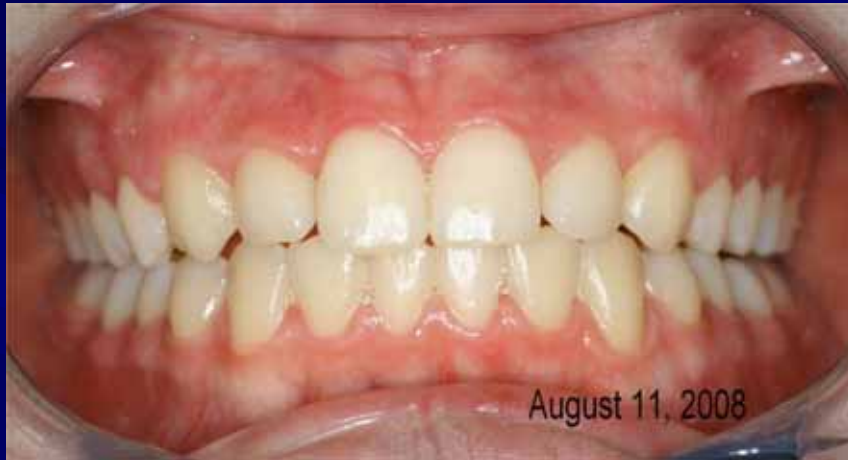Melissa: 17 months full bracket Tx



Melissa: 23 months of active Tx

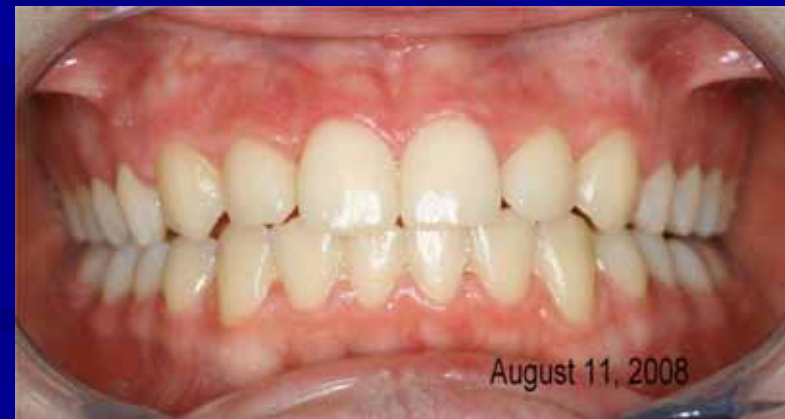

Melissa: Post treatment



Melissa

- Twin Block/upper brackets
5.5 months
- Full brackets 17 months
- Upper Hawley bite ramp
along with brackets 6 months
- Intra oral vertical box elastics
- Positioner for retention
8 months
- Upper & lower slipcovers

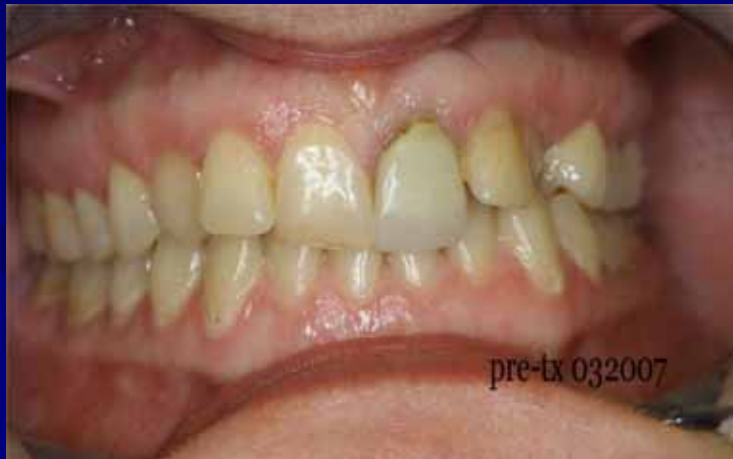

Class II

Rebecca: 33 years of age

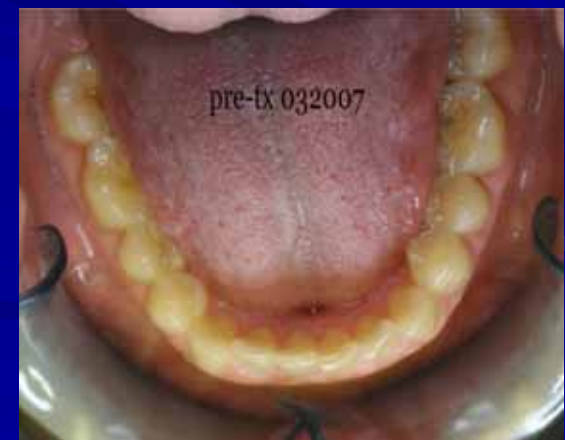
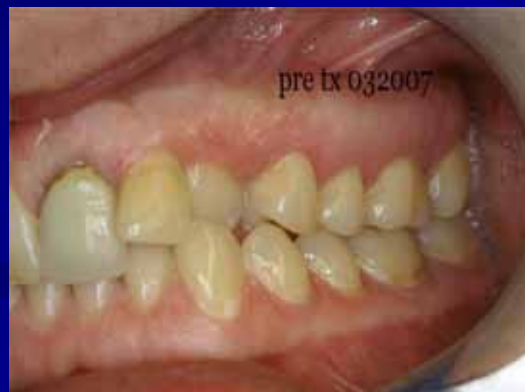
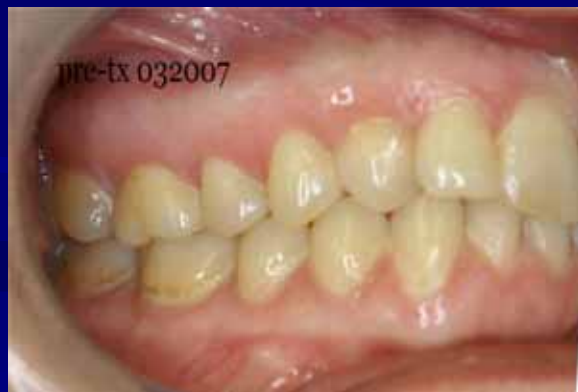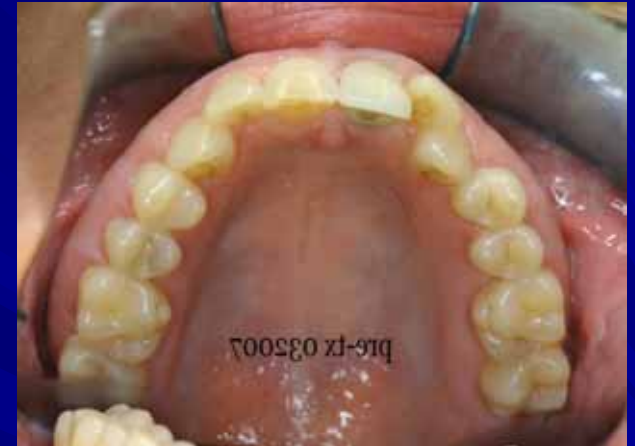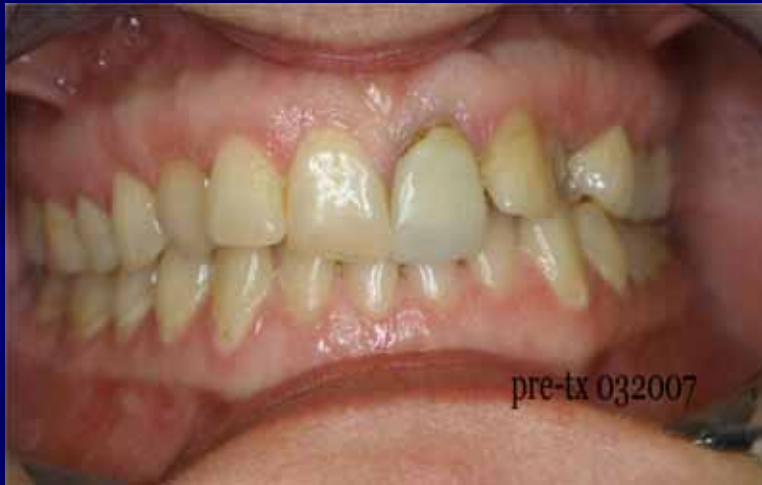- Class II ½ tooth
- Overjet 1mm
- Overbite 50%
- Previous ortho patient
- Headaches/migraines



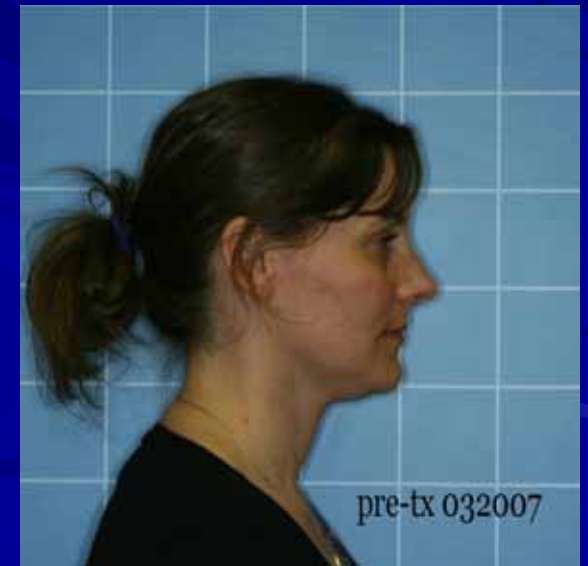Rebecca: 33 yrs of age

Pre-treatment

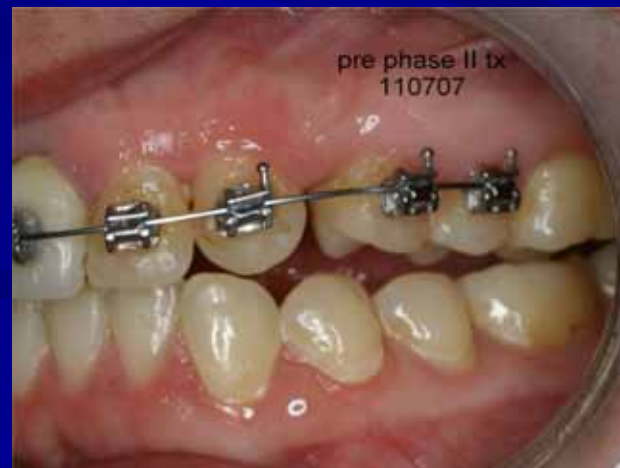
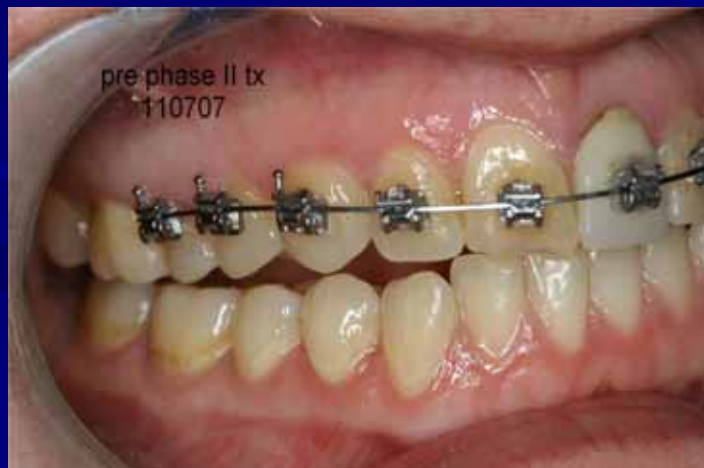
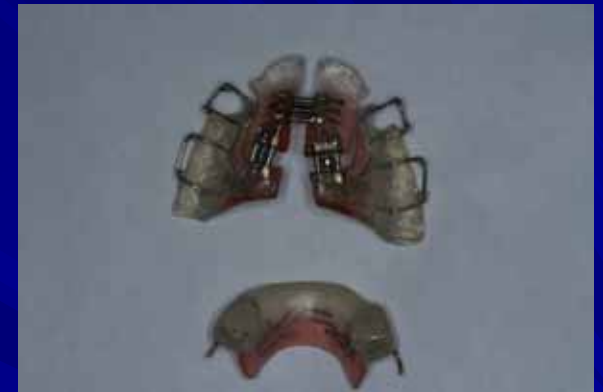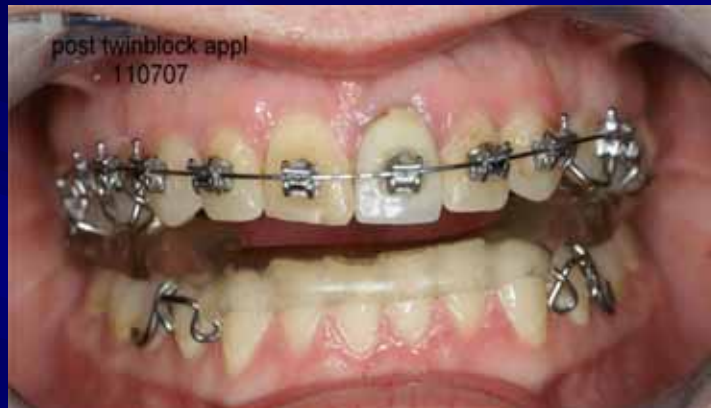Rebecca: 33 years of age

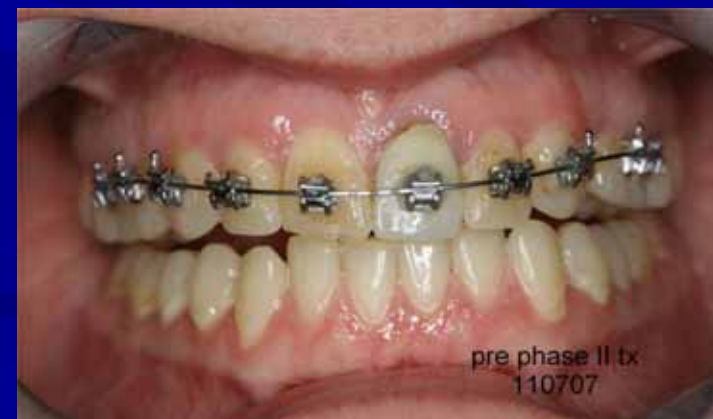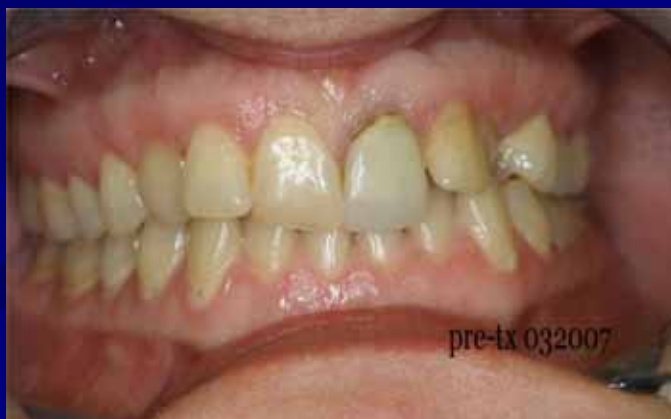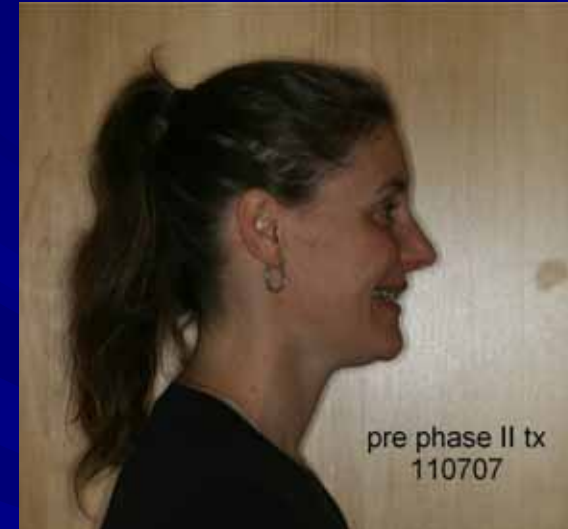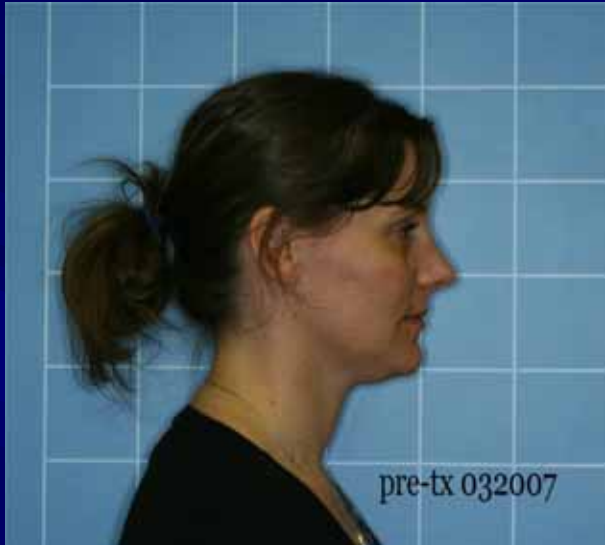
Pre-treatment



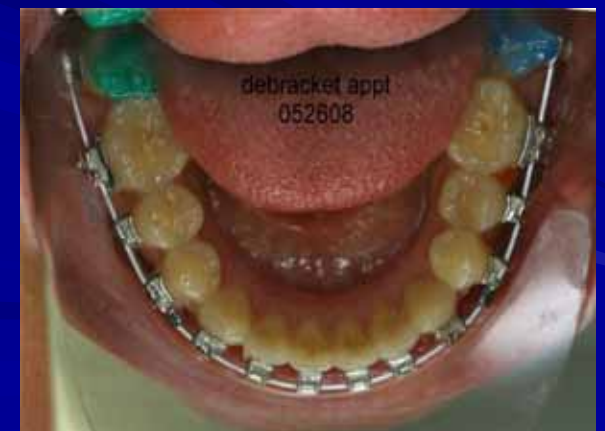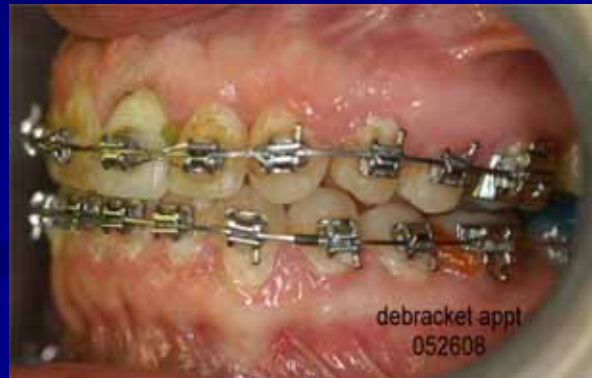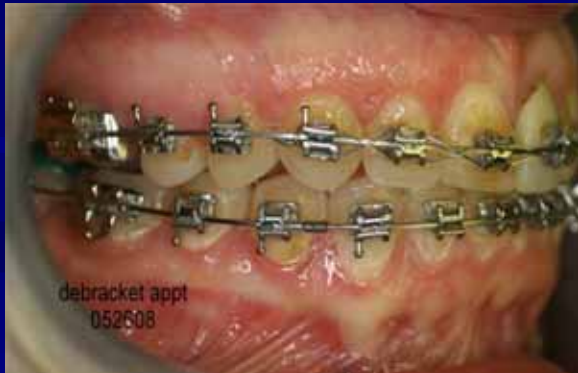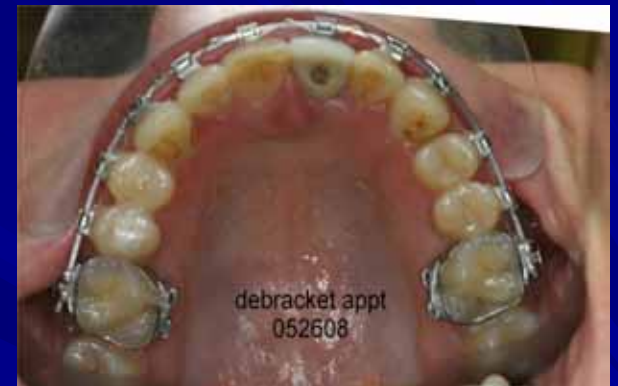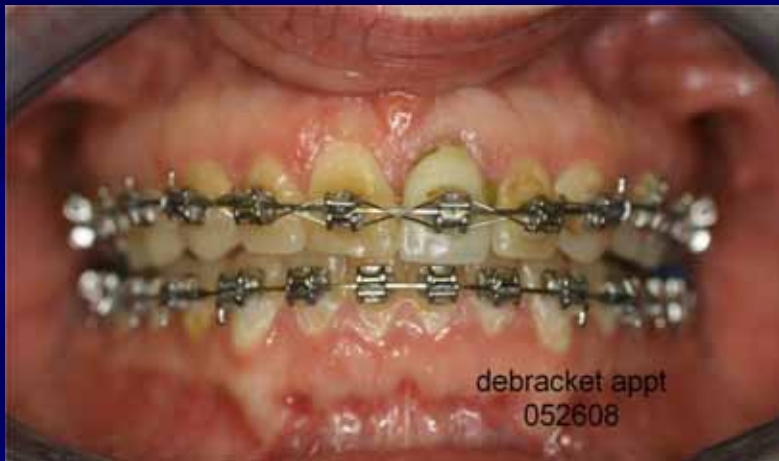Rebecca: Post Twin Block 5 months active wear



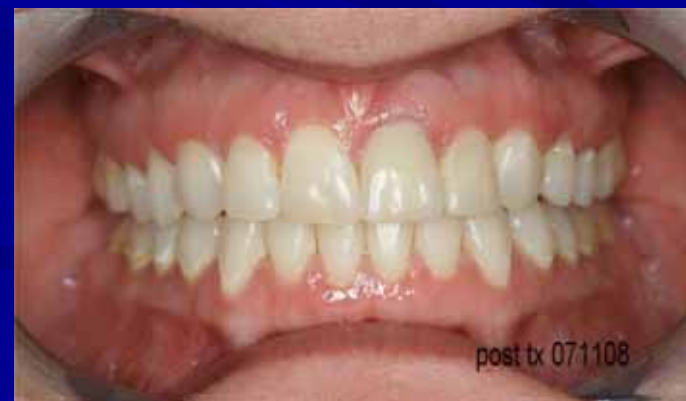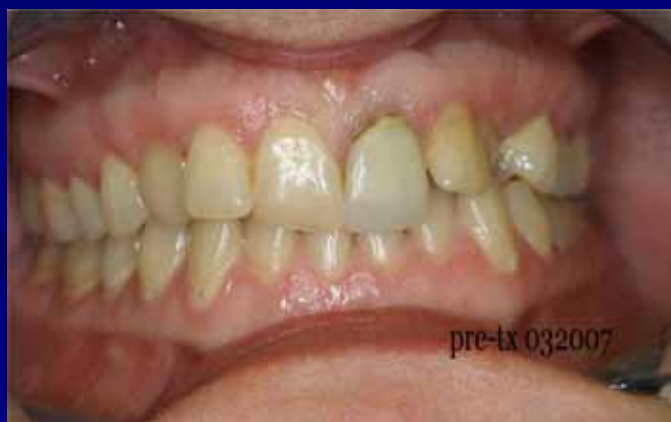Rebecca: Mid treatment



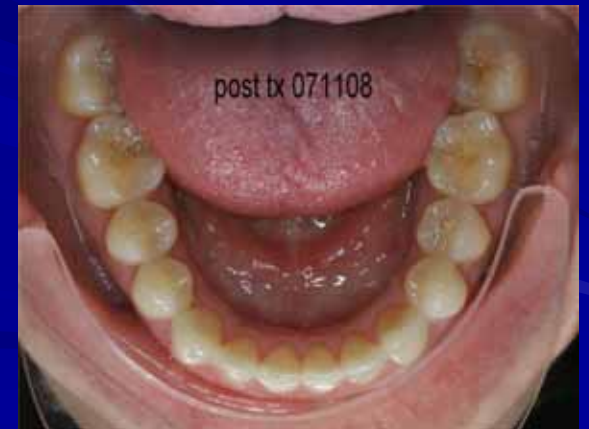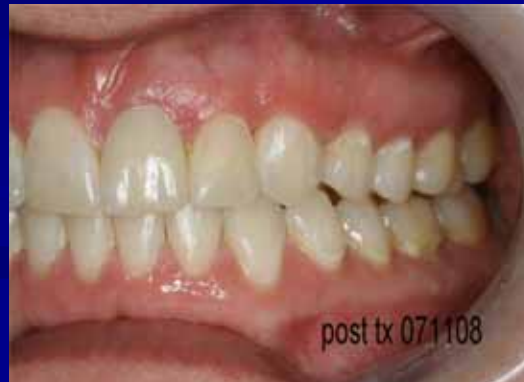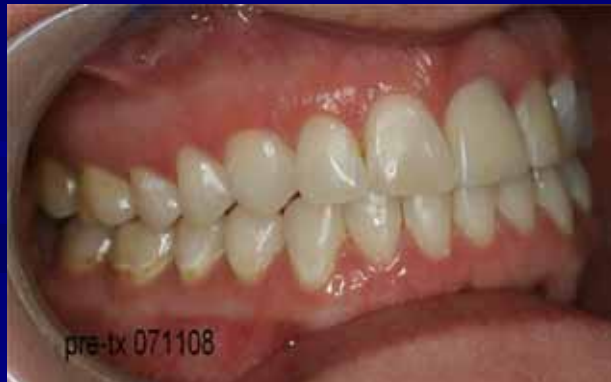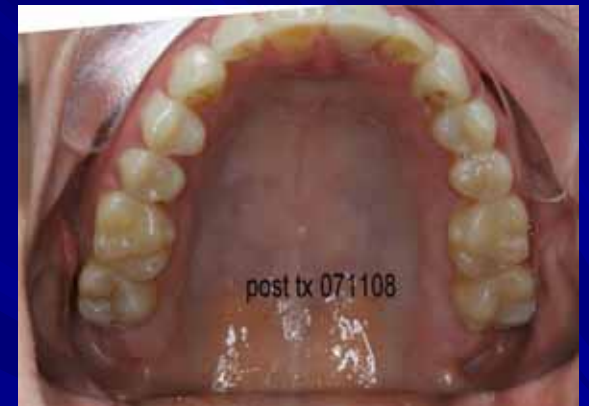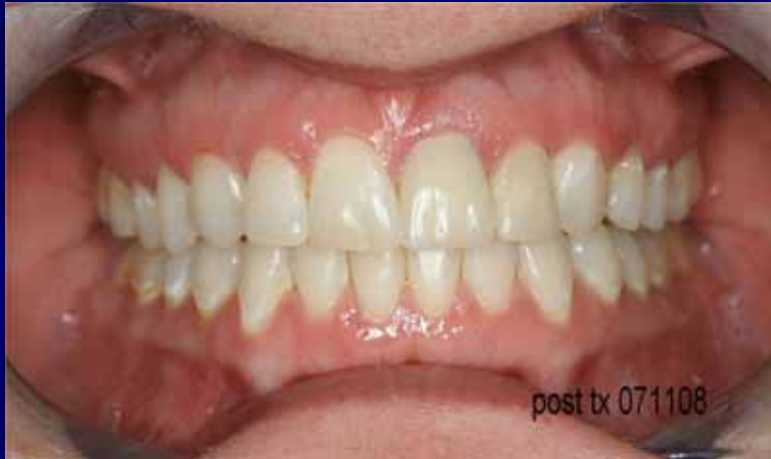Rebecca: Brackets/Rick-a-nator 6 months



Rebecca: Pre/Post 12 months active treatment

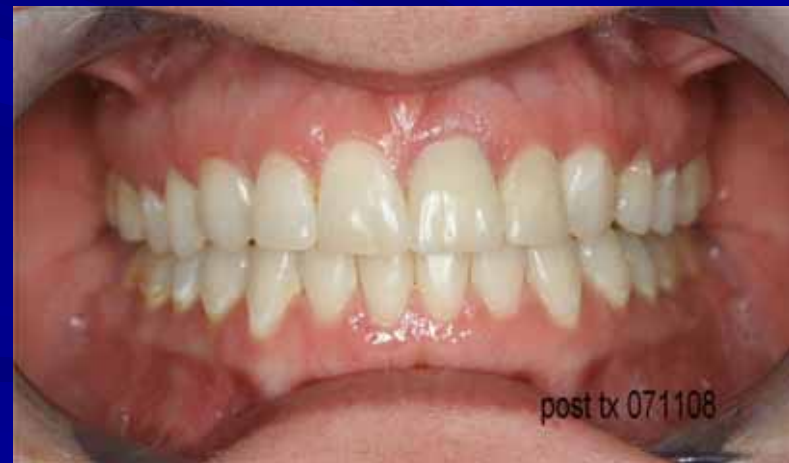

Rebecca: Post treatment



Rebecca

- Twin Block with upper brackets 5 months
- Rick-a-nator/lower tripod & full brackets
- NO HEADACHES
- Positioner for retention
- Zoom whitening
- Replaced 21 crown
- Got Married Aug 8, 2008



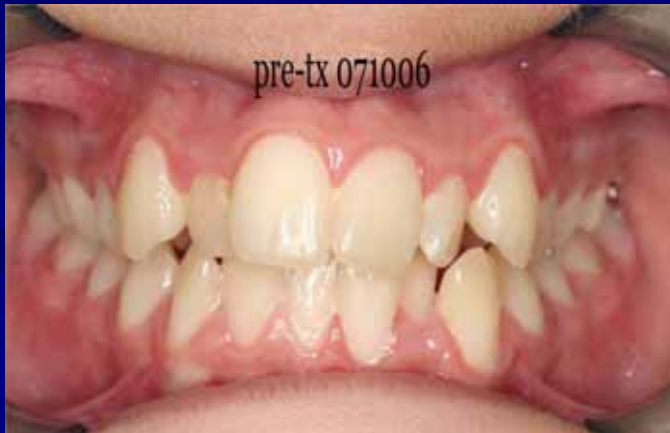Class I Molar Sagittal Treatment

Class I

Shayla: 11 years of age



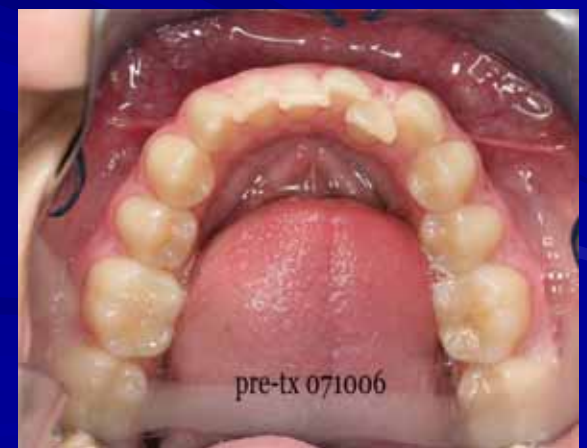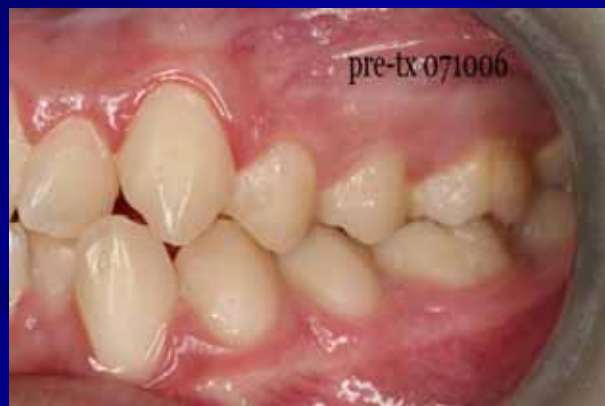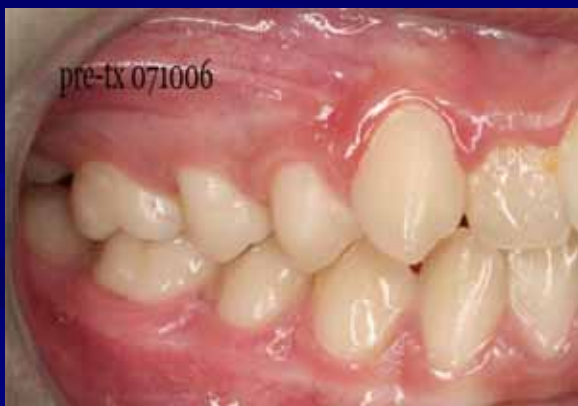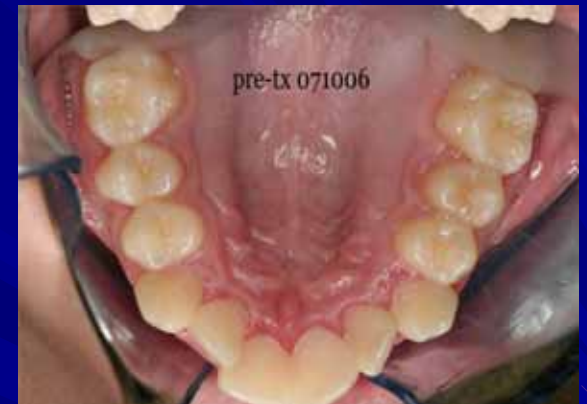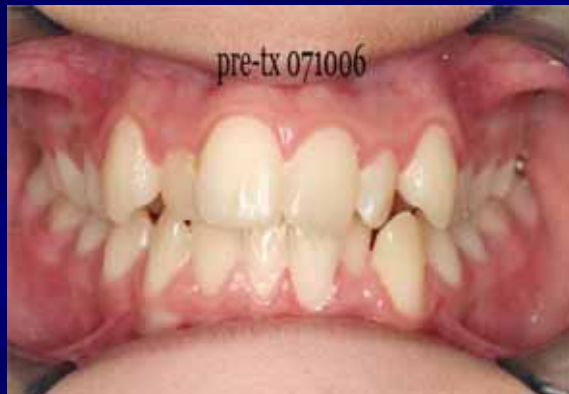- Class I $\frac{1}{2}$ tooth
- Overjet 4 mm
- Overbite 20%



Class I

Shayla: 11 years of age

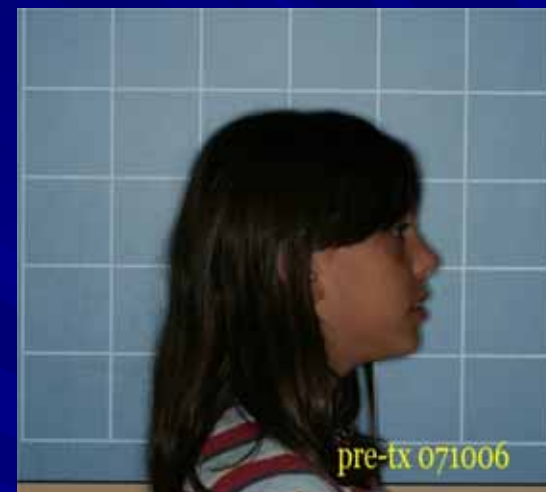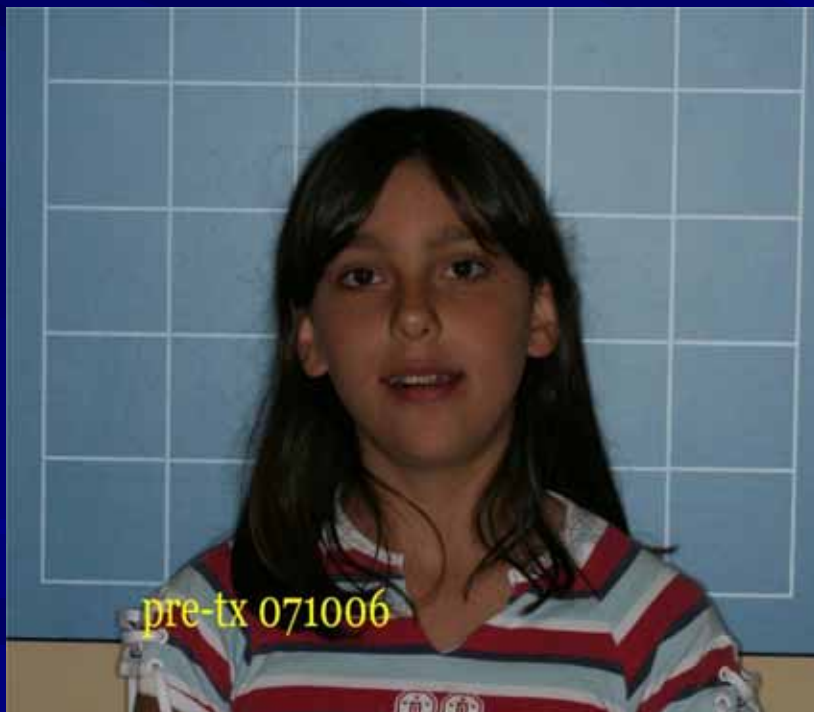Pre-treatment



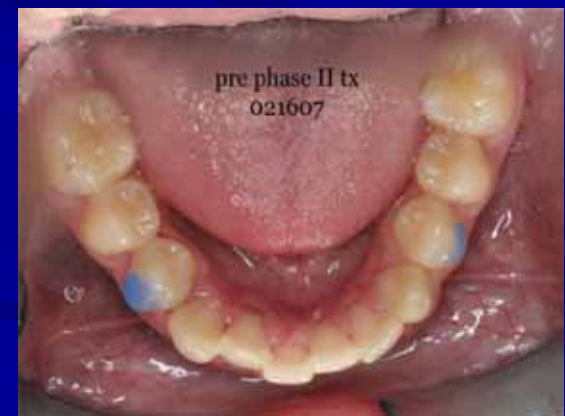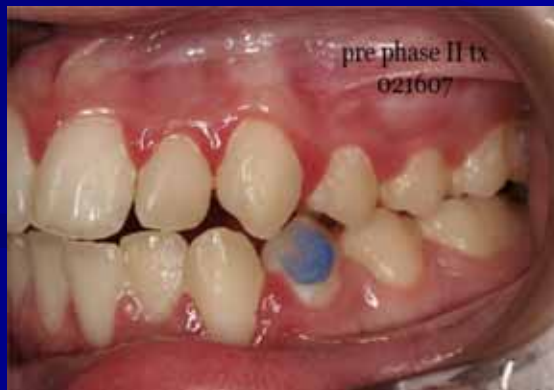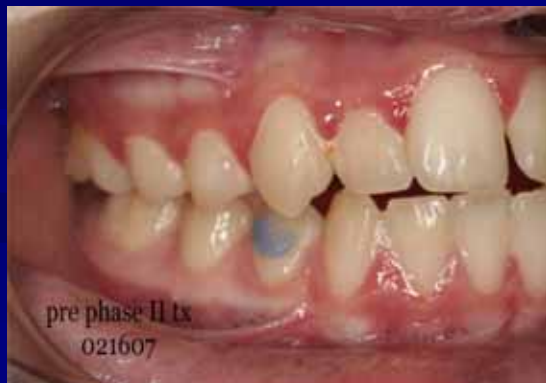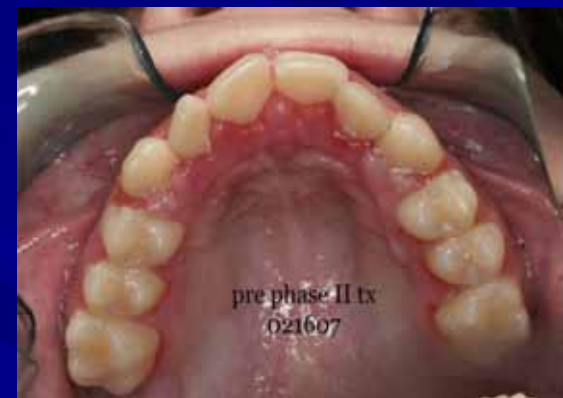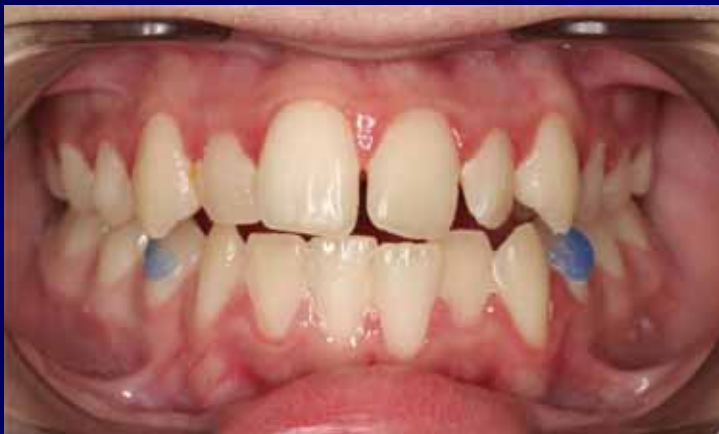Class I

Shayla: 11 years of age

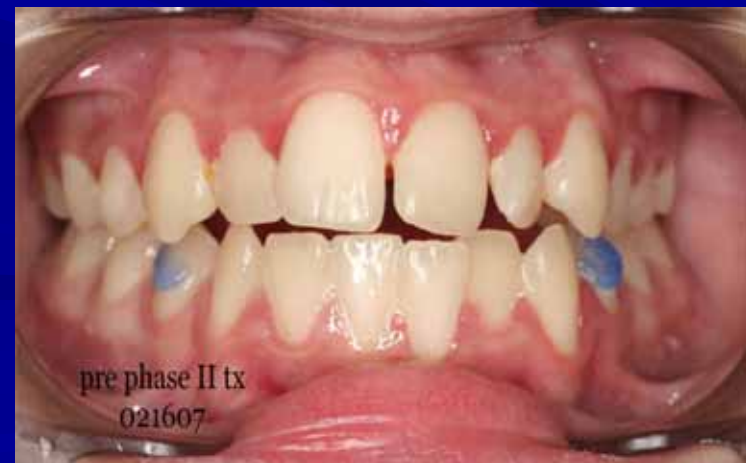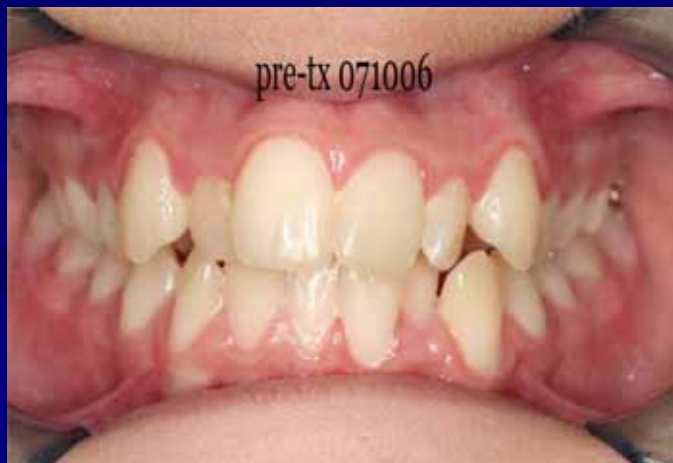Pre-treatment



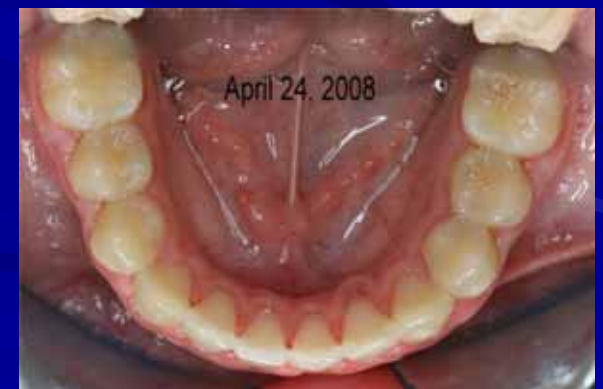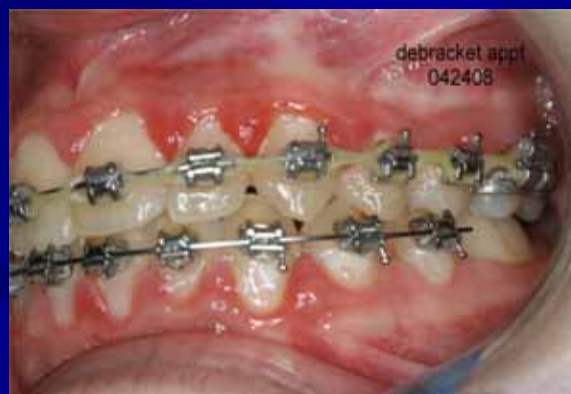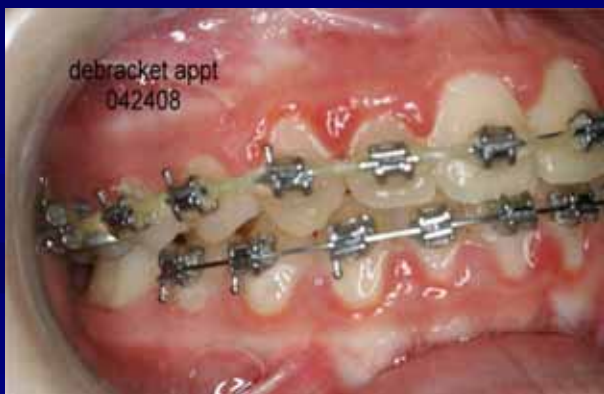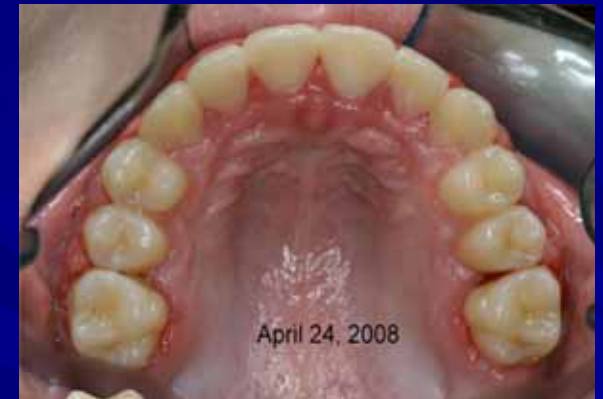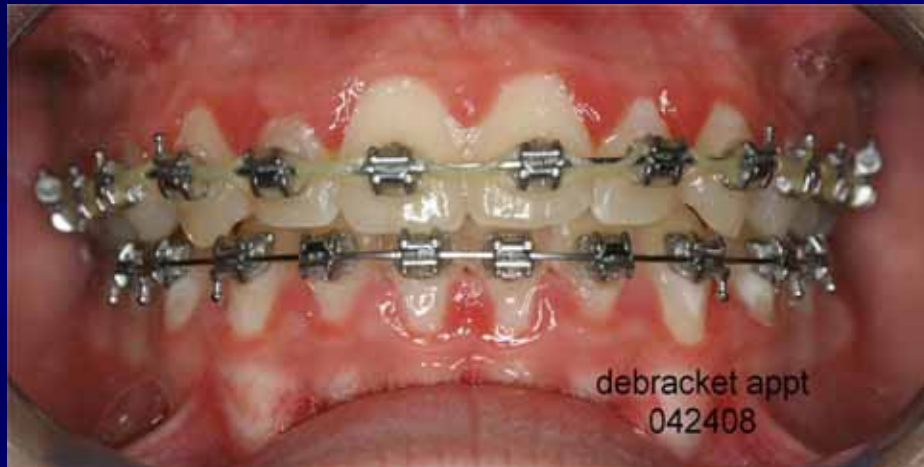Shayla: Post upper/lower Sagittals 6 months active wear



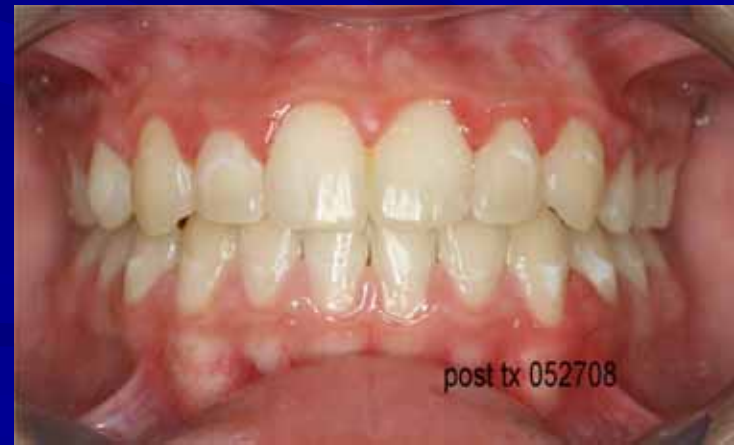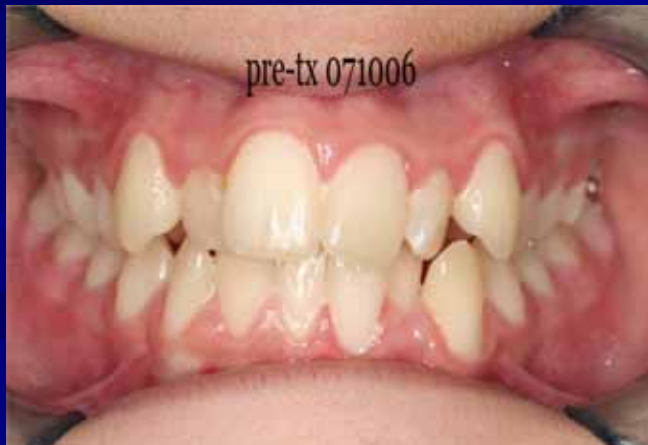Shayla: Mid Tx



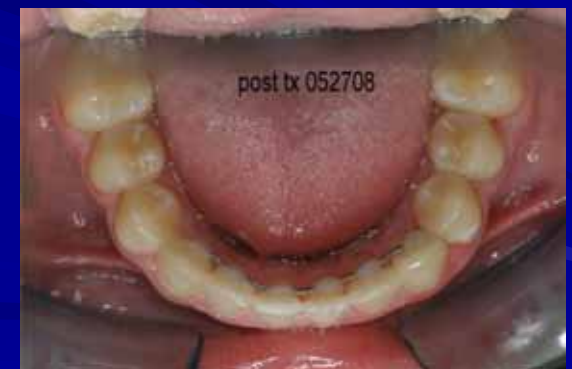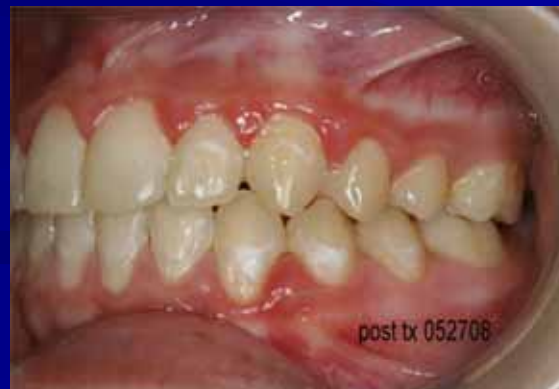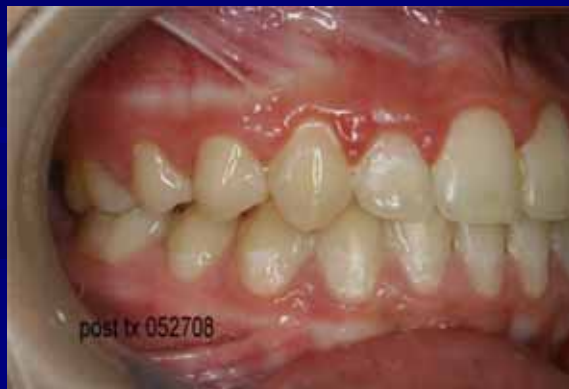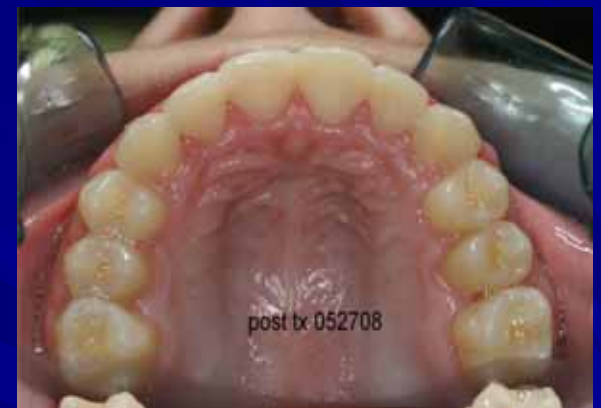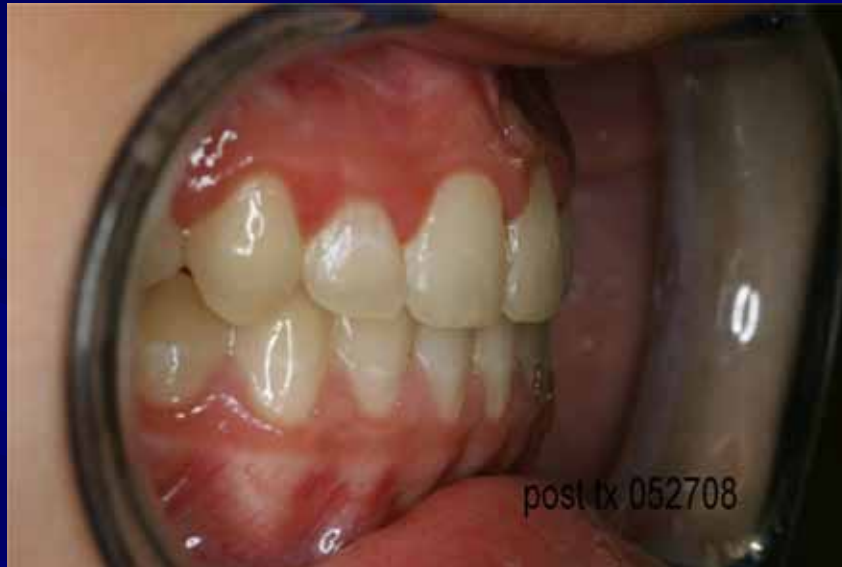Shayla: 14 months full brackets Tx



Shayla: 20 months of active Tx

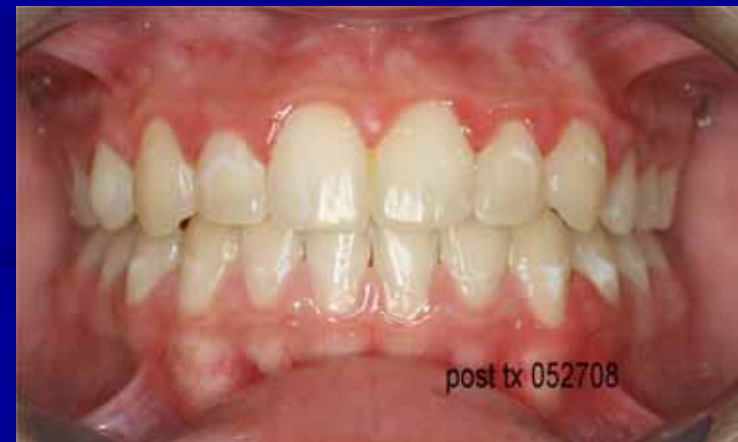

Shayla: Post Tx



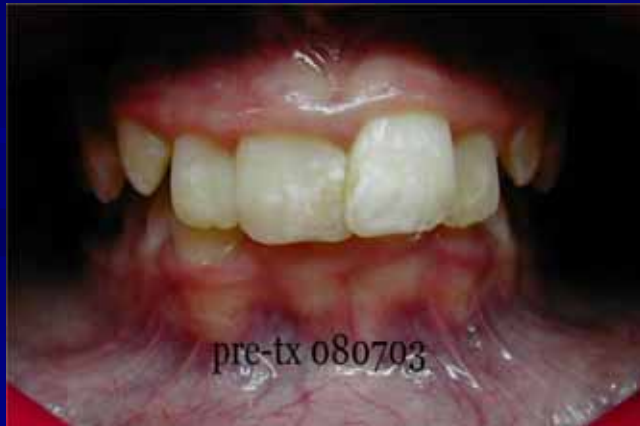Shayla

- Upper 3-way Sagittal/lower 2 ways Sagittal 6 months
- Extract lower second molars
- Full brackets 14 months
- Upper Quad Helix/lower removable holding arch
- Extraction of upper second molars
- Removal of Quad/holding arch at 7 months
- De-bracket upper Hawley/lower 3x3 for retention



Class I

Robert: 7 years of age

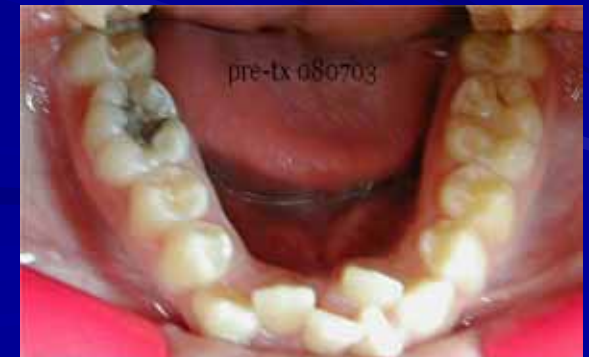
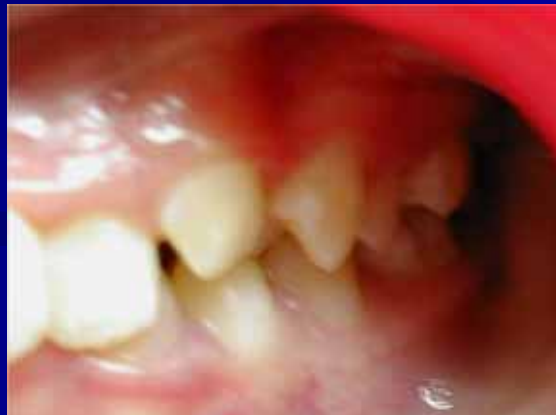
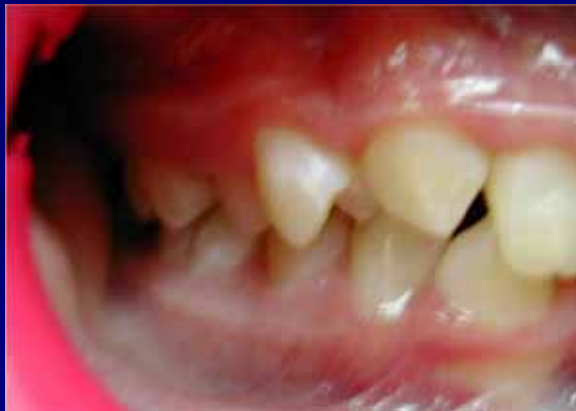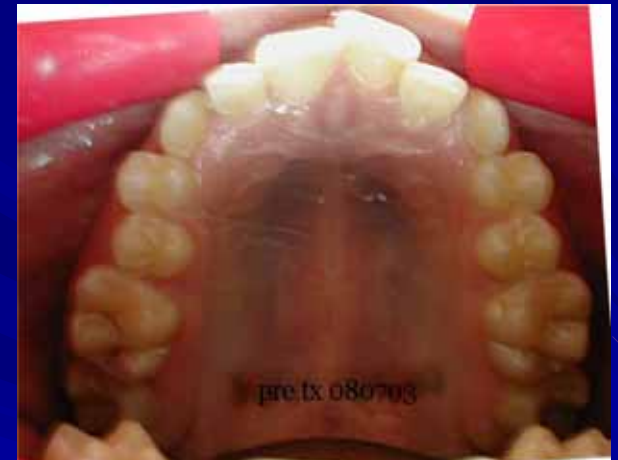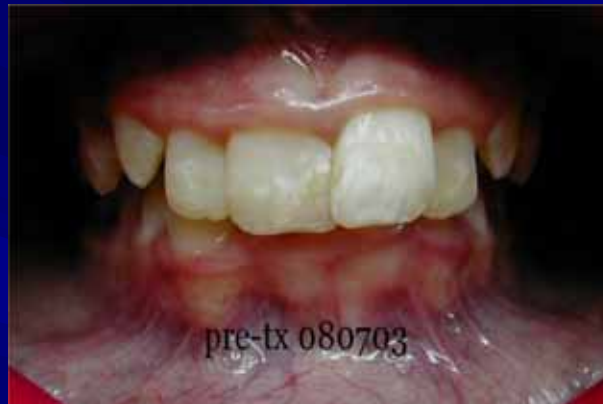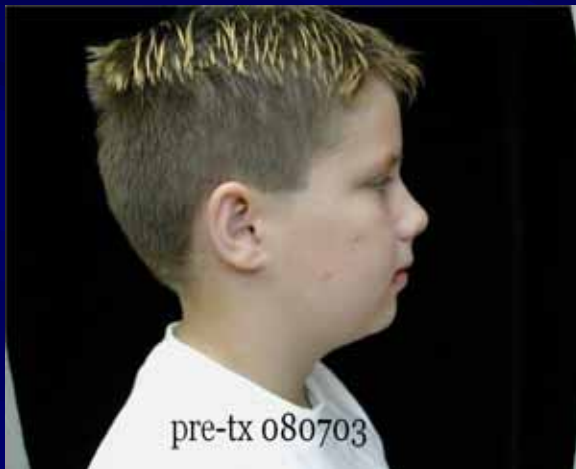- Class I full tooth
- Overjet 3 mm
- Overbite 90%
- Class I facial profile
- Concern: Severe lower crowding

Class I

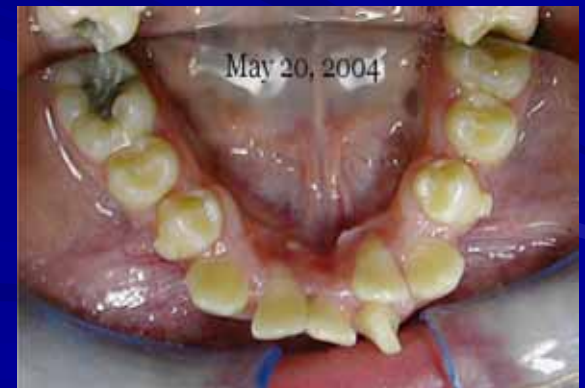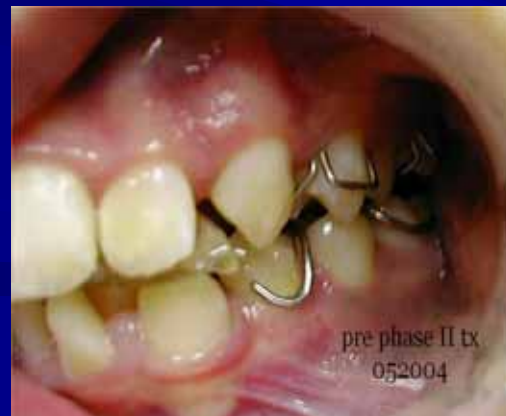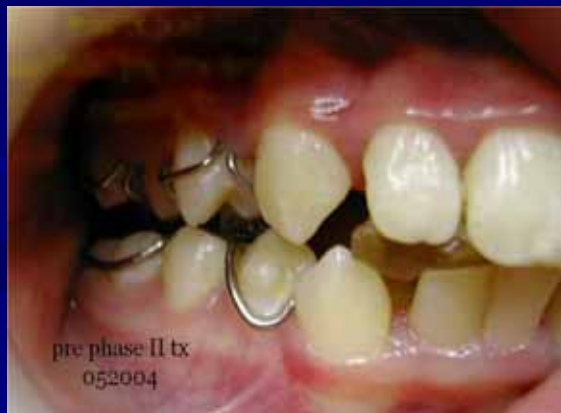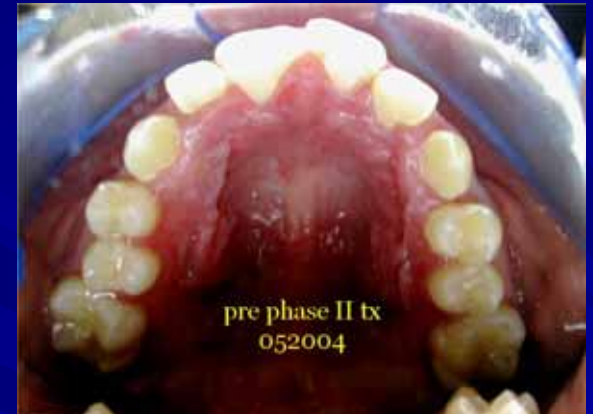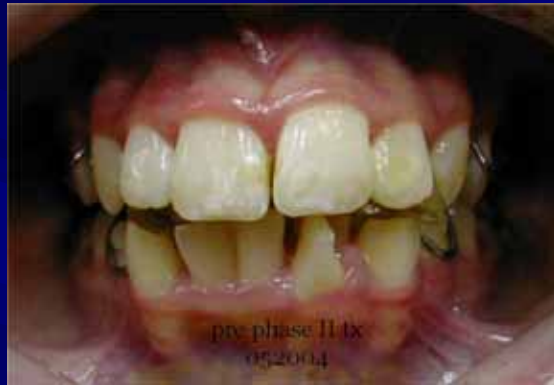Robert: 7 years of age

Pre-treatment

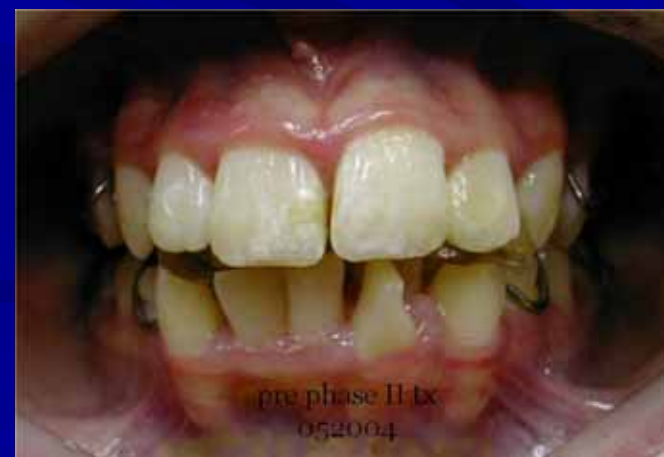
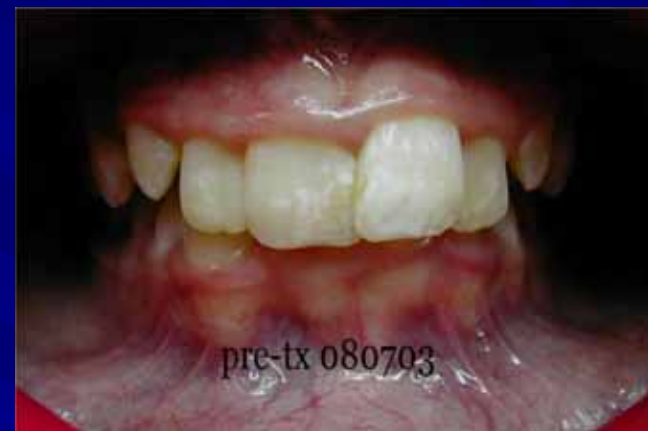
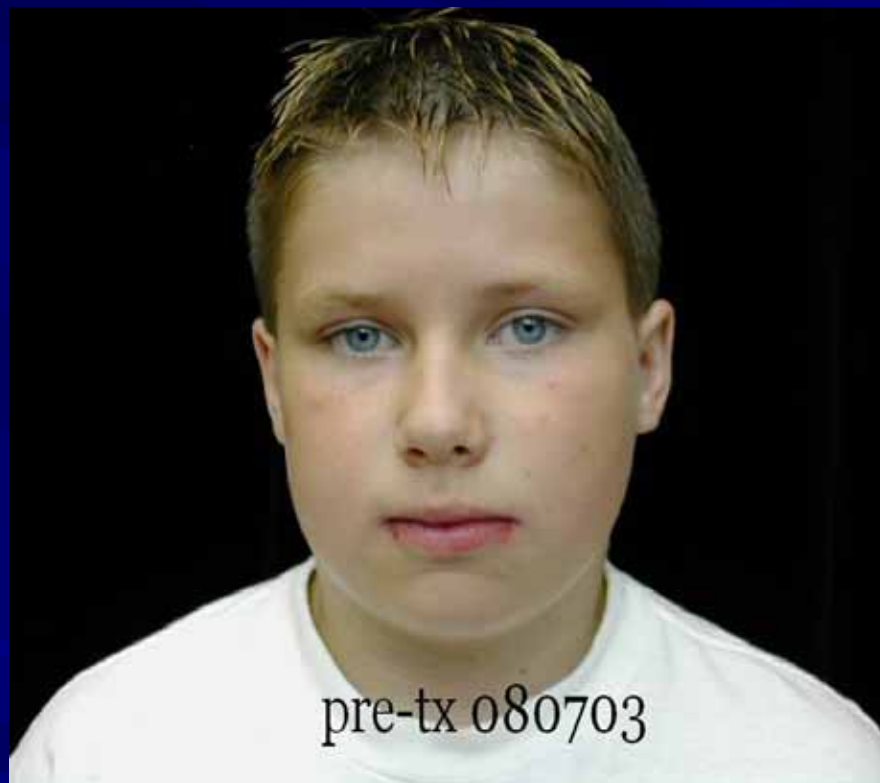Robert: Upper/lower Sagittals

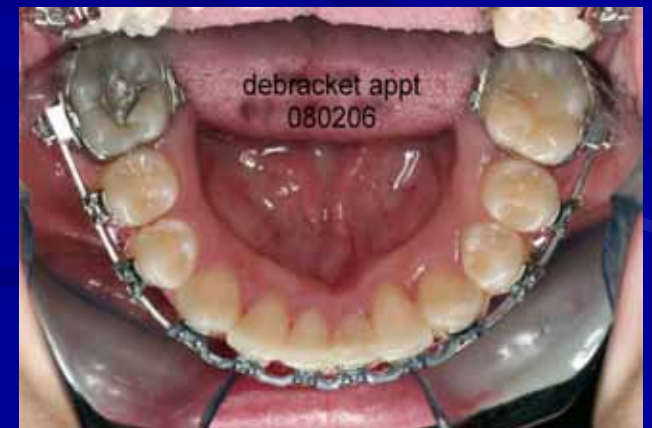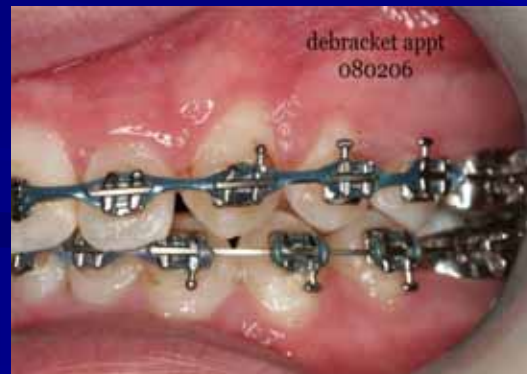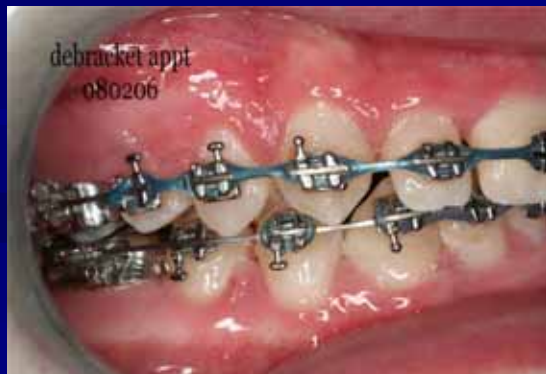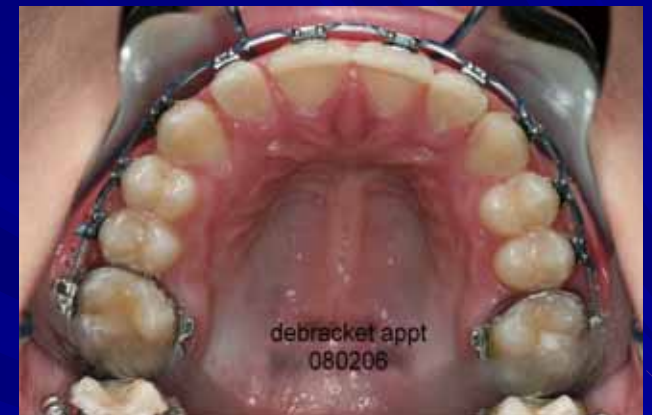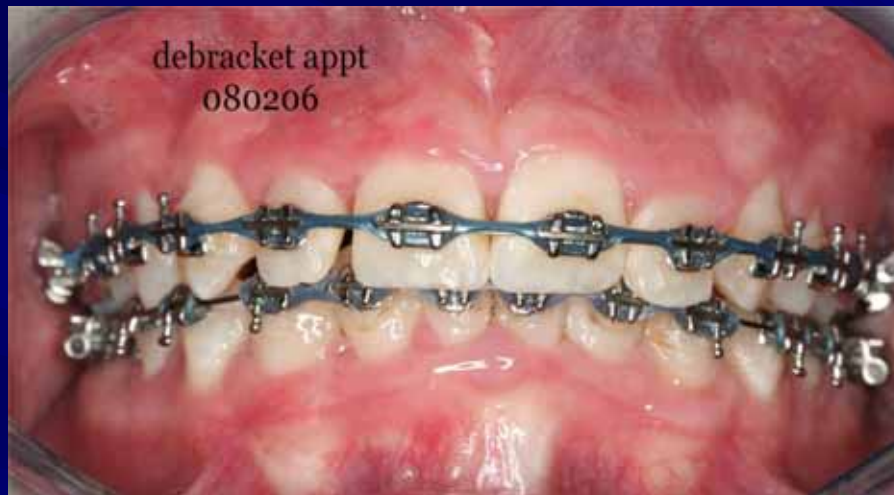7 months active wear



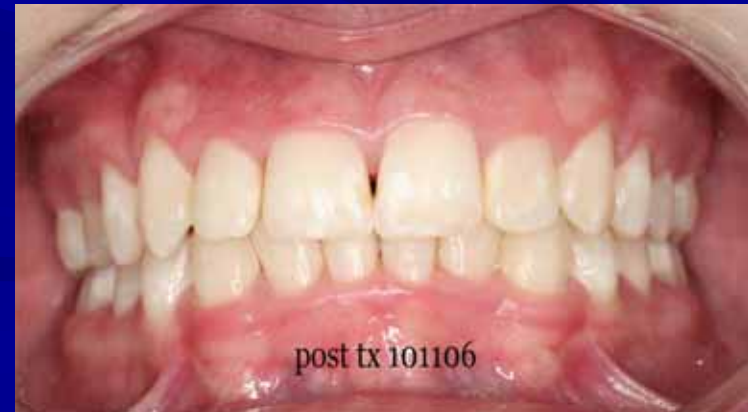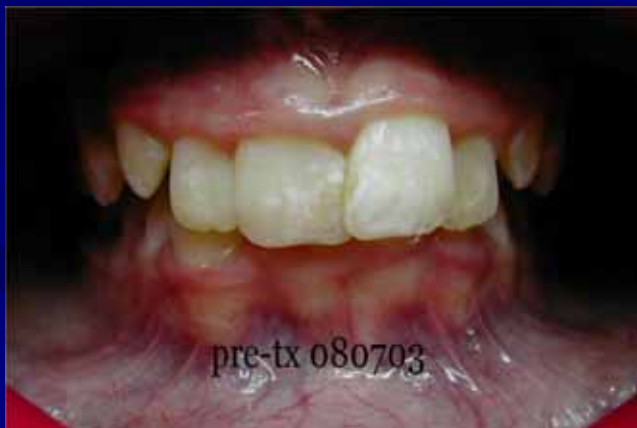Robert: Mid treatment



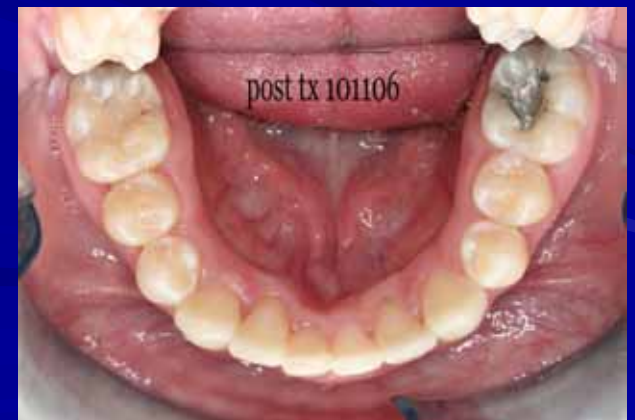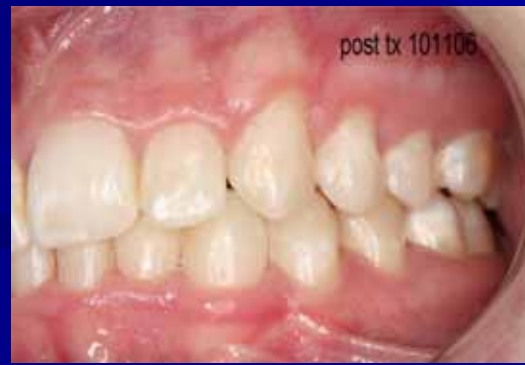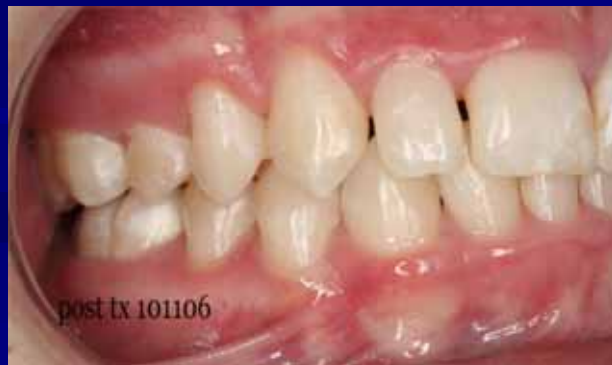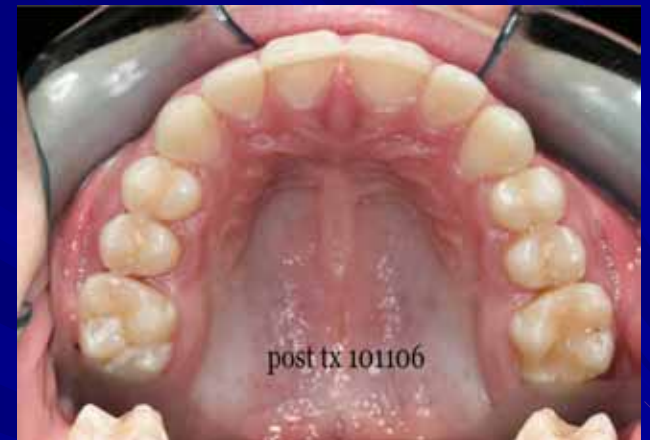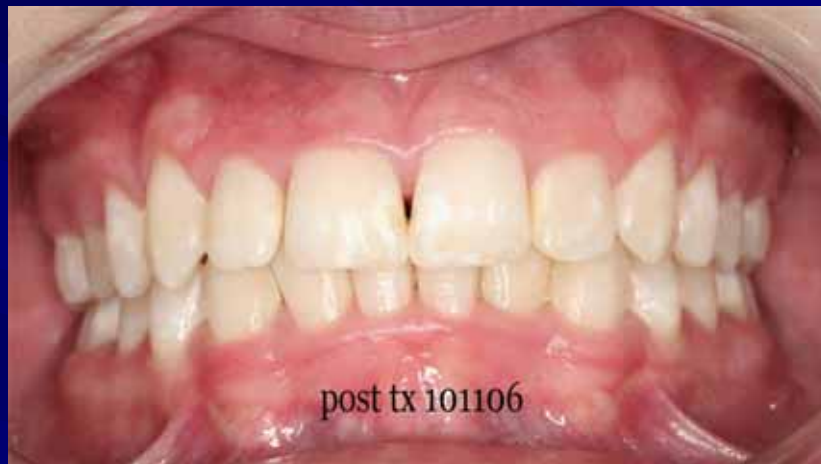Robert: 27 months full bracket Tx



Robert: 34 months active treatment

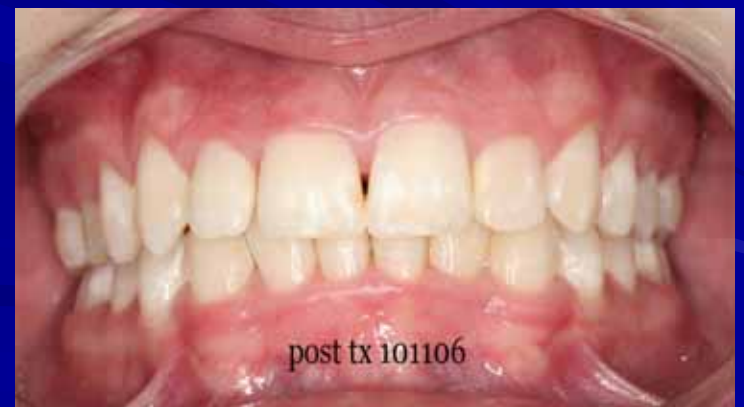

Robert: Post treatment



Robert

- Extraction of upper/lower second molars
- Upper 3-way/lower 2-way Sagittals 7 months
- Full brackets 27 months
- Upper Quad Helix/lower holding arch & lip bumper
- Removed Quad Helix at 14 months replaced with Rick-a-nator
- Removed Rick-a-nator at 4 months
- 31 fiberotomy before de-bracket
- De-bracket, positioner for retention 4 months
- Presently upper slipcover/lower 3x3 for retention



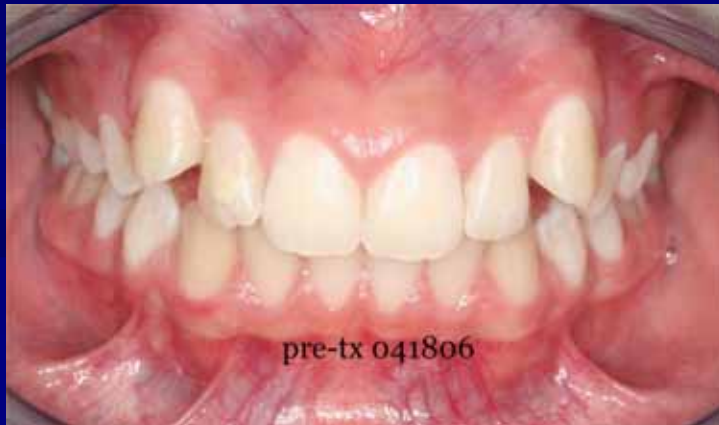Class II Molar Sagittal Treatment

Class II

Brittany: 13 years of age



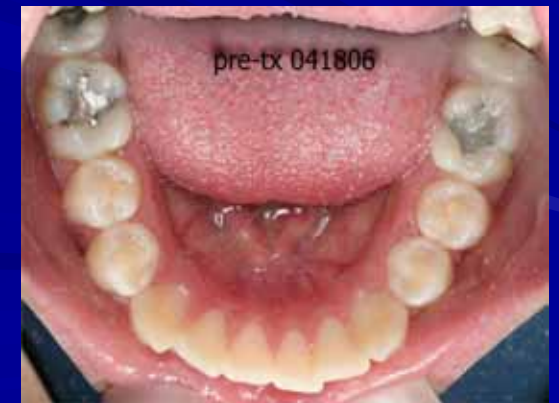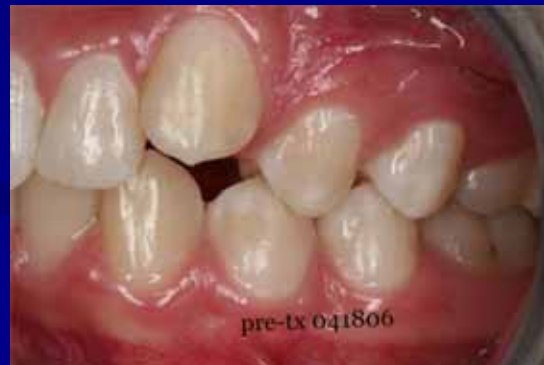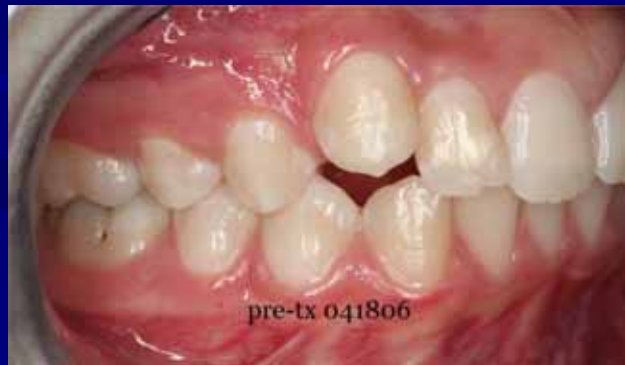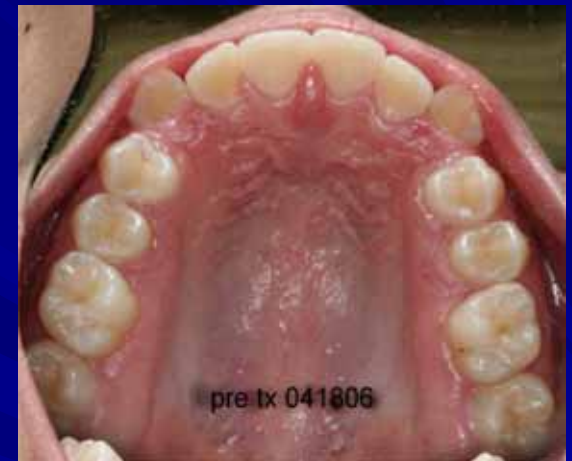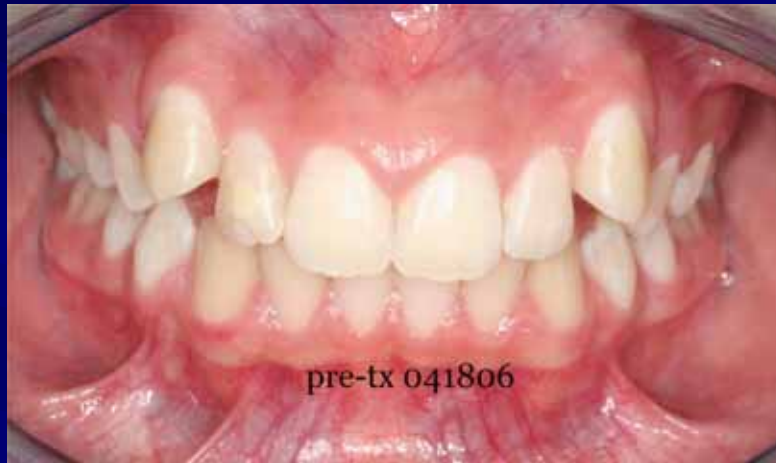- Class II ½ tooth
- Overjet 2 mm
- Overbite 30%
- Concern: Crowding



Class II

Brittany: 13 years of age

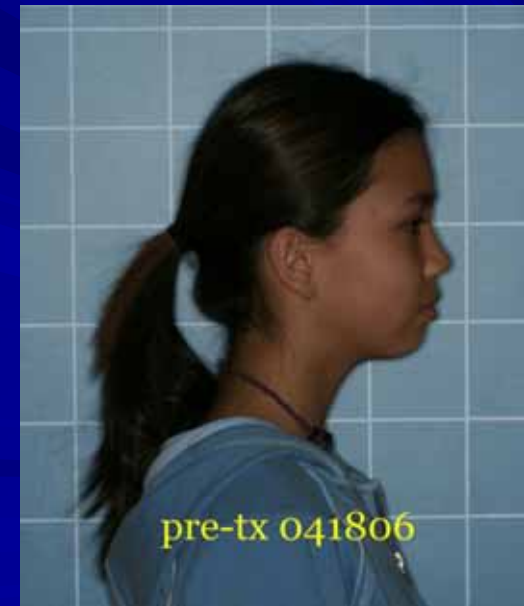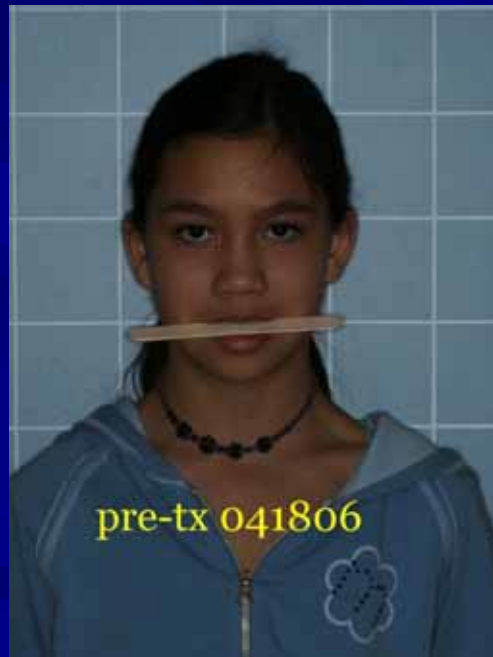Pre-treatment



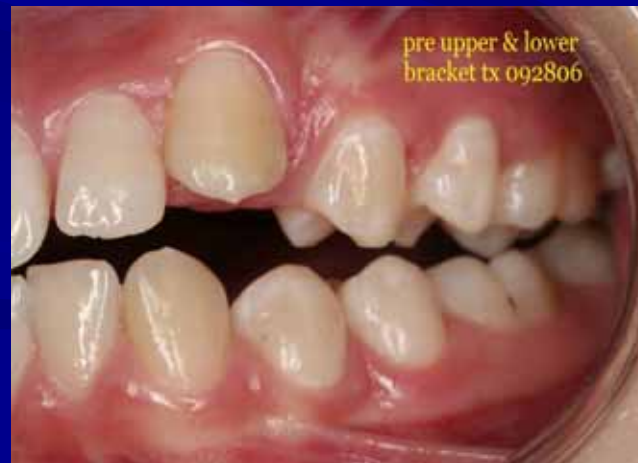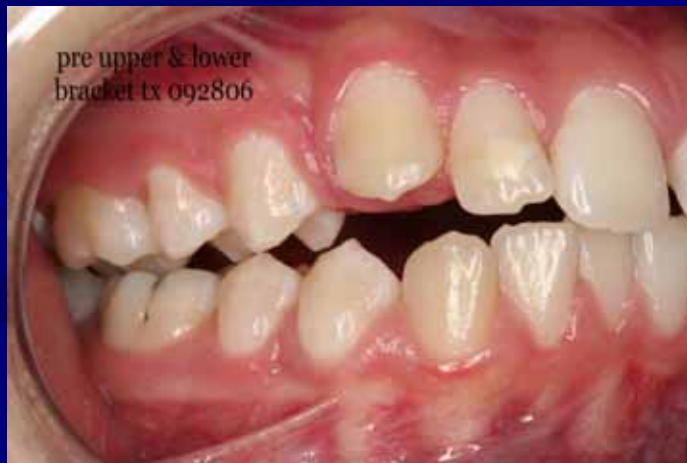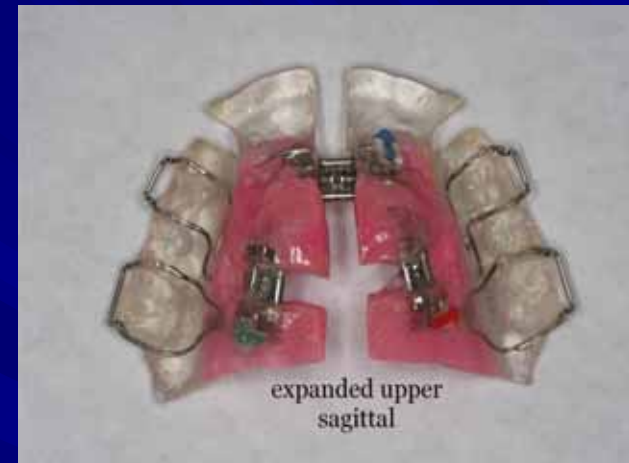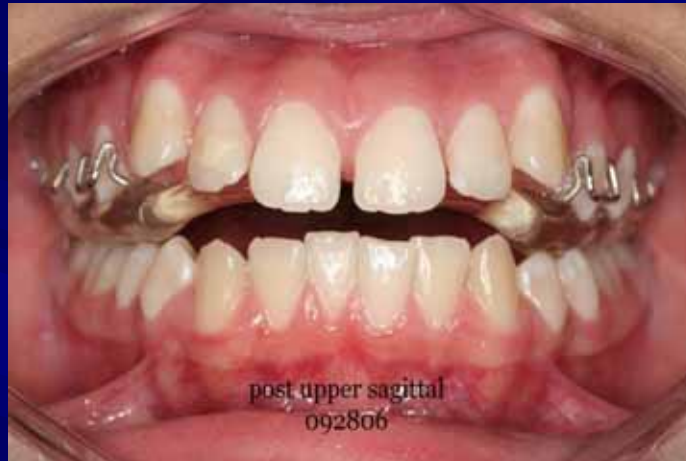Class II

Brittany: 13 years of age

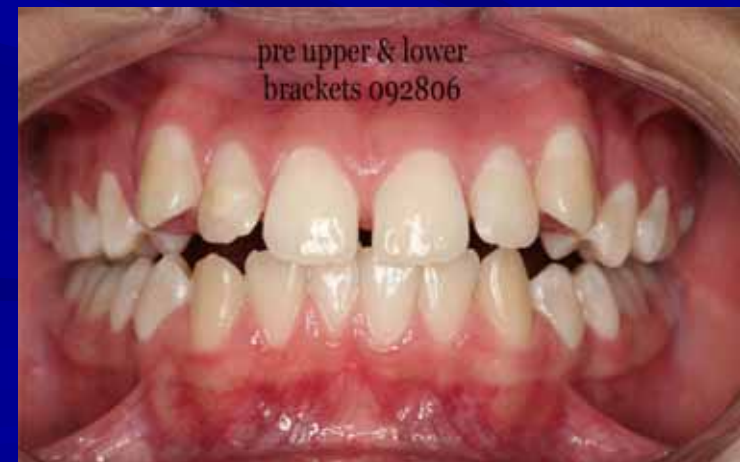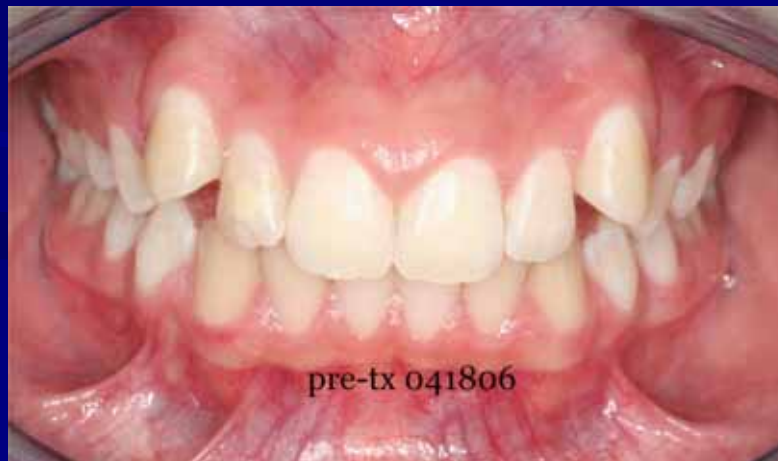Pre-treatment



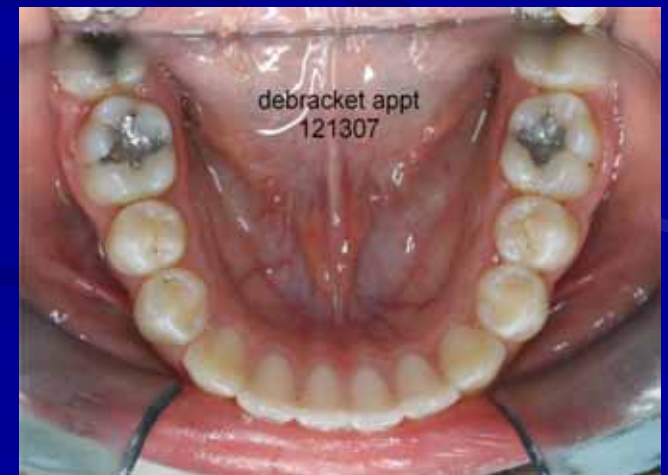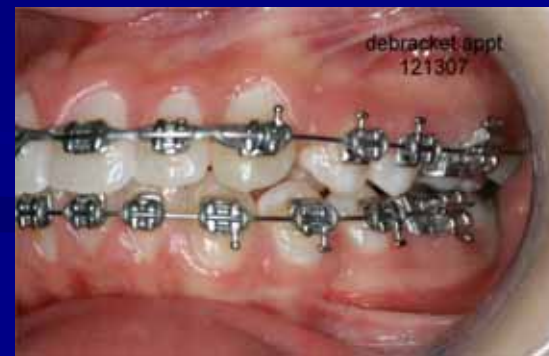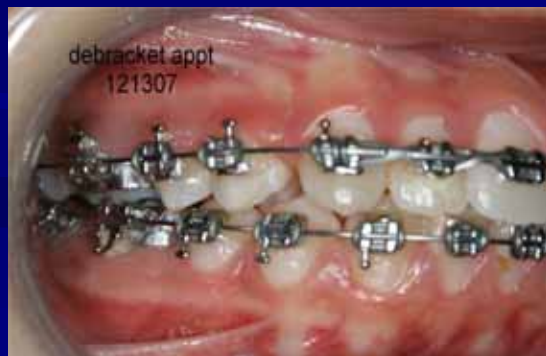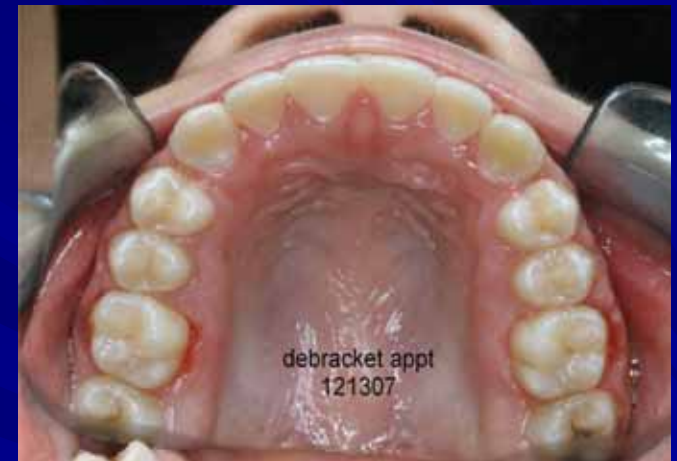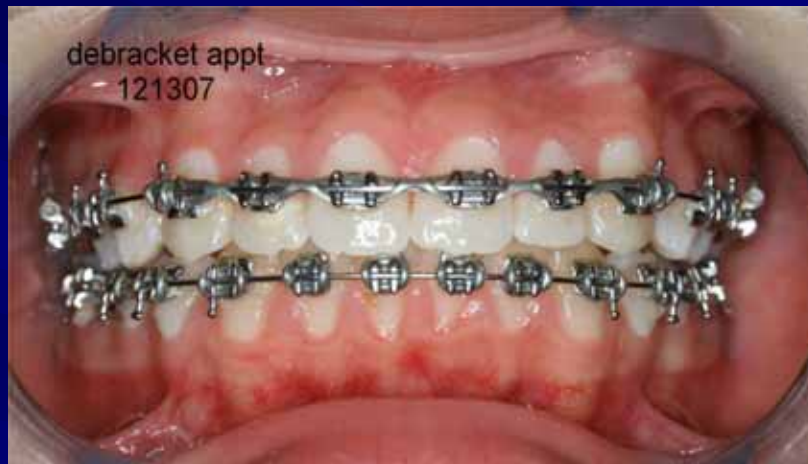Brittany: Post upper Sagittal 4 months active wear



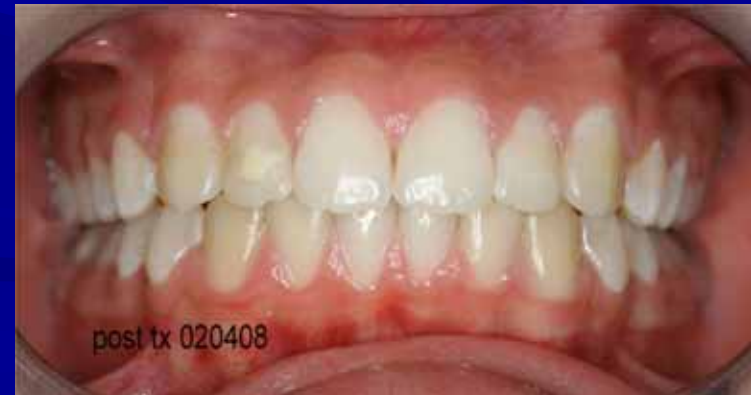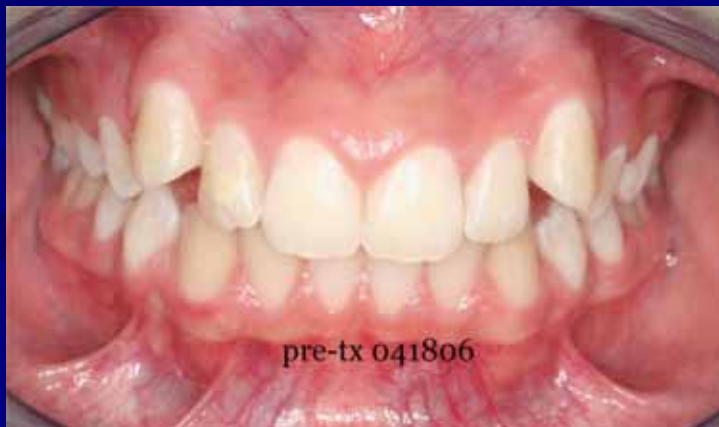Brittany: Mid treatment



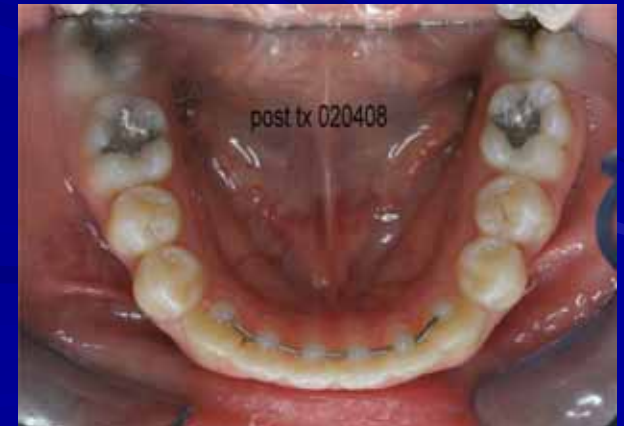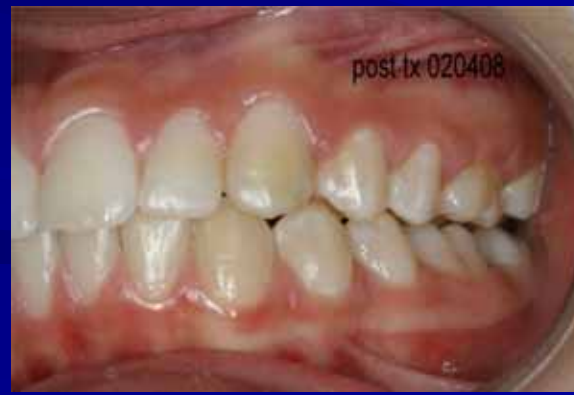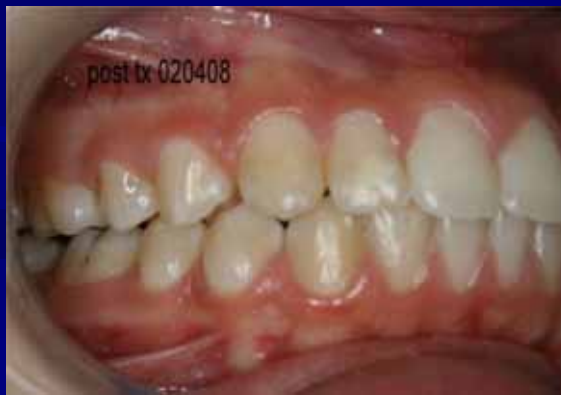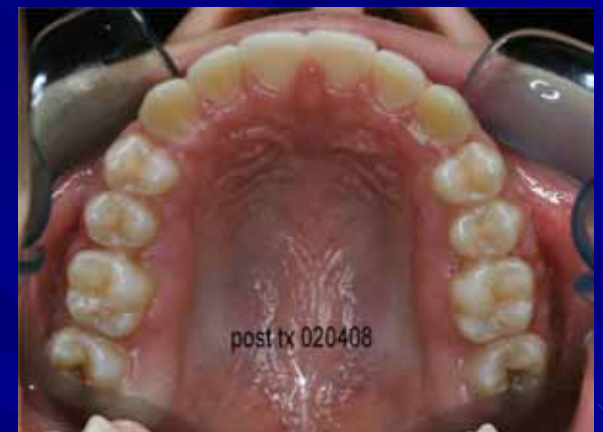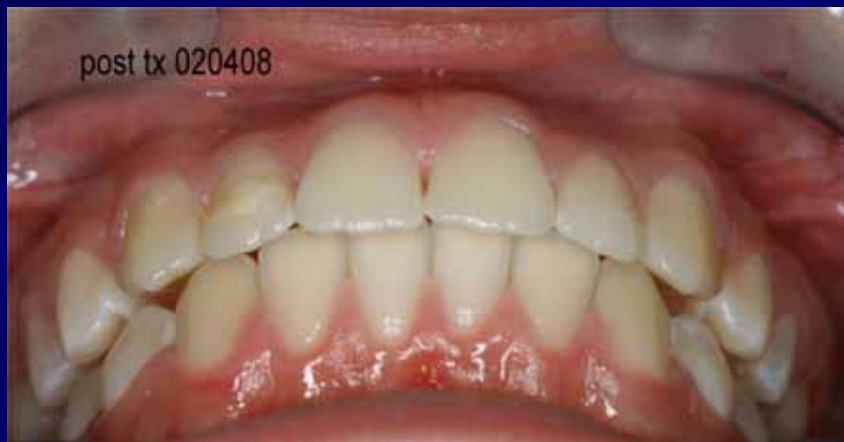Brittany: 15 months full bracket Tx



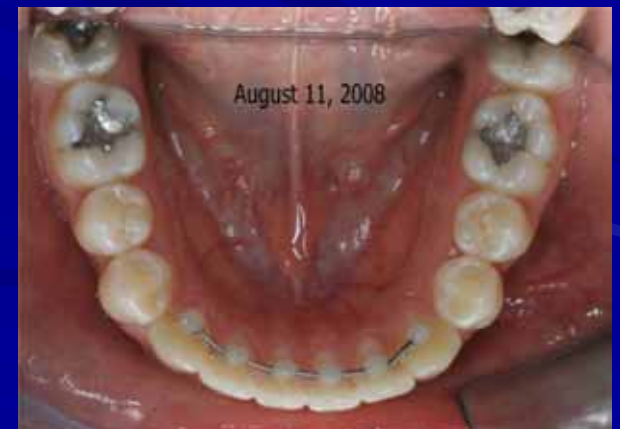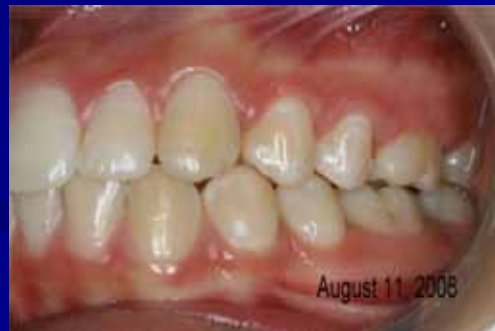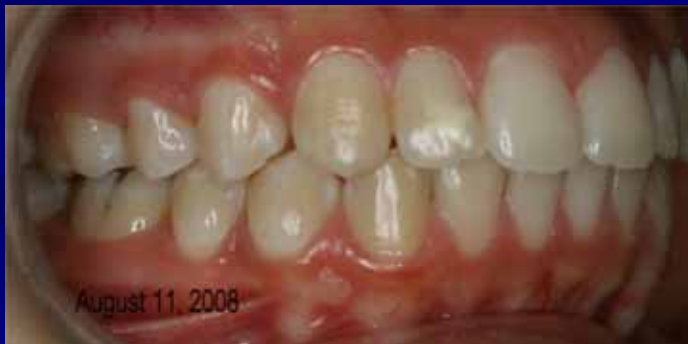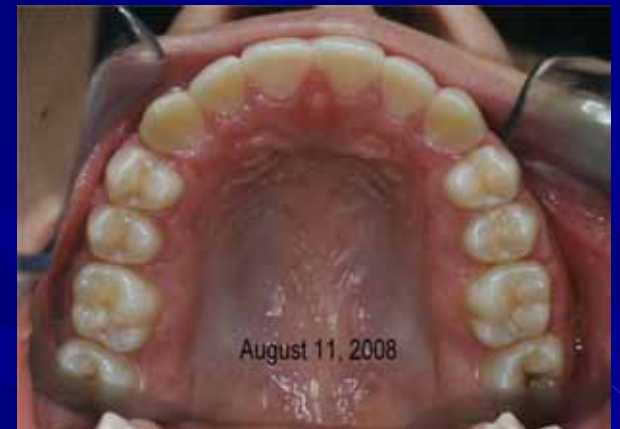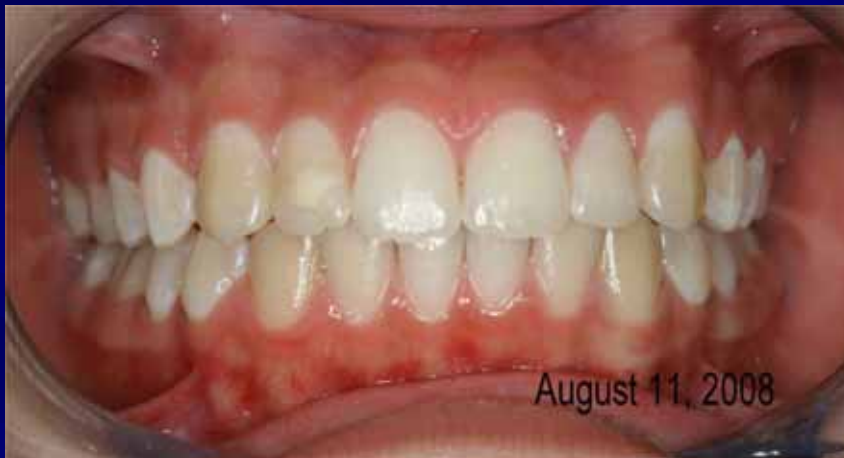Brittany: 19 months active Tx



Brittany: Post treatment

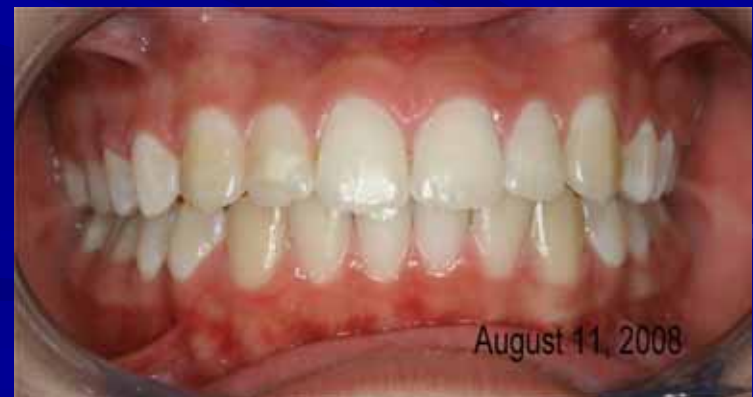

Brittany: 8 months retention



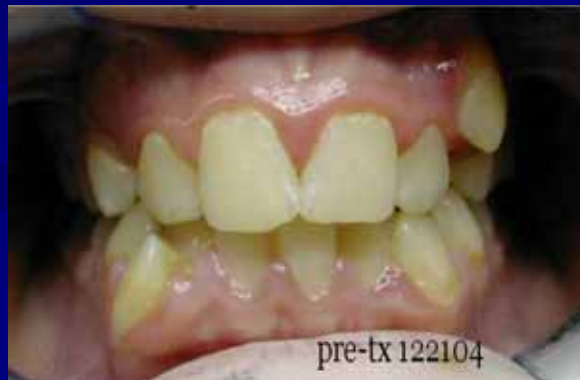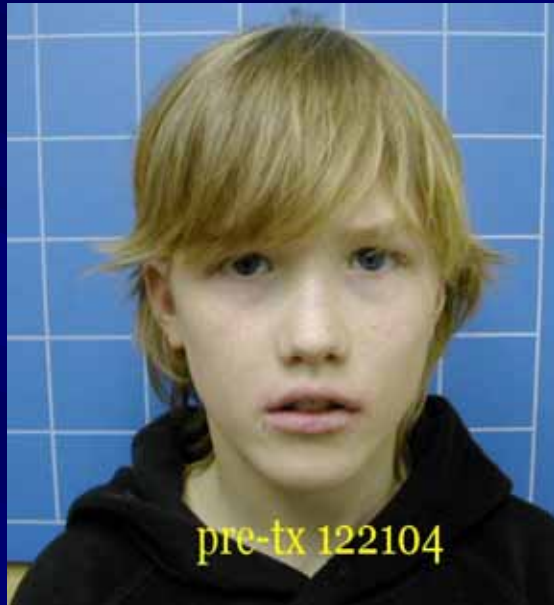Brittany

- Upper 3-way Sagittal 4 months
- Full brackets 15 months
- Upper Rick-a-nator/ tripod lower molars
- Removal of Rick-a-nator at 5 months
- De-bracket- upper QCM Hawley/ lower 3x3



Class II

Billy: 12 years of age

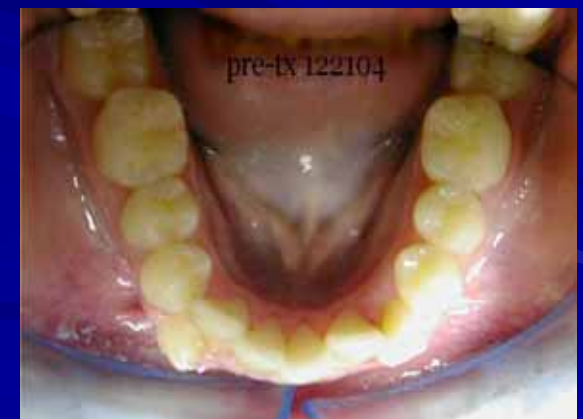
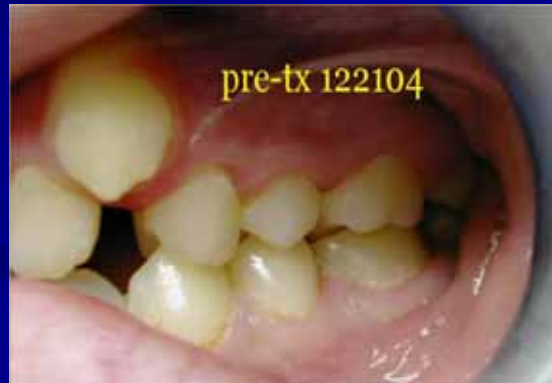
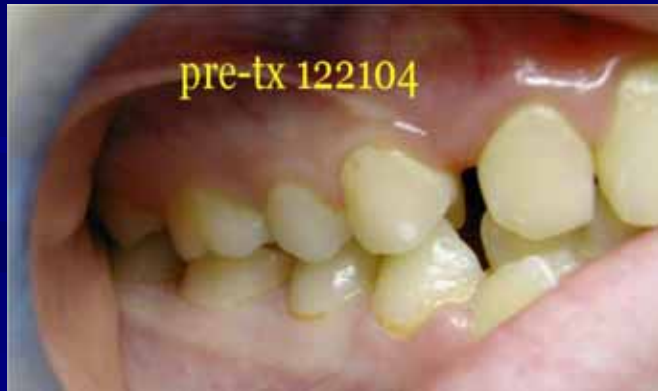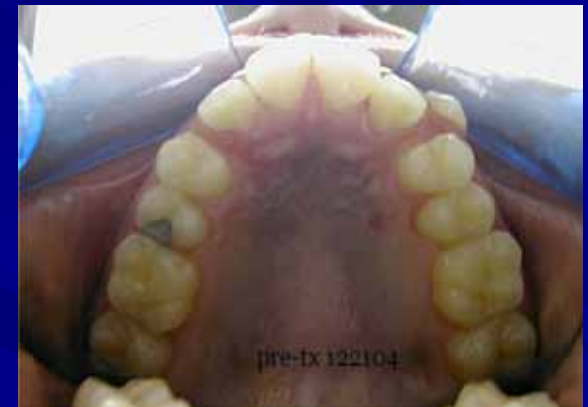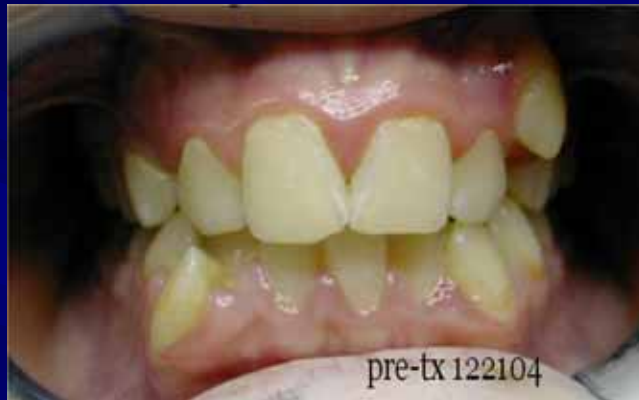- Class II ½ tooth
- Overjet 2 mm
- Overbite 20%
- Class I facial profile
- Constricted maxilla
- Doesn't smile
- Concern: Crowding

Class II

Billy: 12 years of age

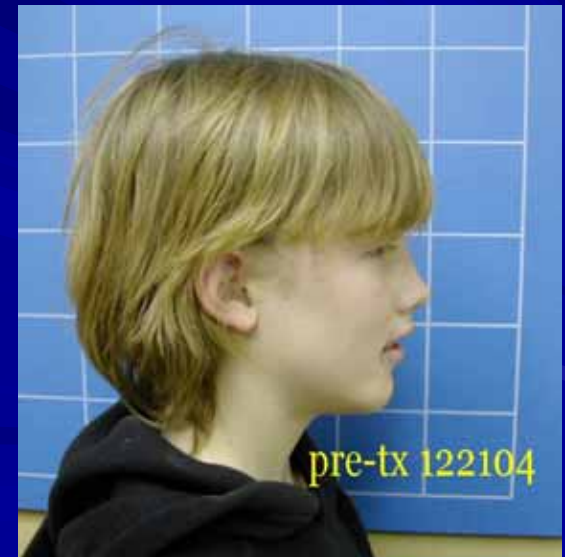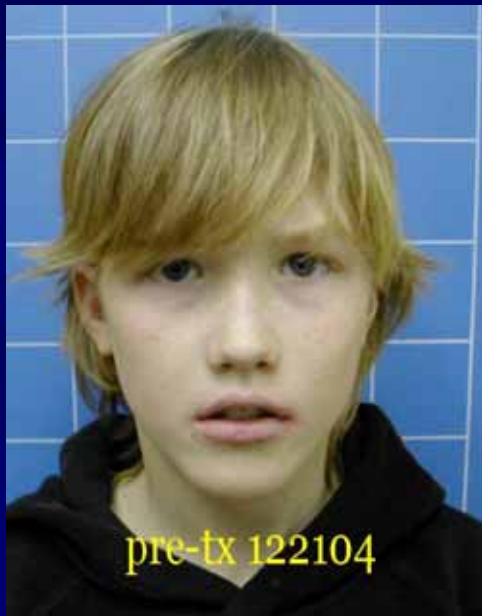Pre-treatment



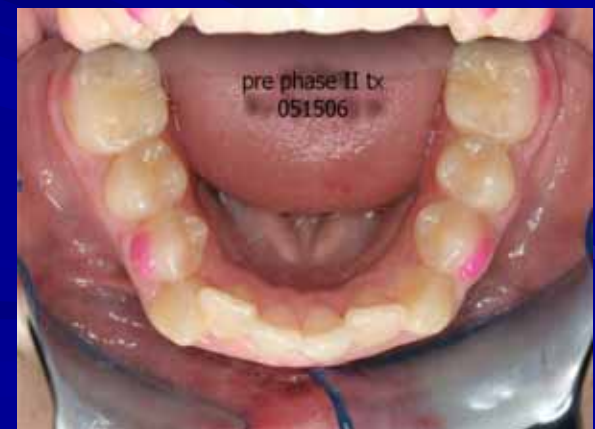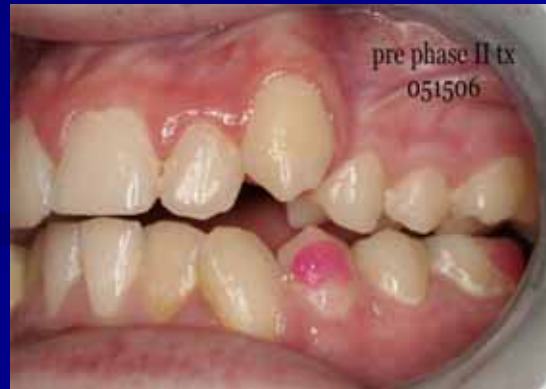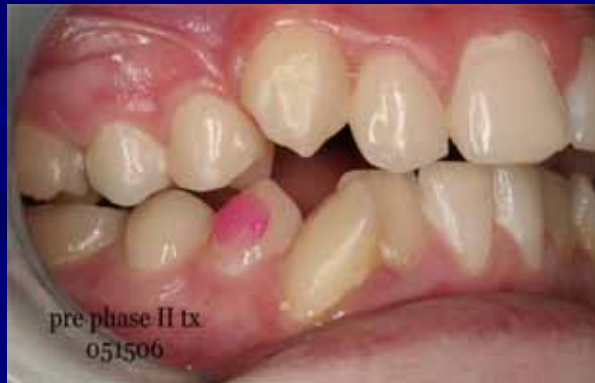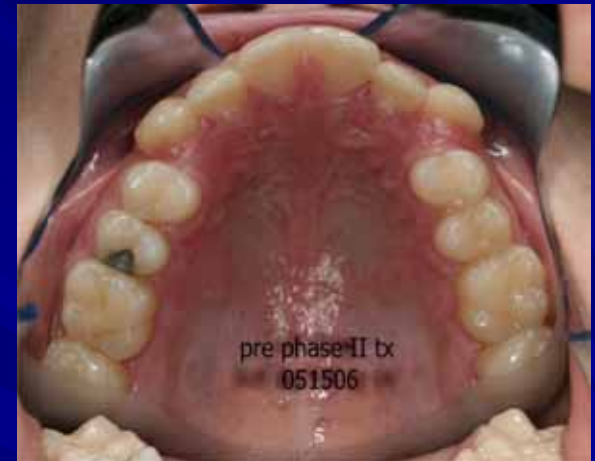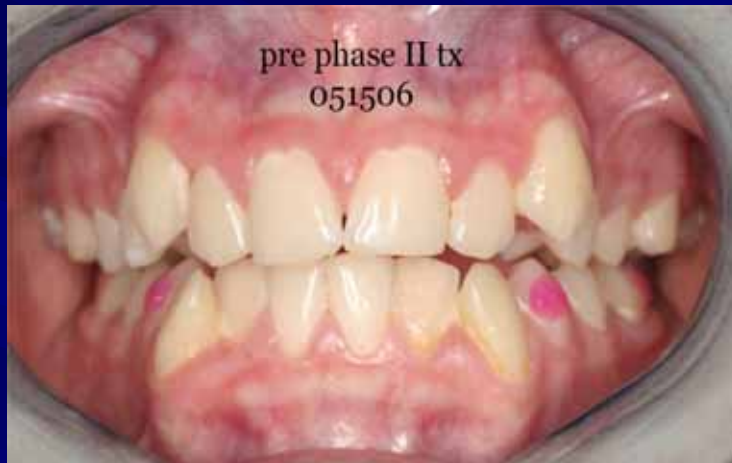Class II

Billy: 12 years of age

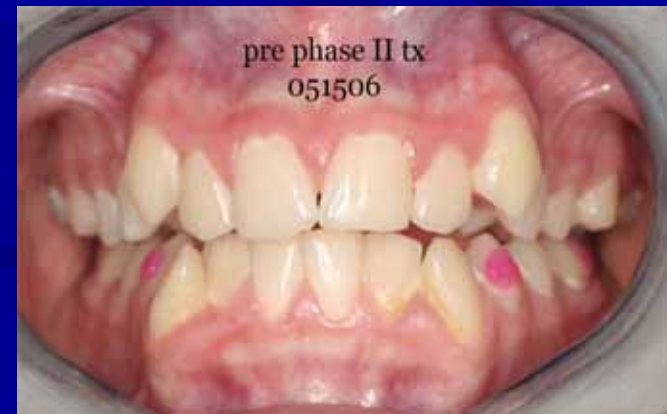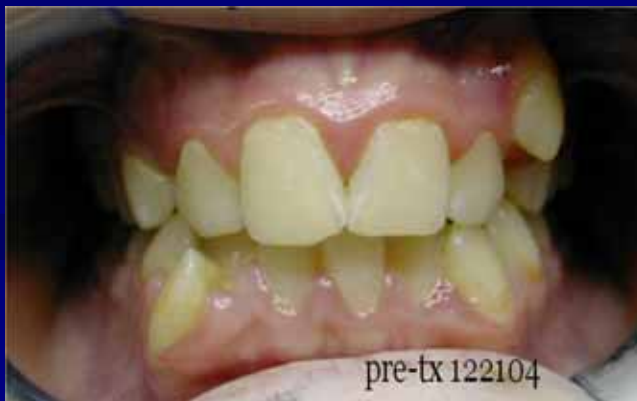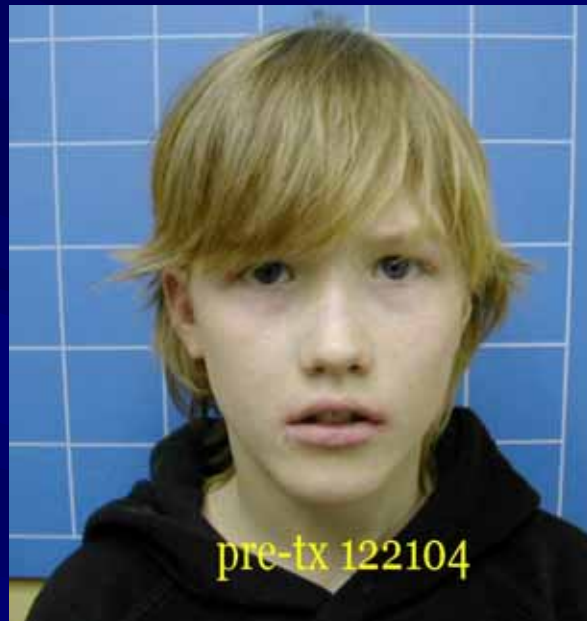Pre-treatment



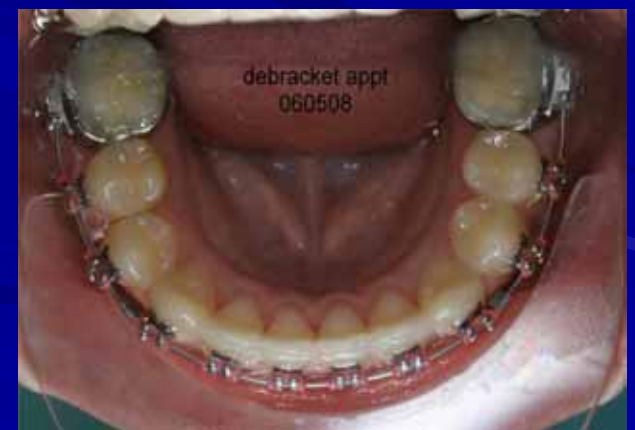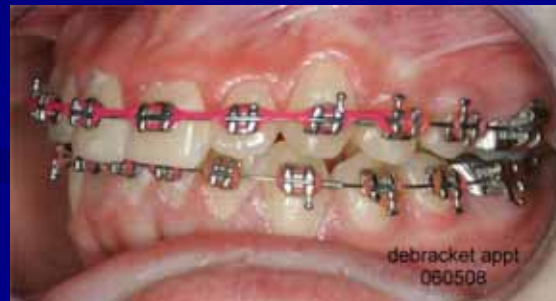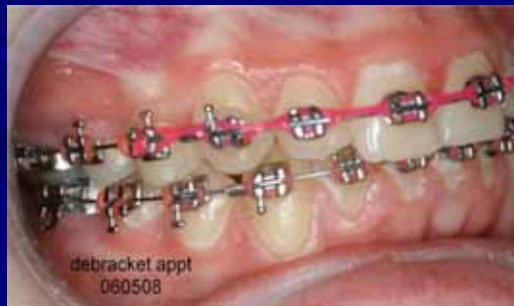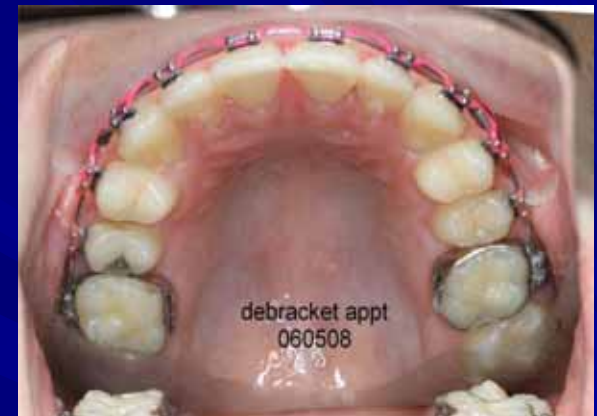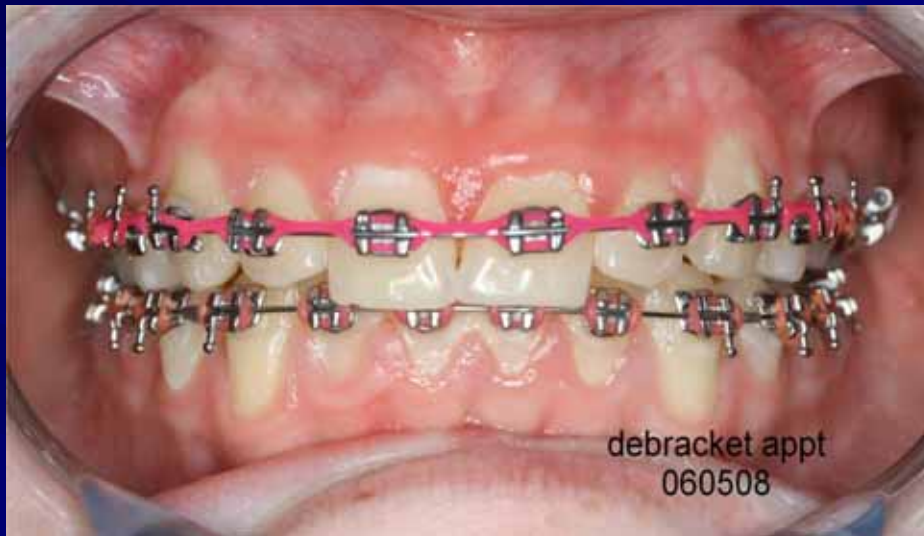Billy: Upper & lower Sagittals 15 months of active wear



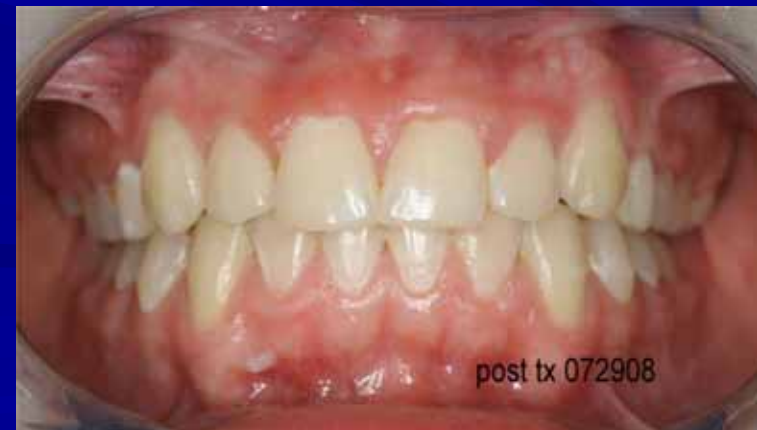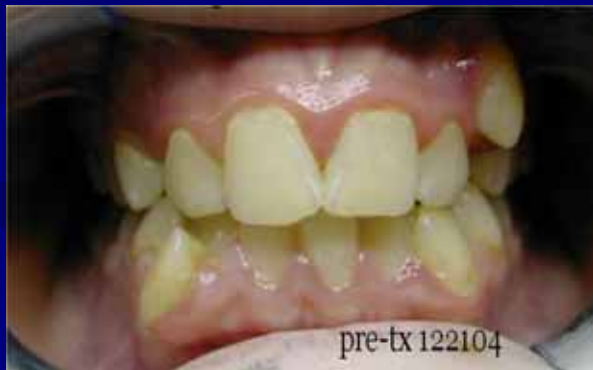Billy: Mid treatment



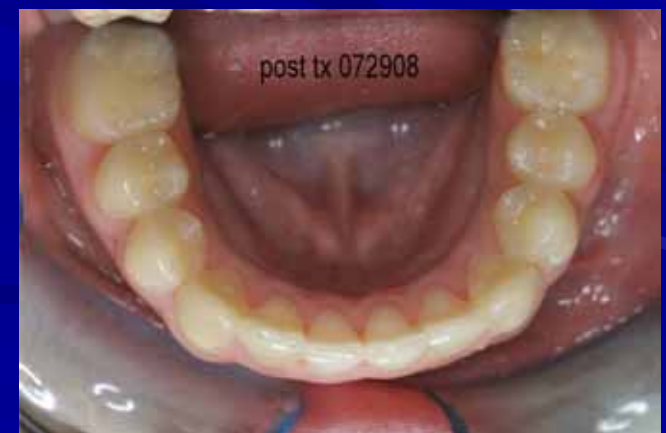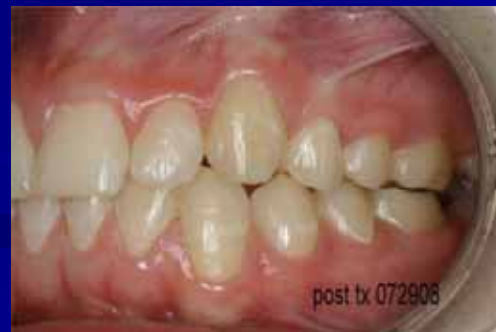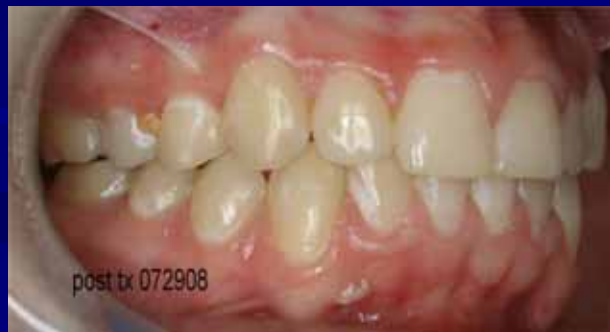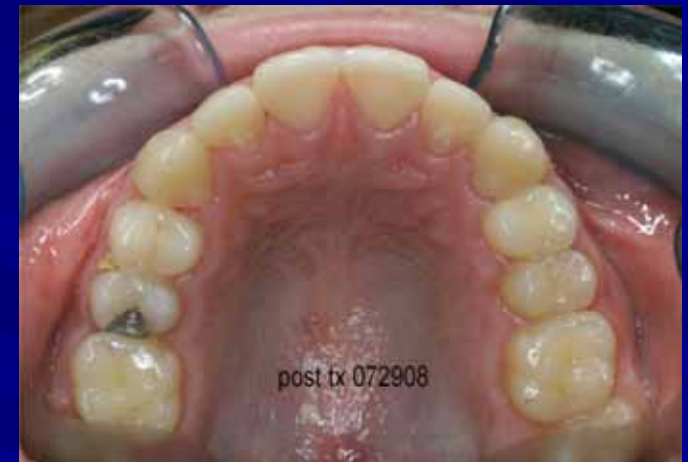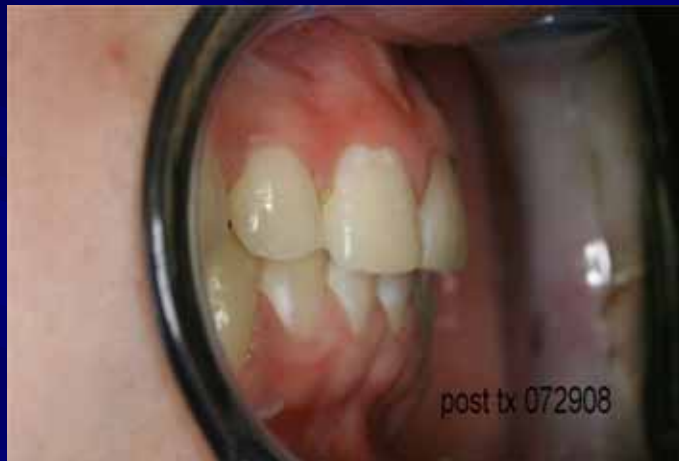Billy: 25 months full bracket Tx



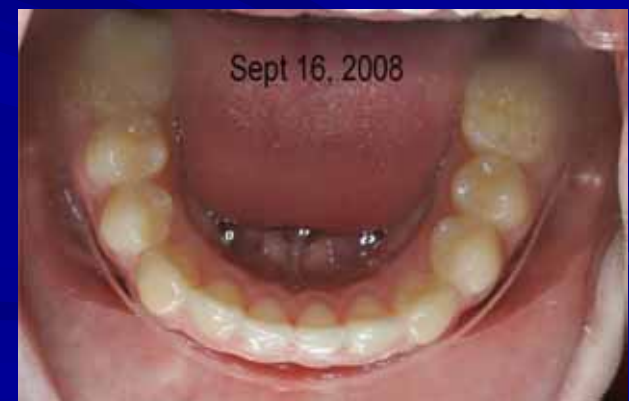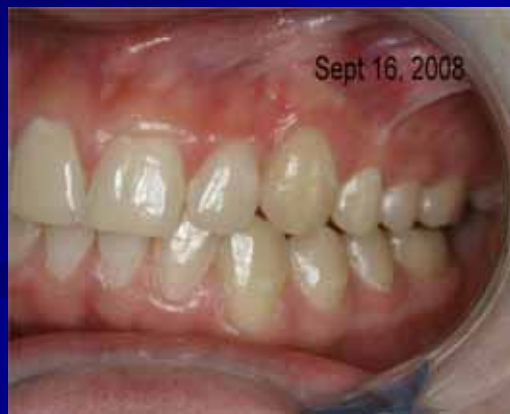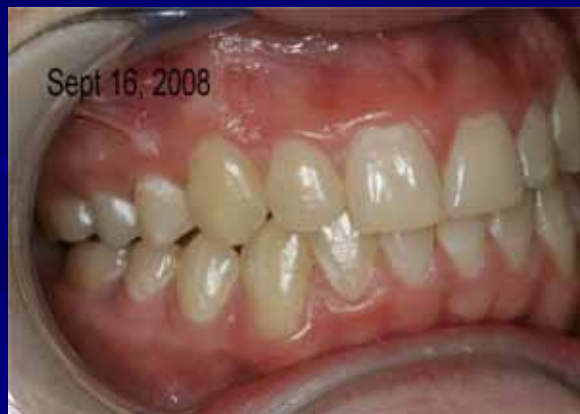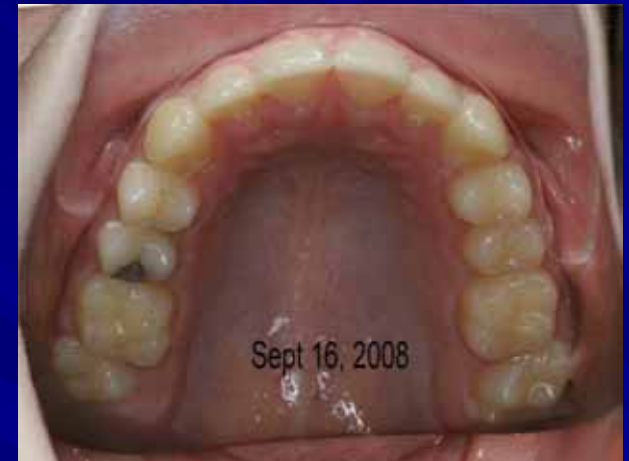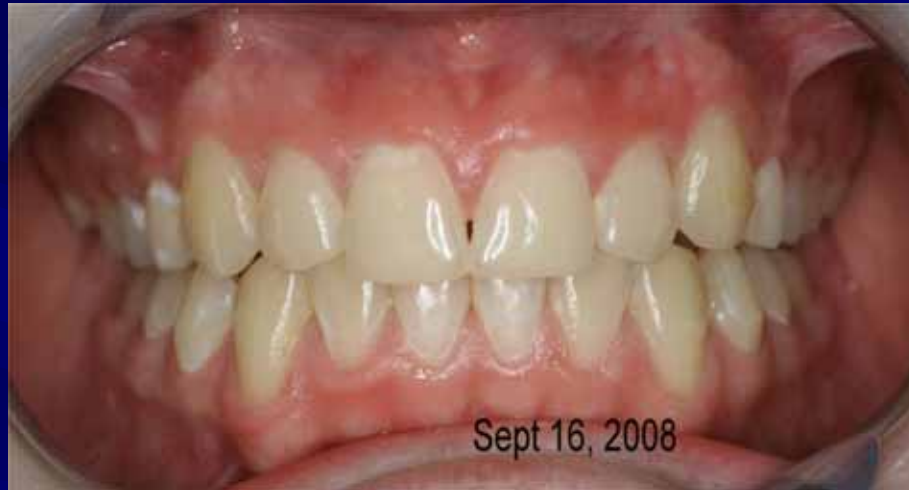Billy: 40 months of active Tx



Billy: Post Tx

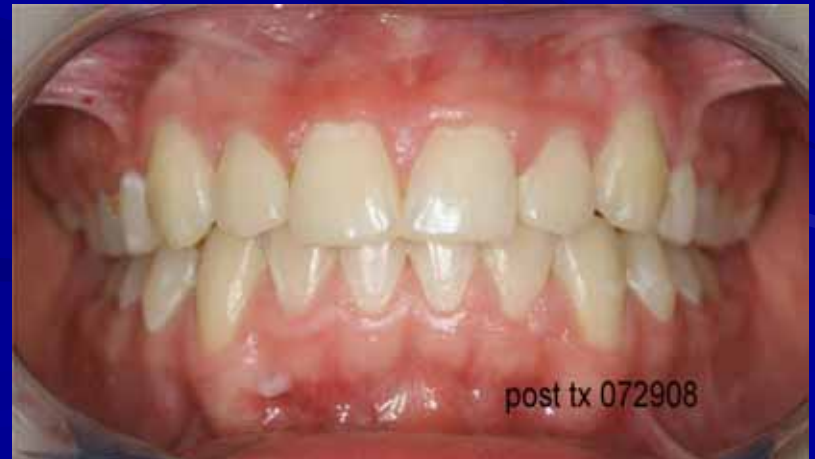

Billy: 3 months retention



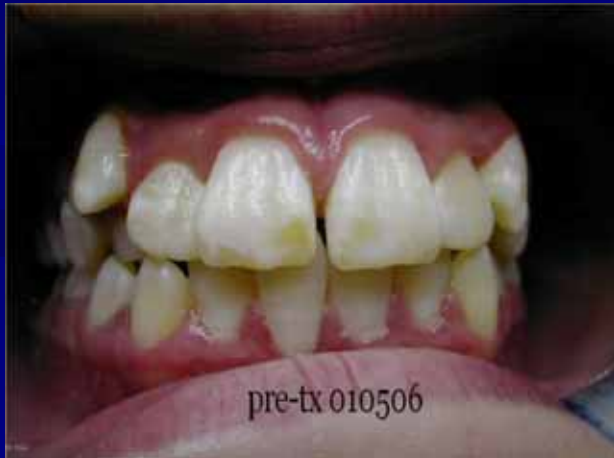Billy

- Extraction of lower second molars
- Upper 3-way Sagittal (did not see patient for 6 months)
- New upper/lower Sagittals 8 months
- Full brackets 25 months
- De-bracket positioner for retention
- Billy is now 'SMILING'



Class II

Nikki: 12 years of age

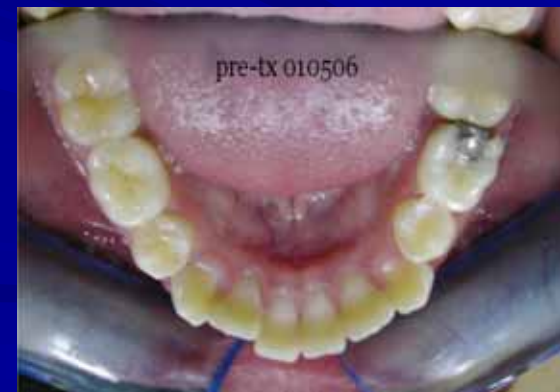
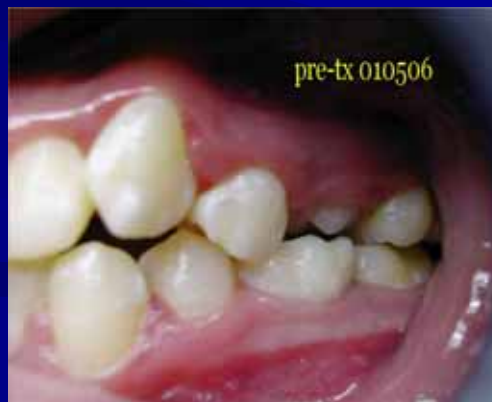
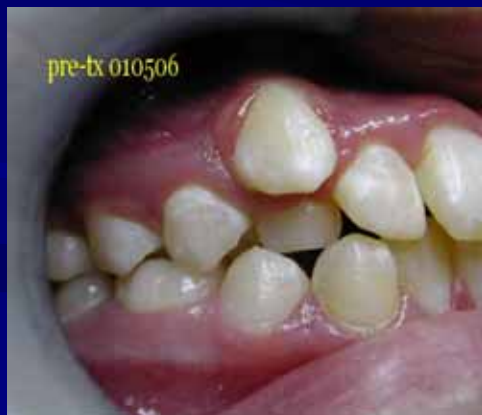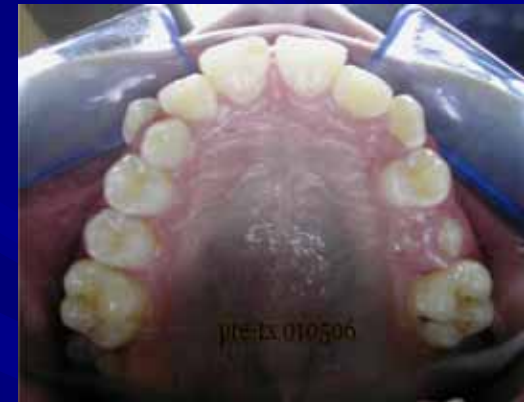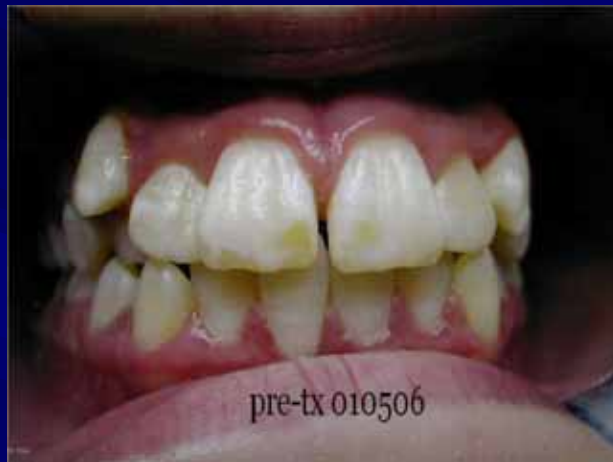- Class II ½ tooth
- Overjet 1 mm
- Overbite 10%
- Class I facial profile
- Concern:
Upper cuspids

Class II

Nikki: 12 years of age

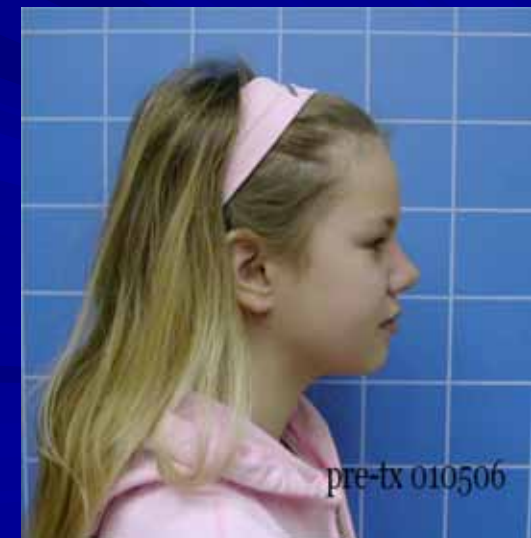Pre-treatment



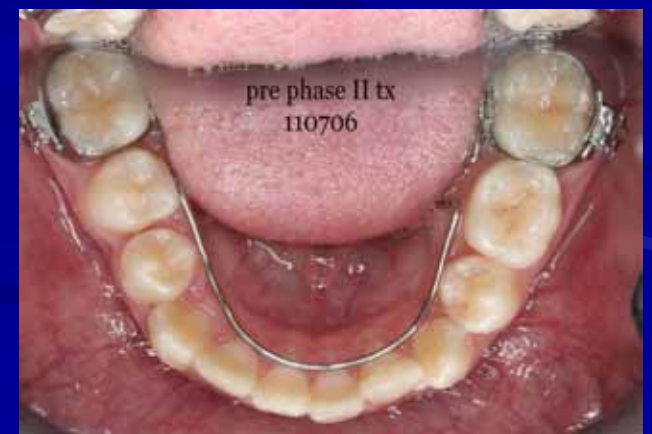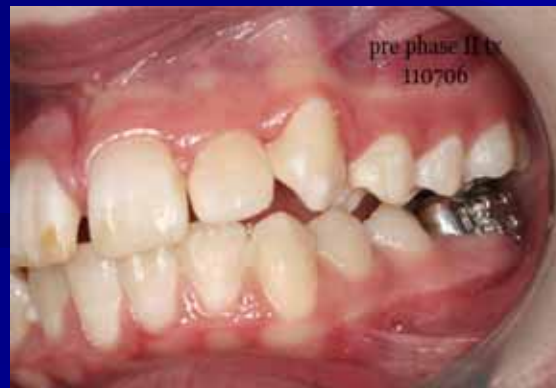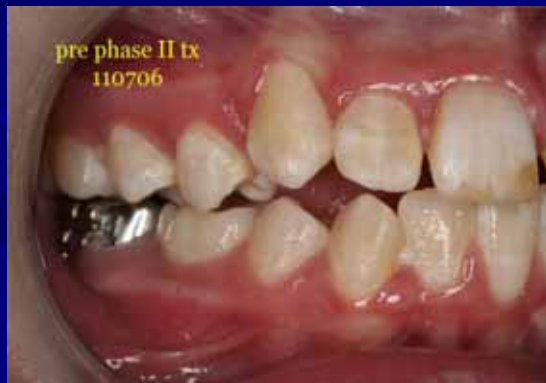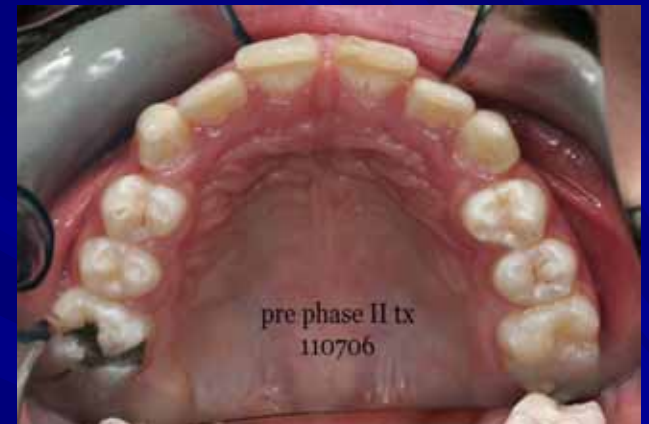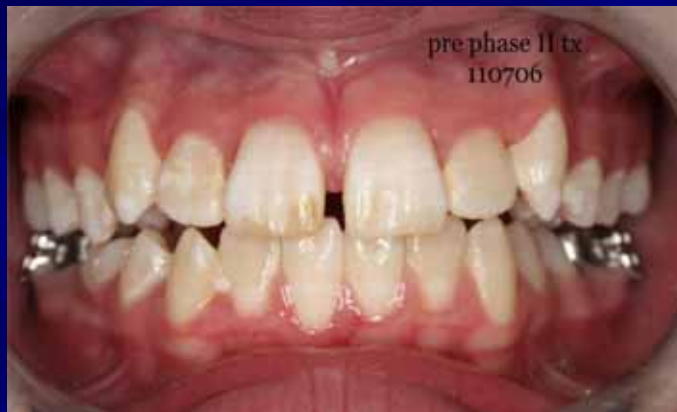Class II

Nikki: 12 years of age

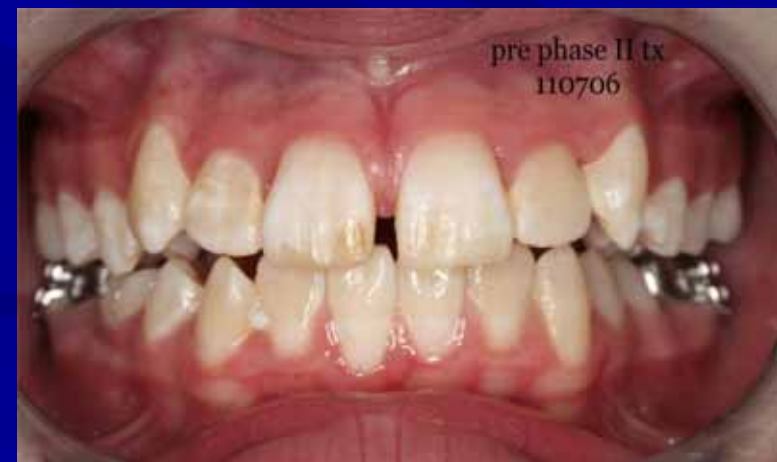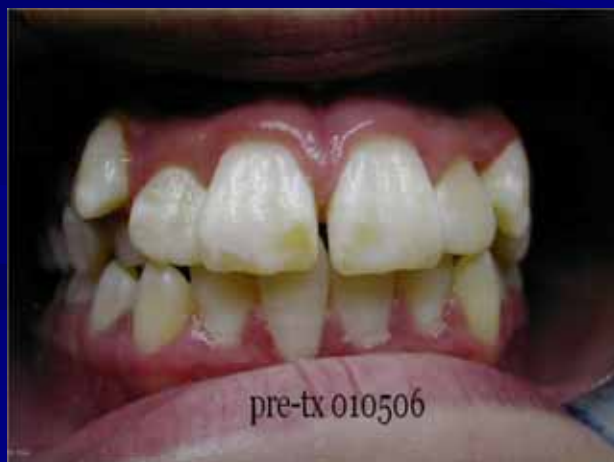Pre-treatment



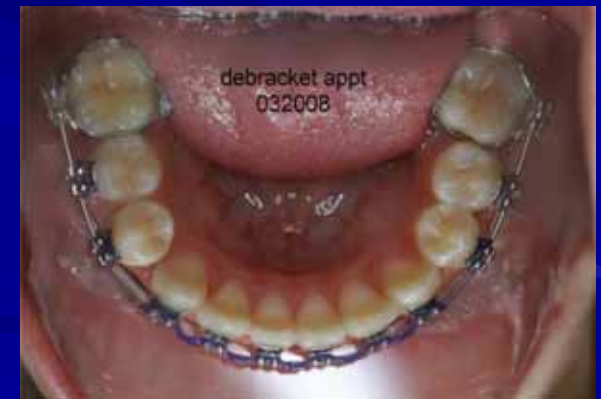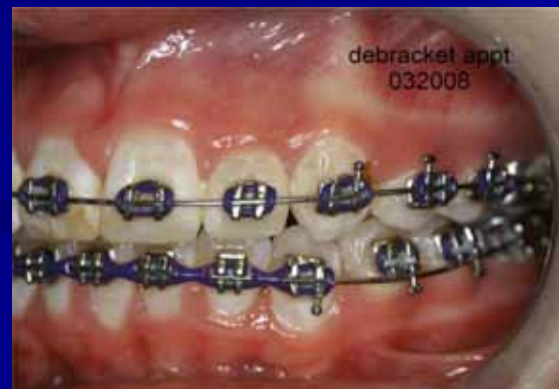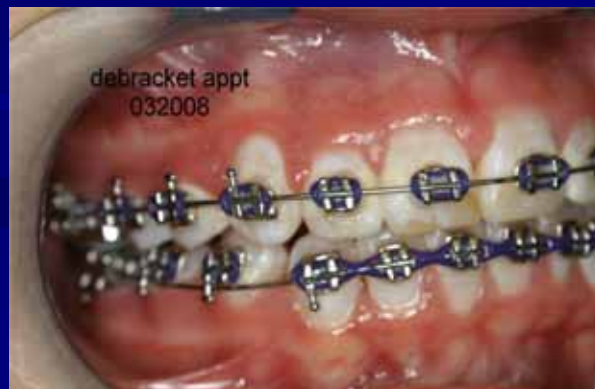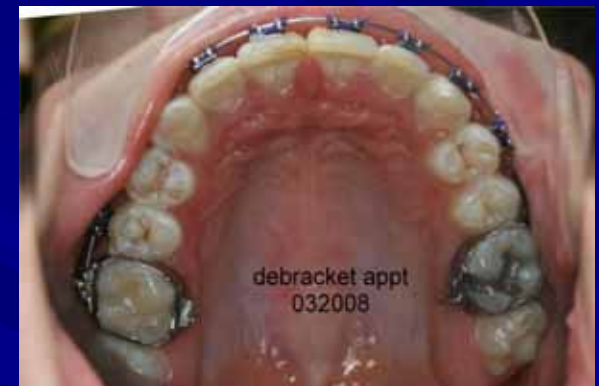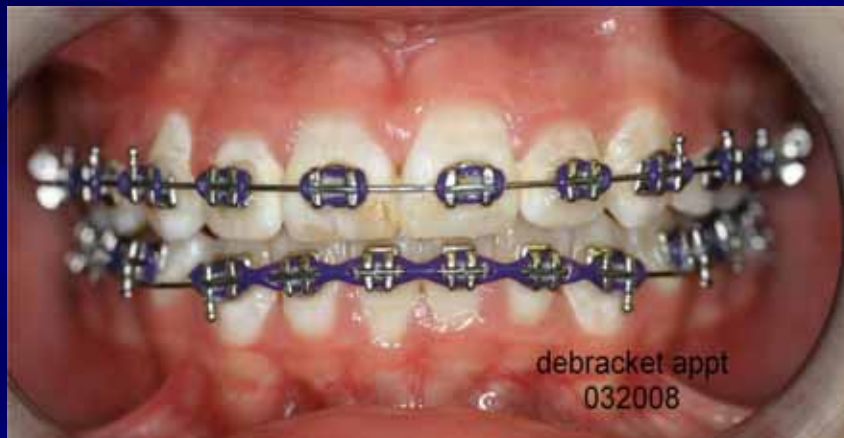Nikki: upper Sagittal/lower holding arch 6 months active wear



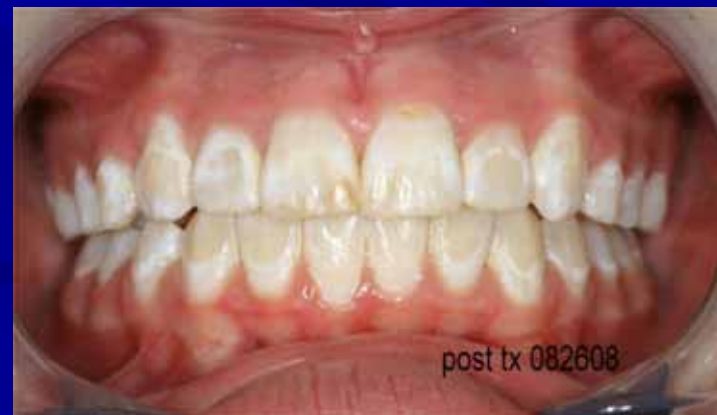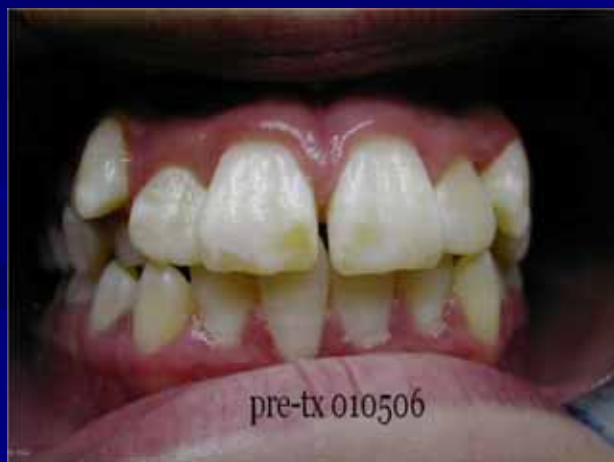Nikki: Mid treatment



Nikki: 16 months full bracket Tx

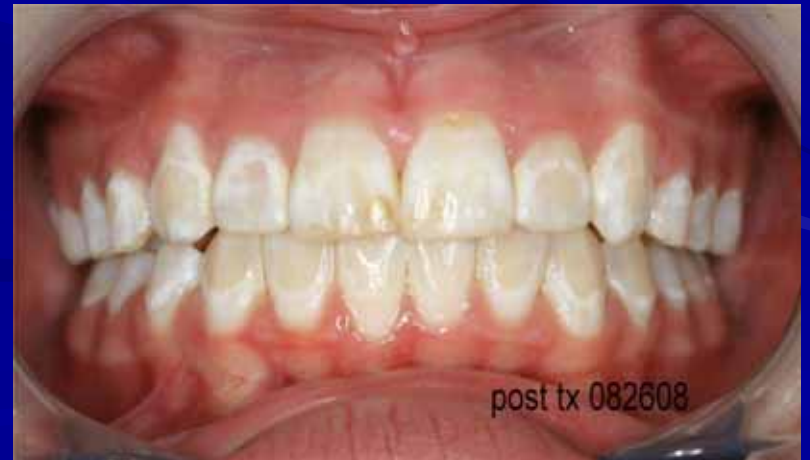

Nikki: 24 months active Tx



Nikki

- Extraction of lower second molars
- Upper 3-way Sagittal/ lower holding arch 6 months
- Mx over expanded allowed to relapse 1 month
- Full brackets with TPA/RLHA 16 months
- De-bracket
- Positioner for retention

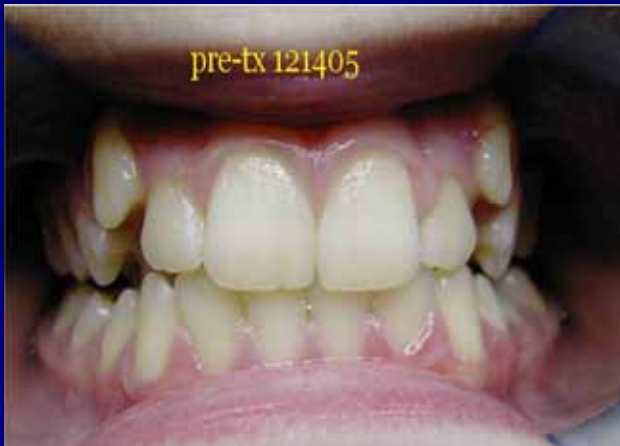

Class II

Alysa: 11 years of age



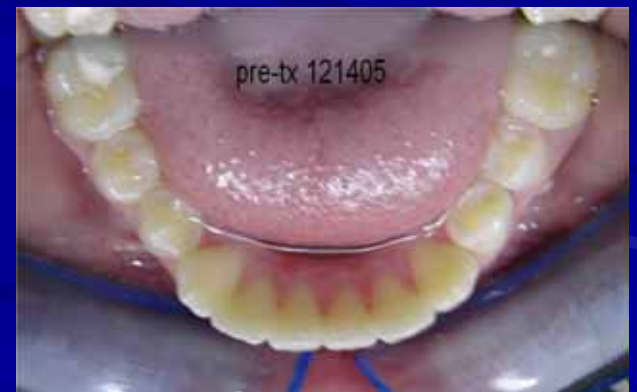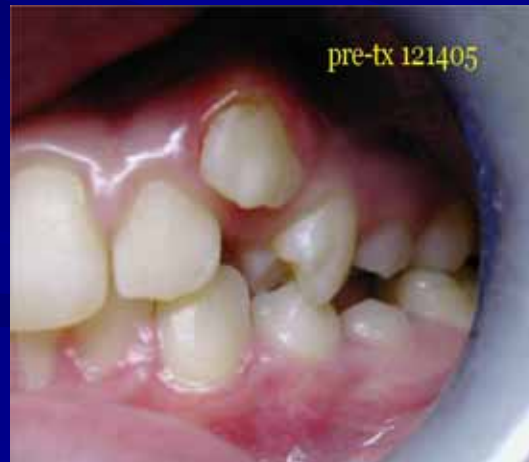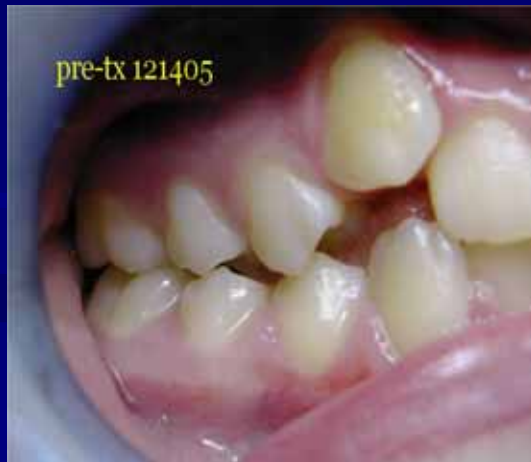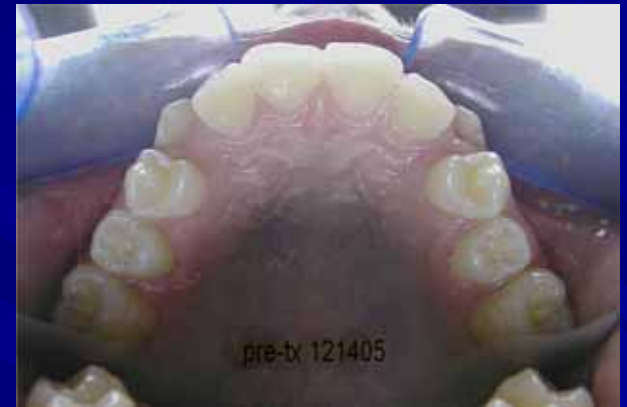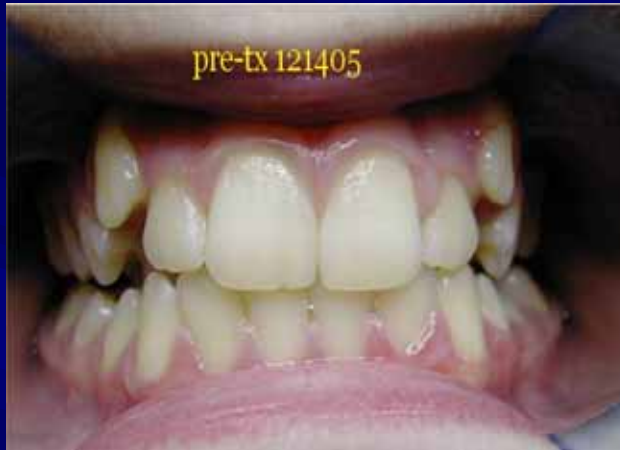- Class II ½ tooth
- Overjet 2 mm
- Overbite 50%
- Class II facial profile



Class II

Alysa: 11 years of age

Pre-treatment



Class II

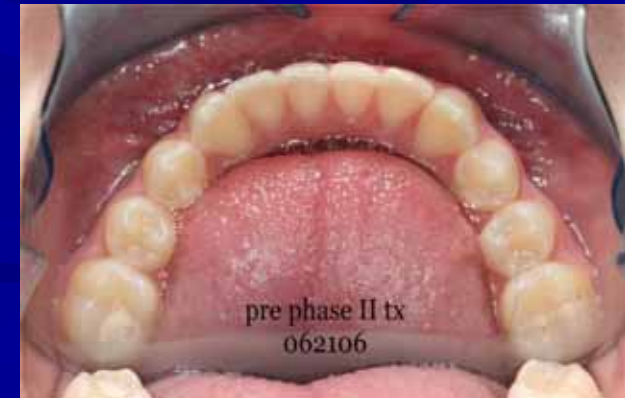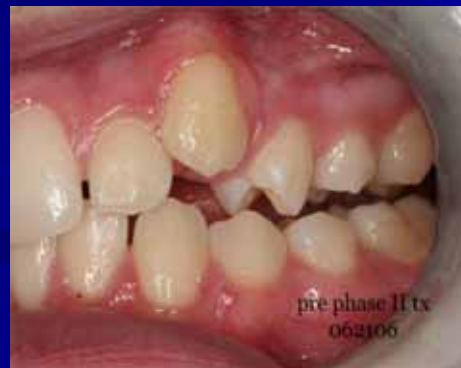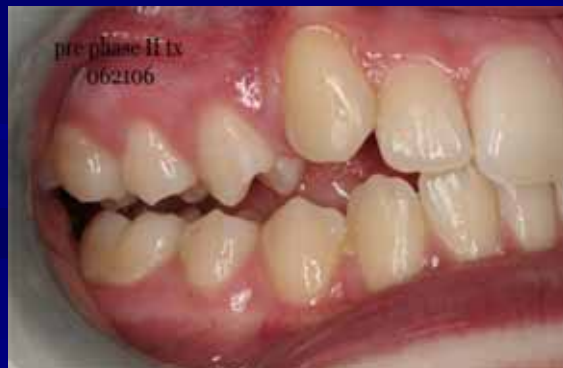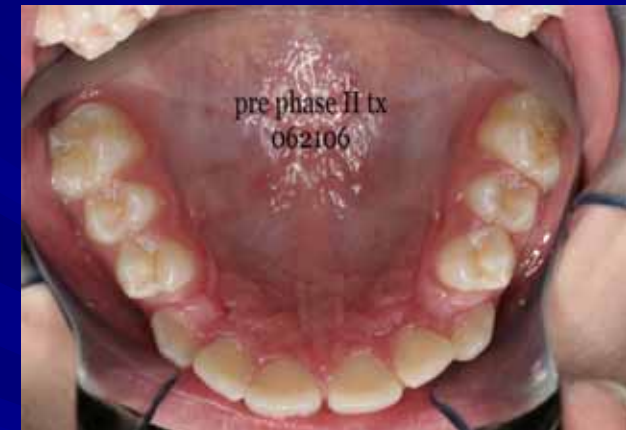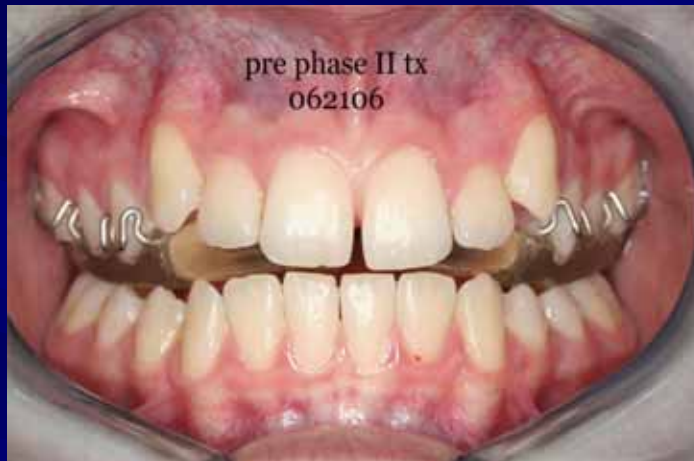Alysa: 11 years of age

Pre-treatment

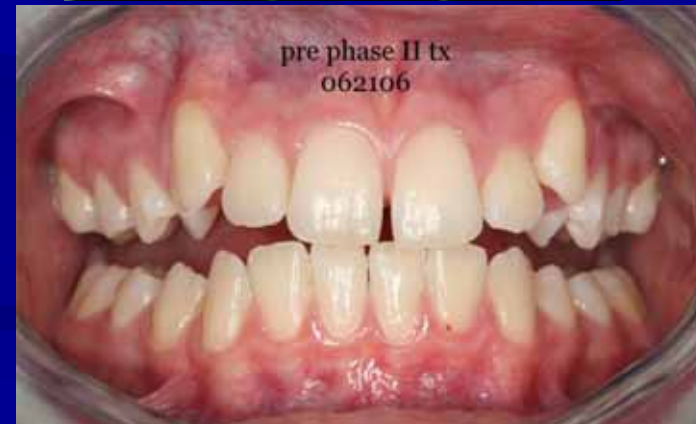
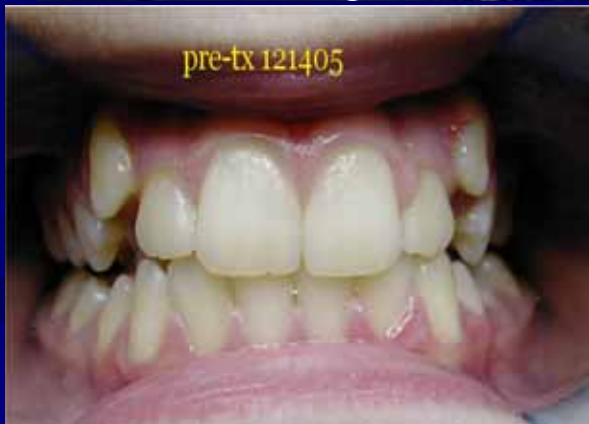
Alysa: Upper & lower Sagittals

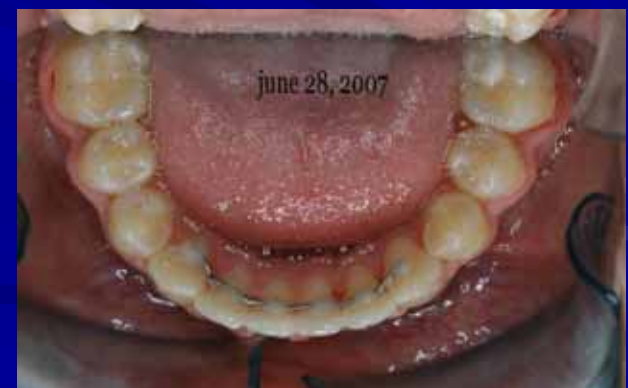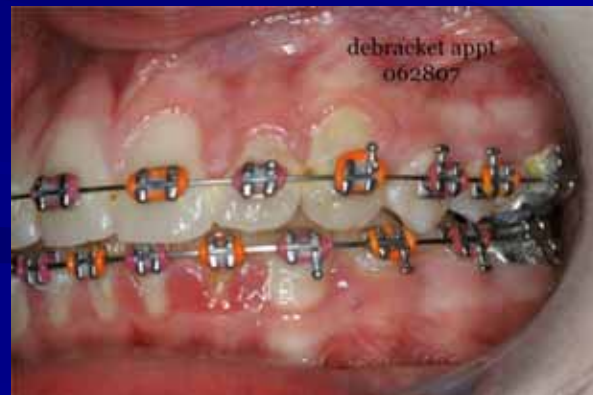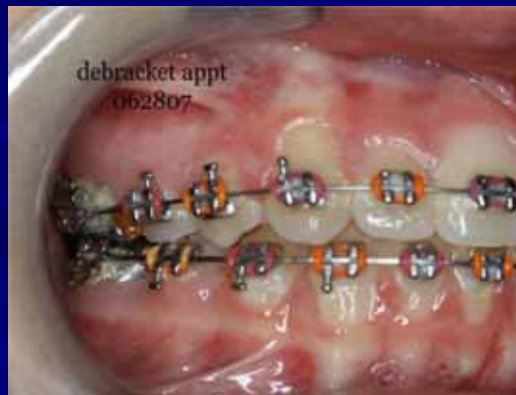
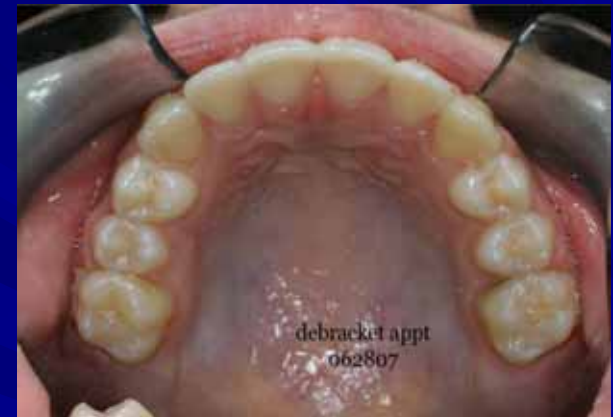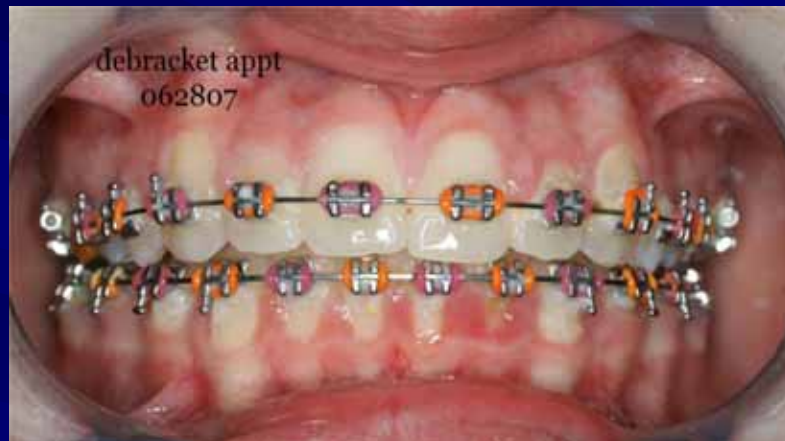4 months active wear



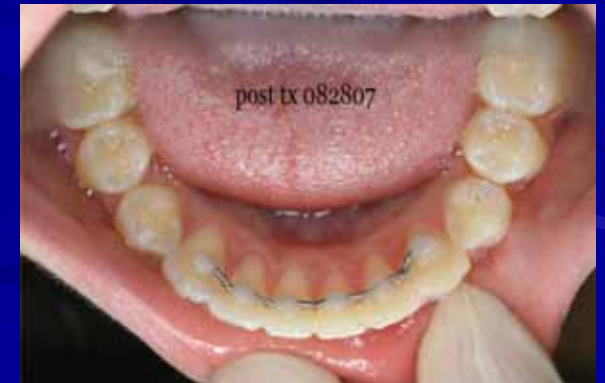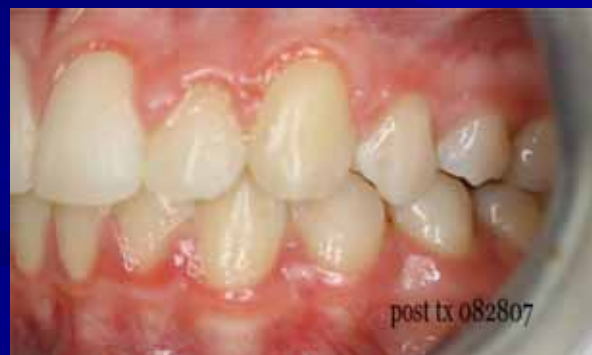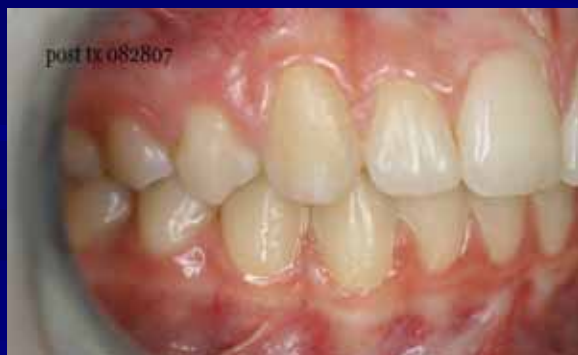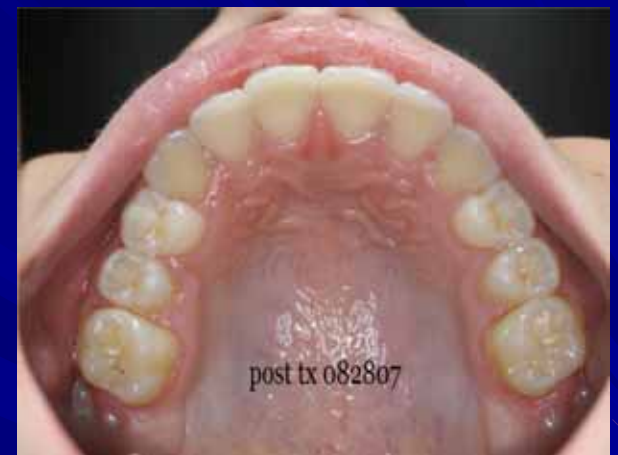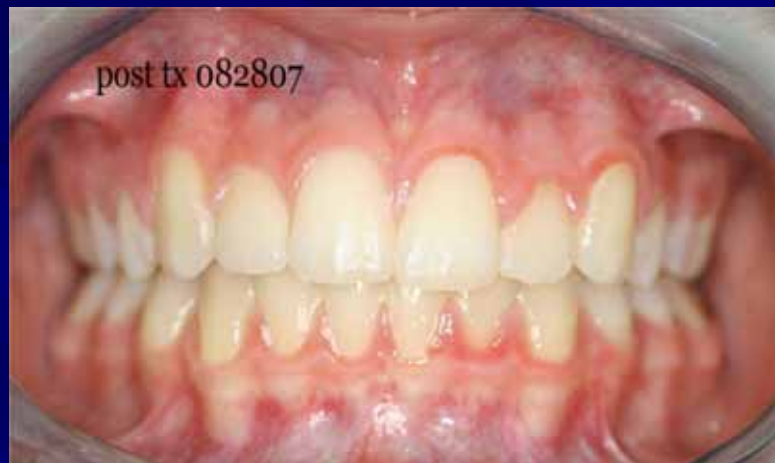Alysa: Pre & Mid treatment



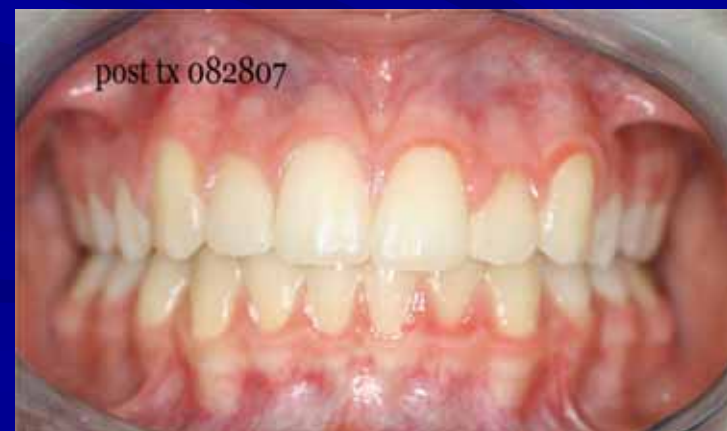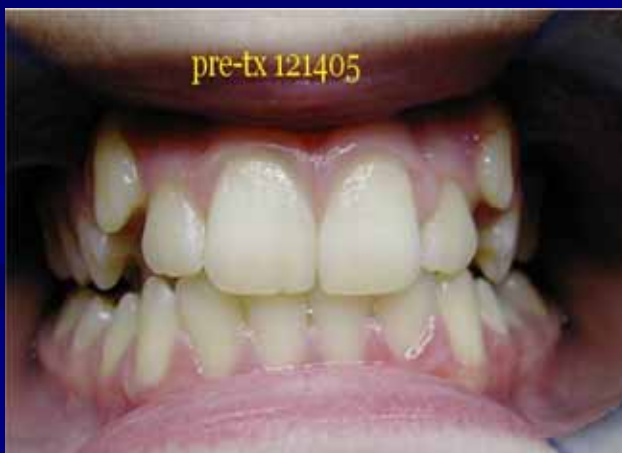Alysa: 12 months full bracket Tx



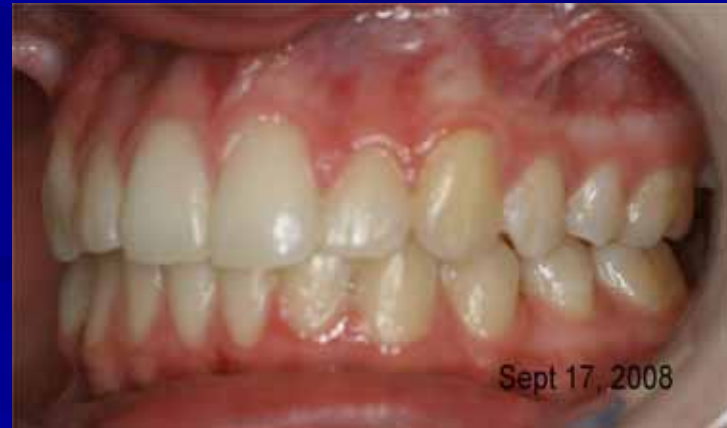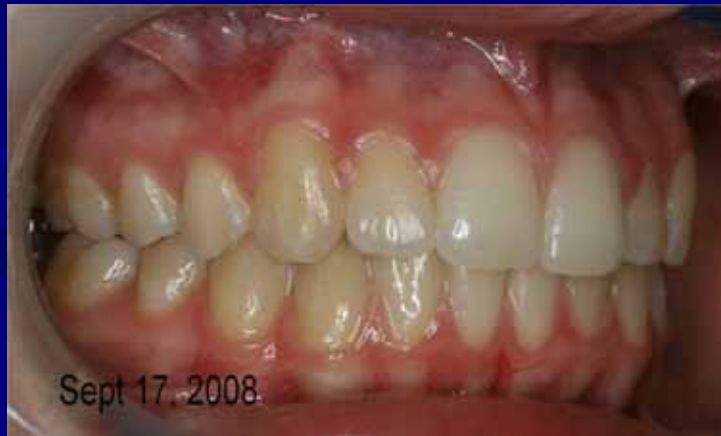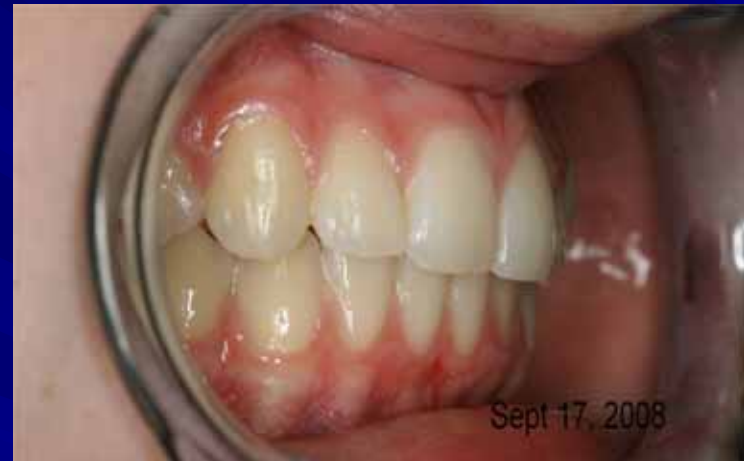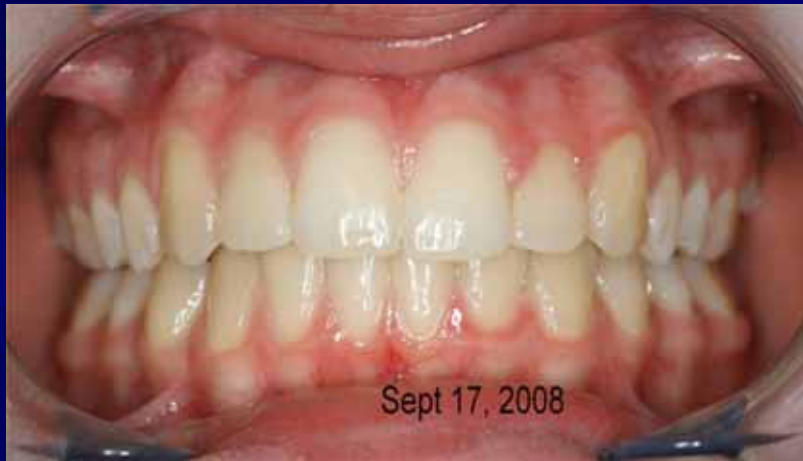Alysa: Post treatment



Alysa: 16 months of active Tx

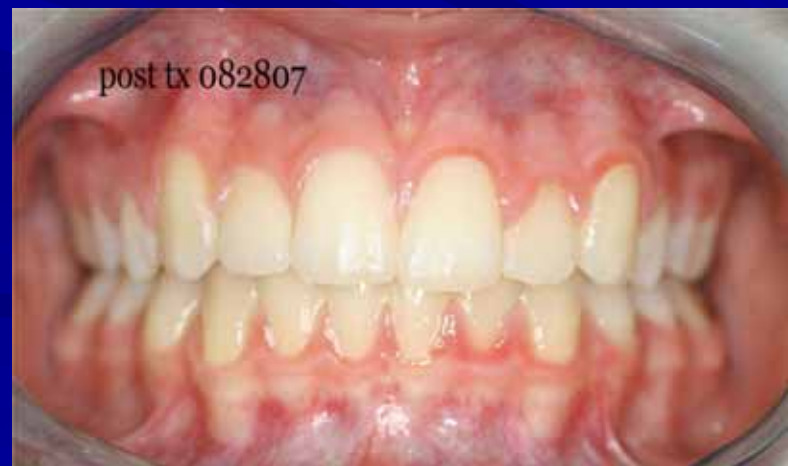

Alysa: 15 months retention



Alysa

- Extraction of lower second molars
- Upper & lower Sagittals 4 months
- Full brackets
- De-bracket
- Upper QCM Hawley - lower 3x3

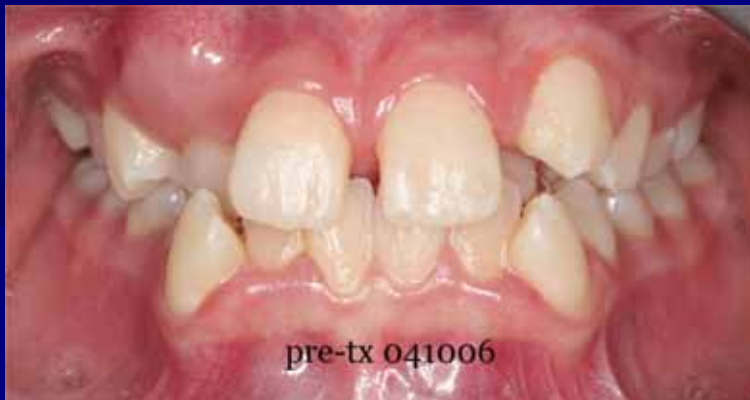

Class II

Karli: 11 years of age



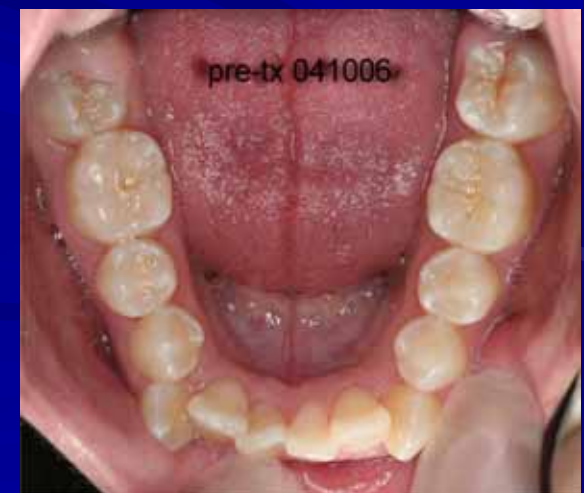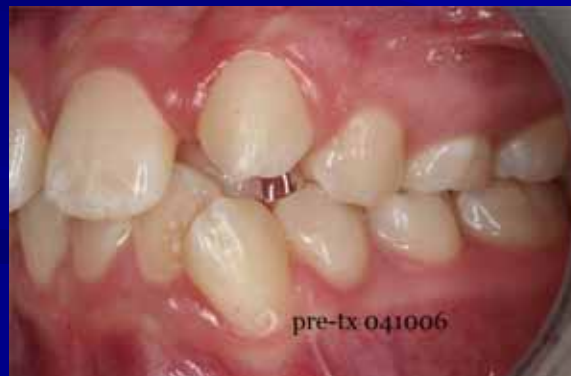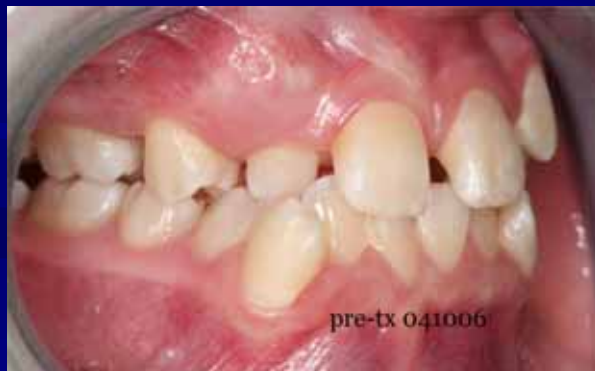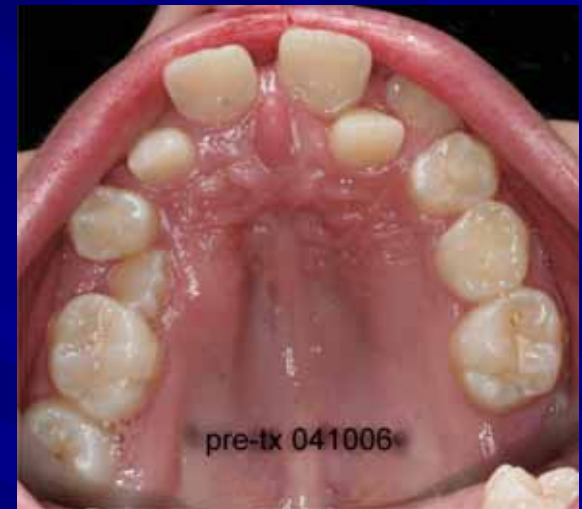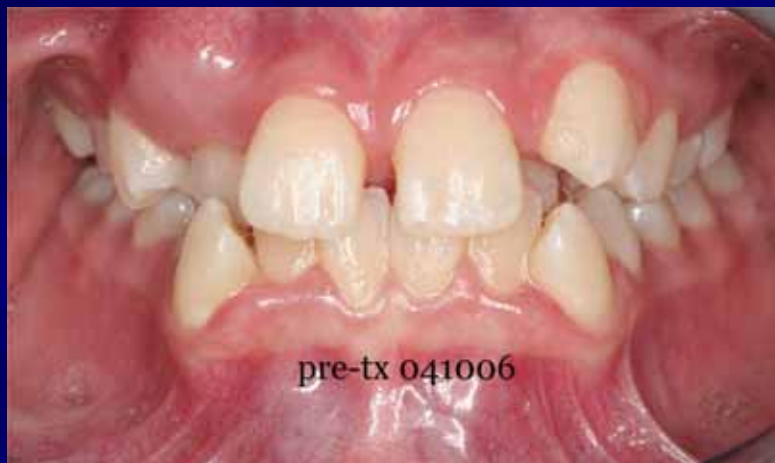- Class II ½ tooth
- Overjet 2mm
- Overbite 40%
- Constricted mx
- Concern: Crowding



Class II

Karli: 11 years of age

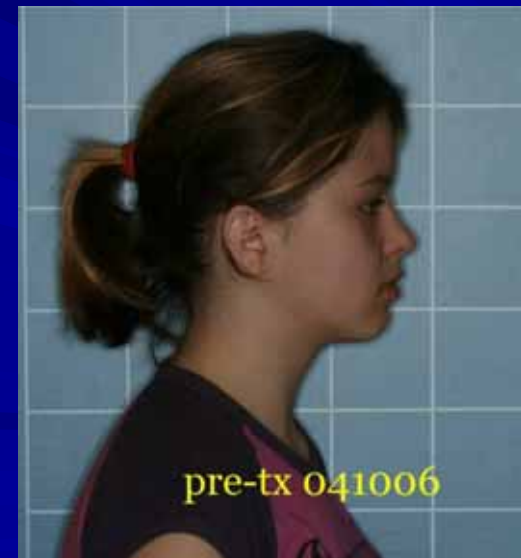Pre-treatment



Class II

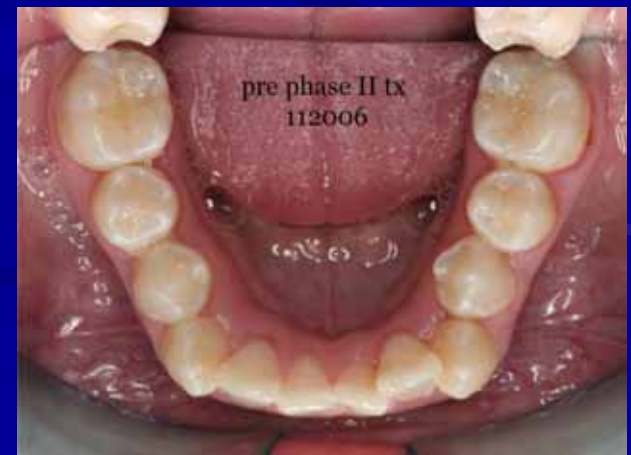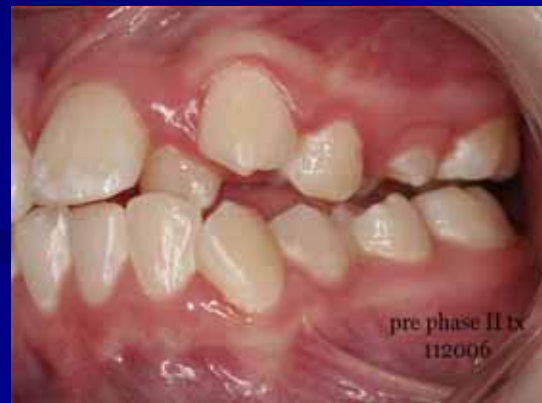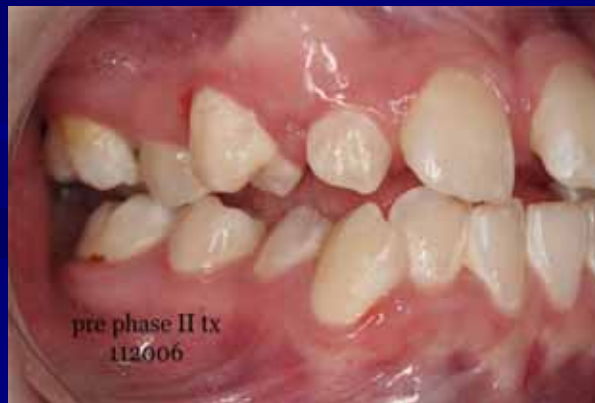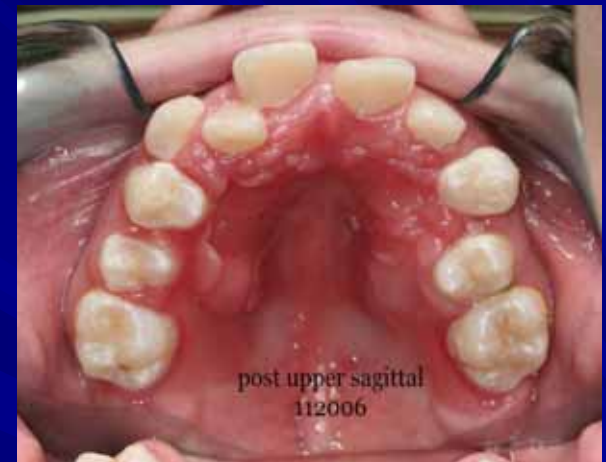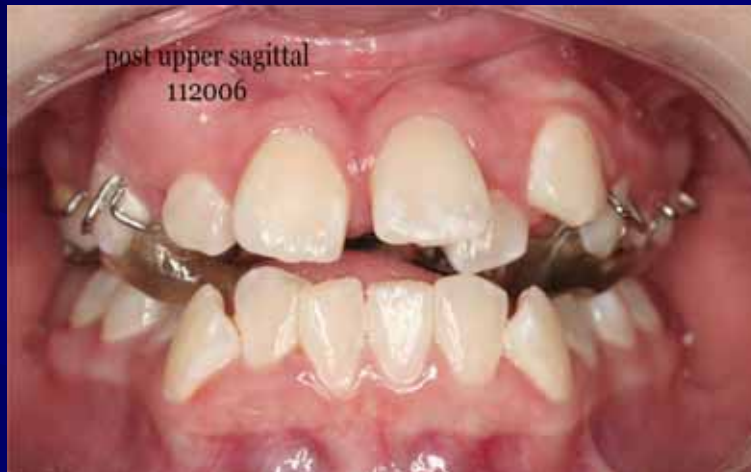Karli: 11 years of age

Pre-treatment

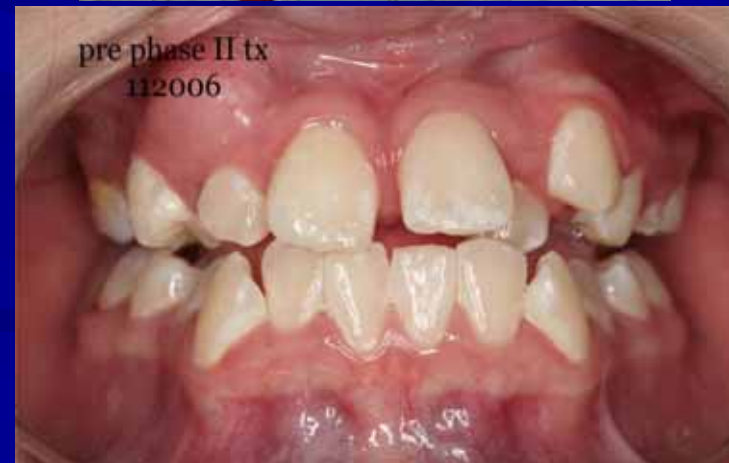
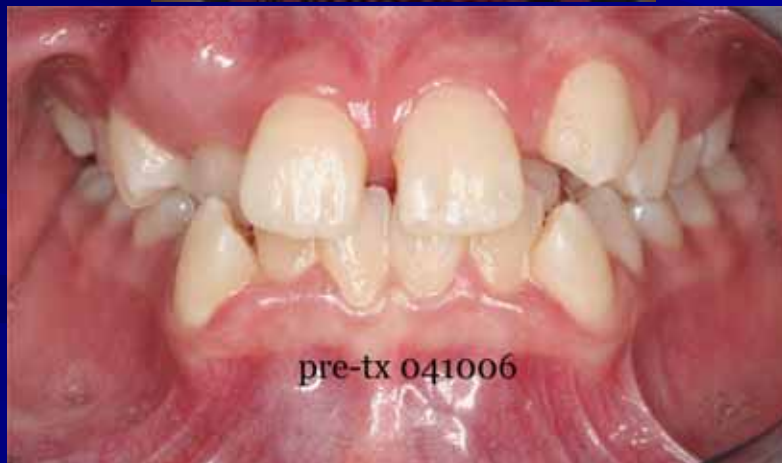
Karli: upper & lower Sagittals

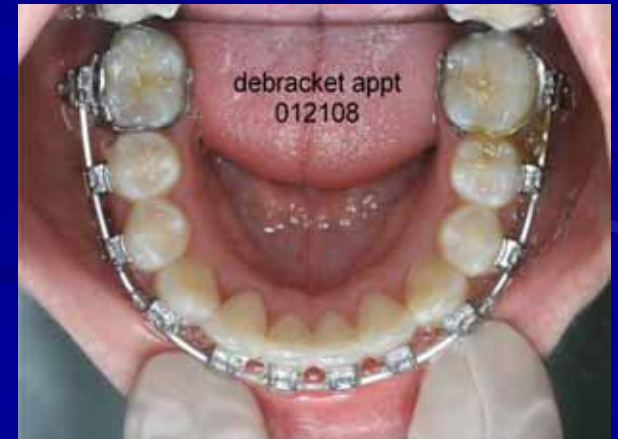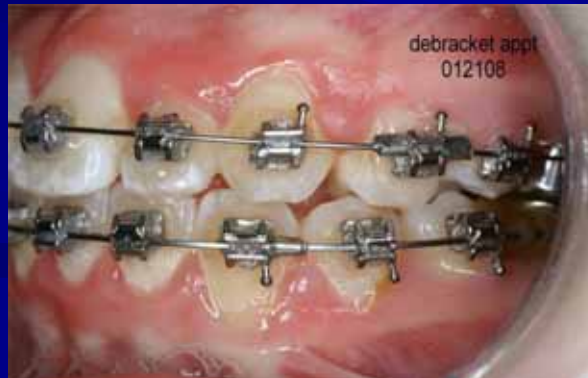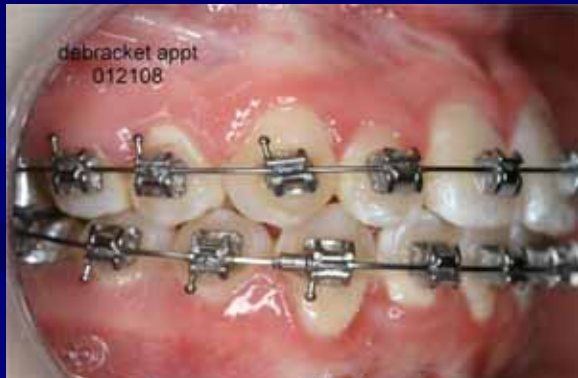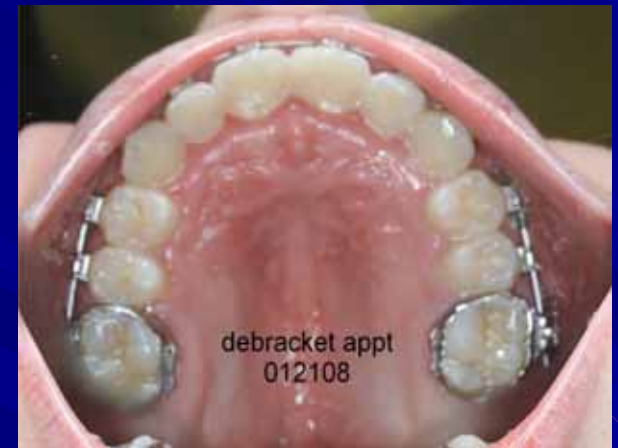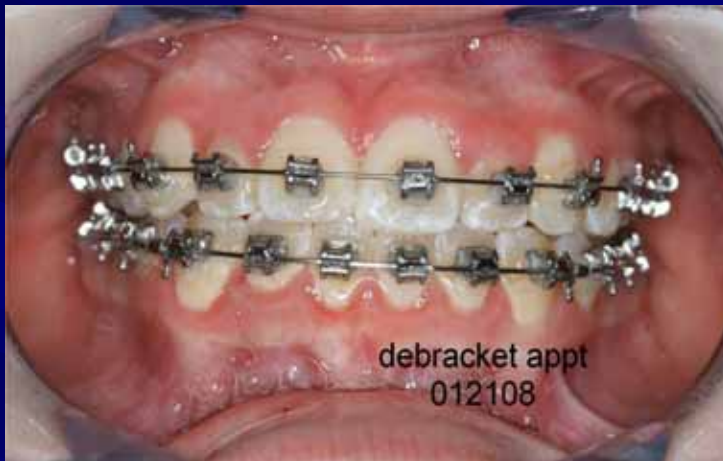6 months active wear



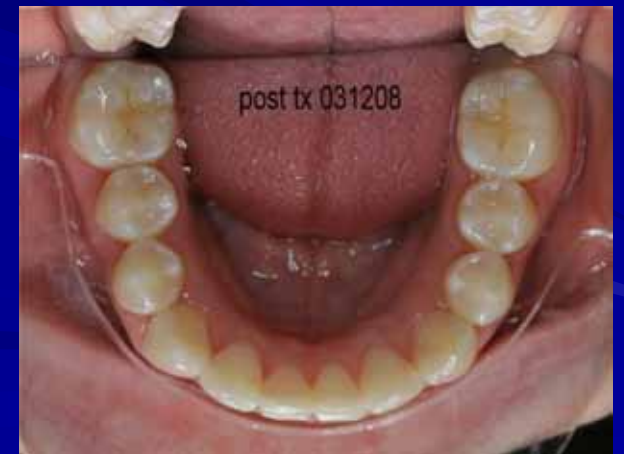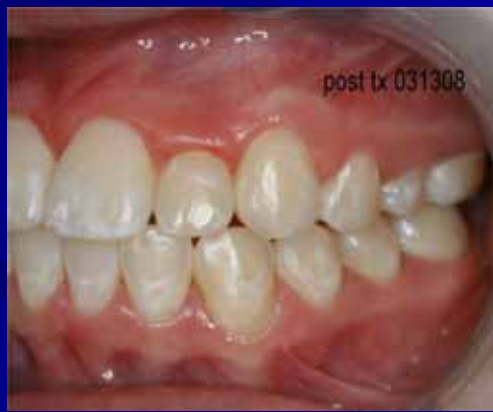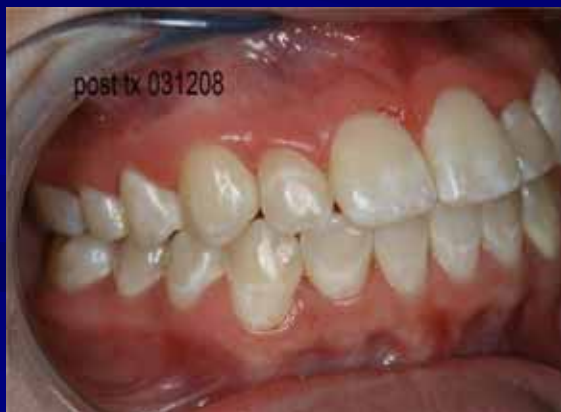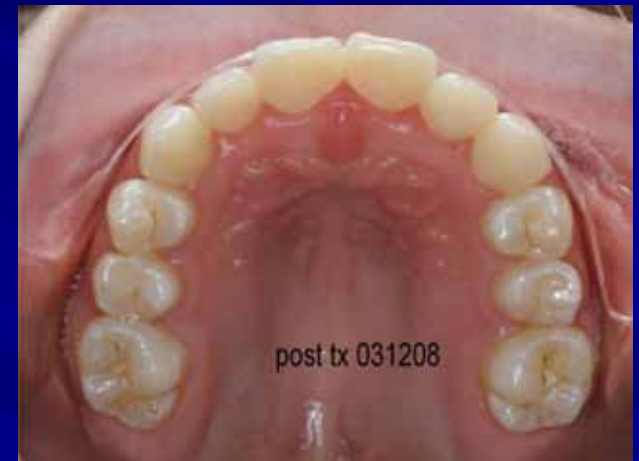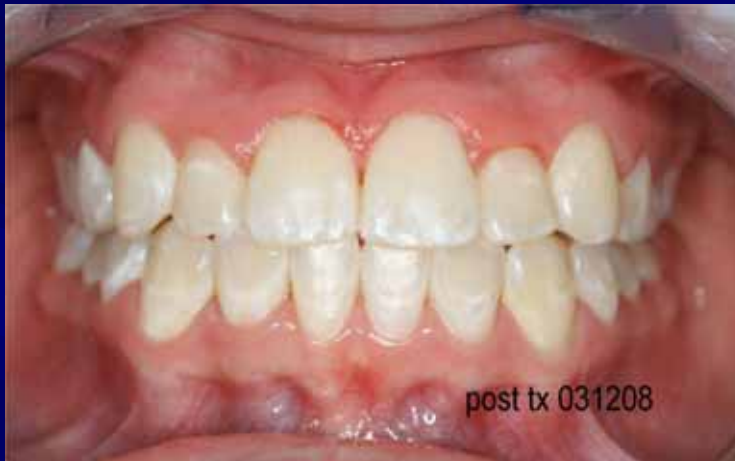Karli: Pre & Mid treatment



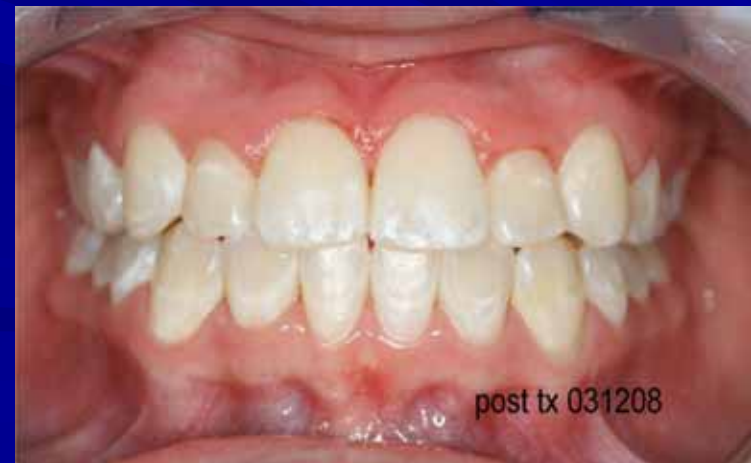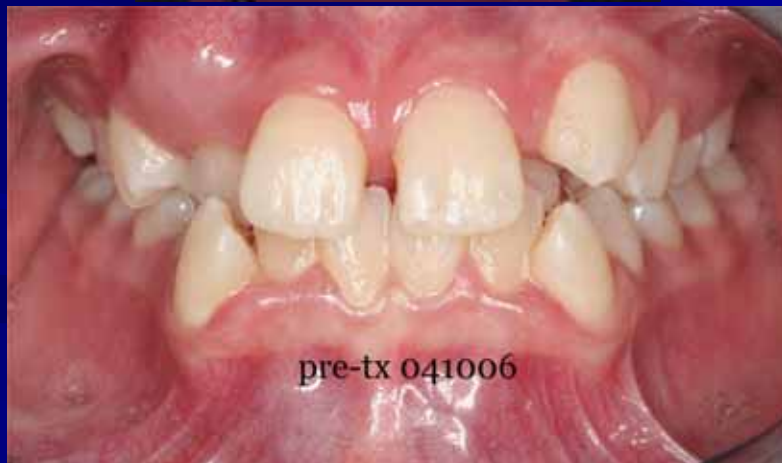Karli: 14 months full bracket Tx



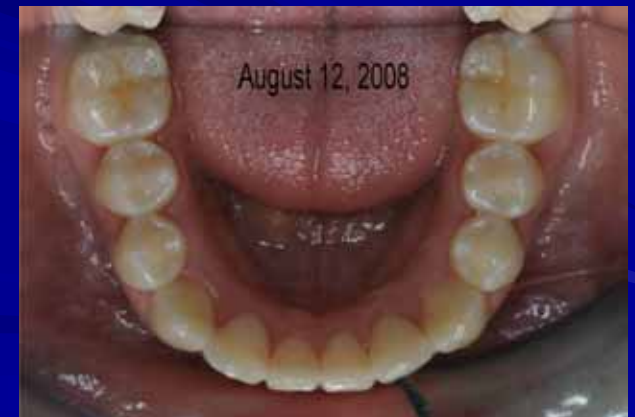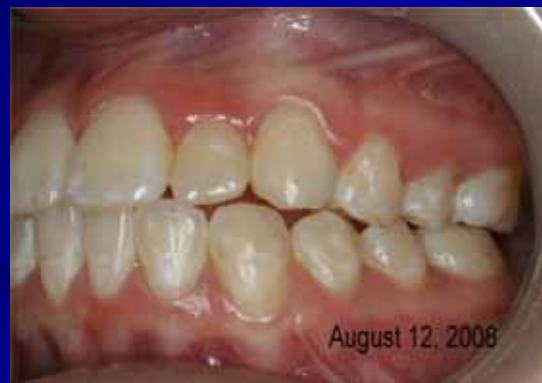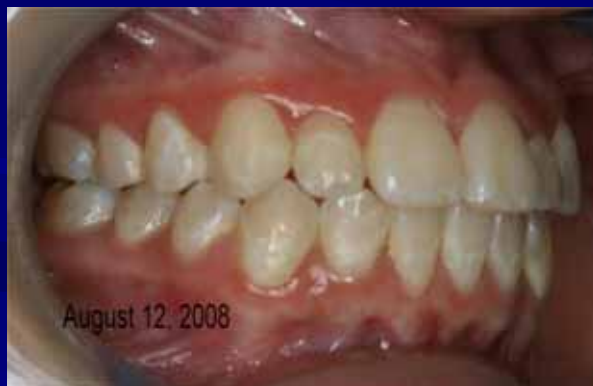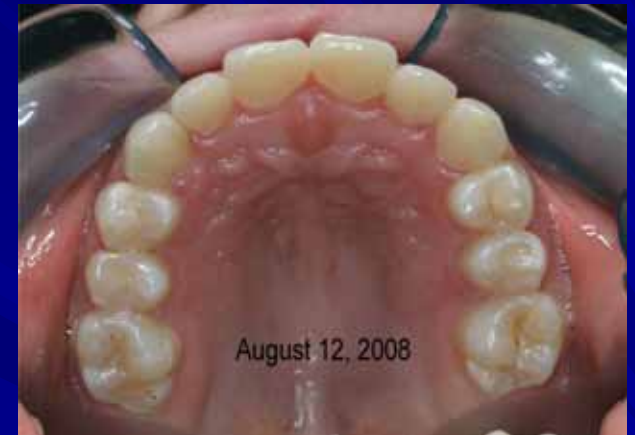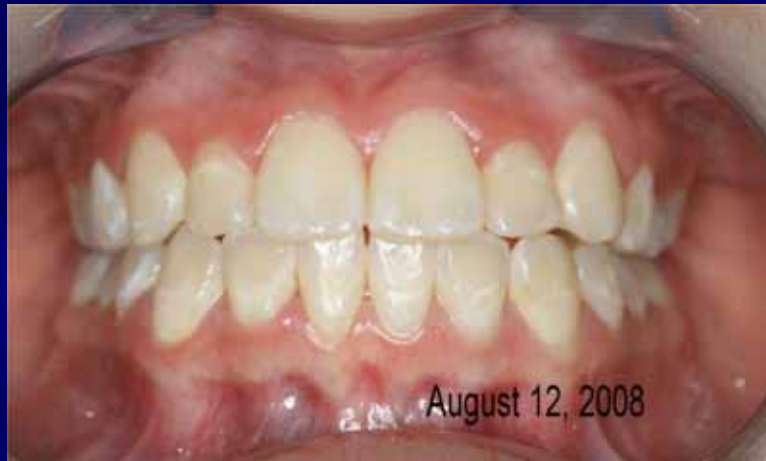Karli: Post treatment



Karli: Pre & Post treatment

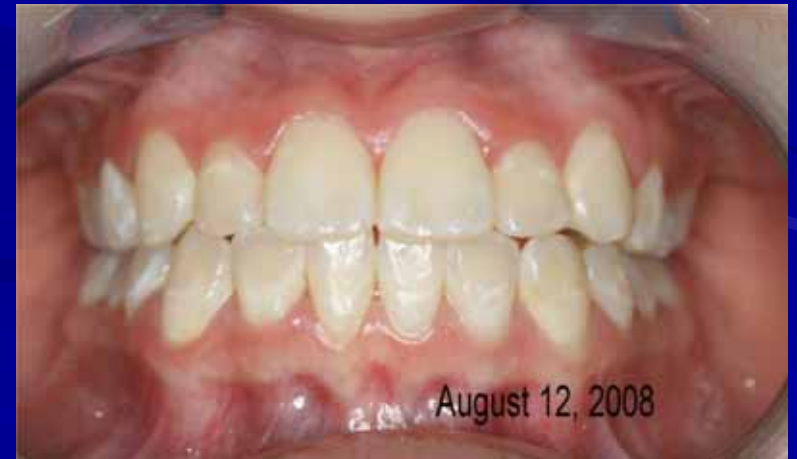

Karli: 7 months retention



Karli

- Extraction of upper & lower second molars
- Upper & lower 2-way Sagittals 6 months
- Full brackets 14 months
- De-bracket/positioner for retention 7 months
- Presently upper & lower 3x3's



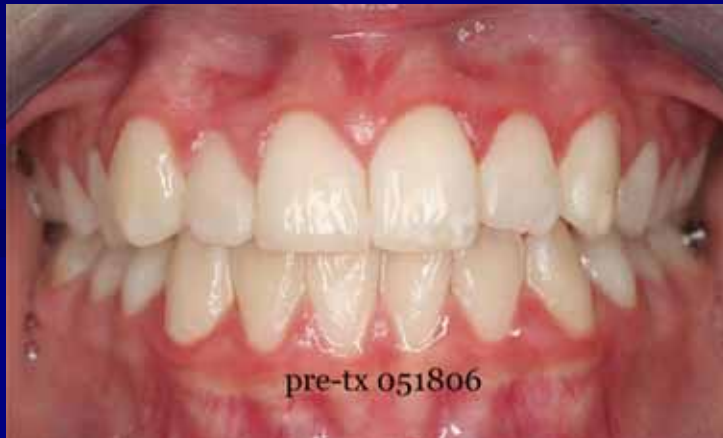Class I Molar Full Bracket Treatment

Class I

Julie: 13 years of age



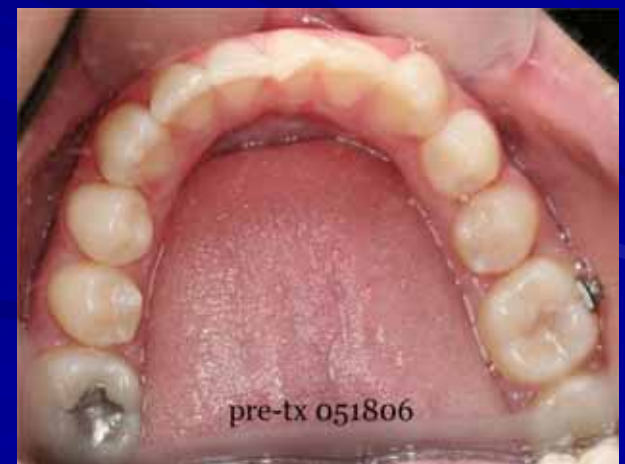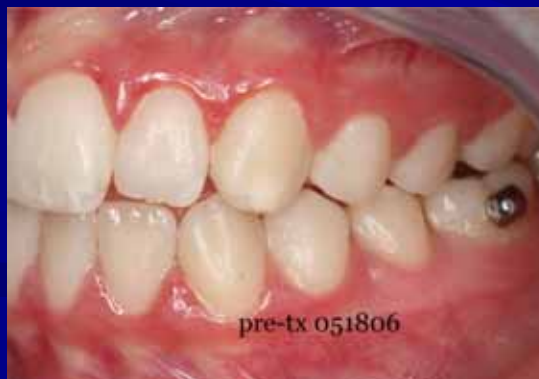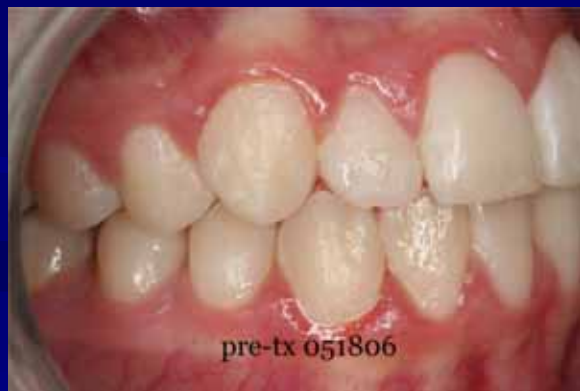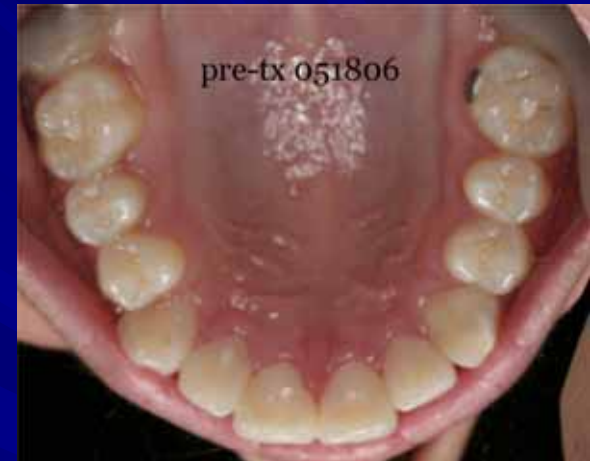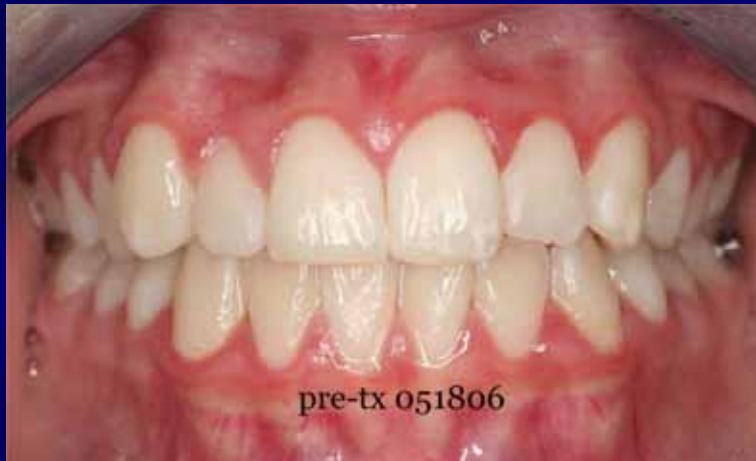- Class I full tooth
- Overjet 1 mm
- Overbite 1mm
- Class I facial profile



Class I

Julie: 13 years of age

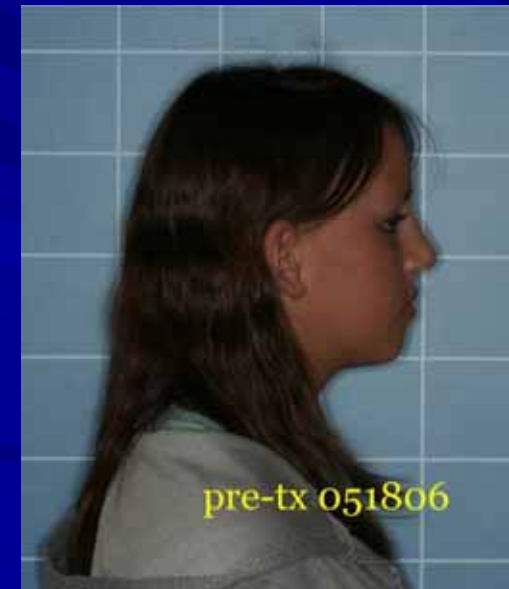Pre-treatment



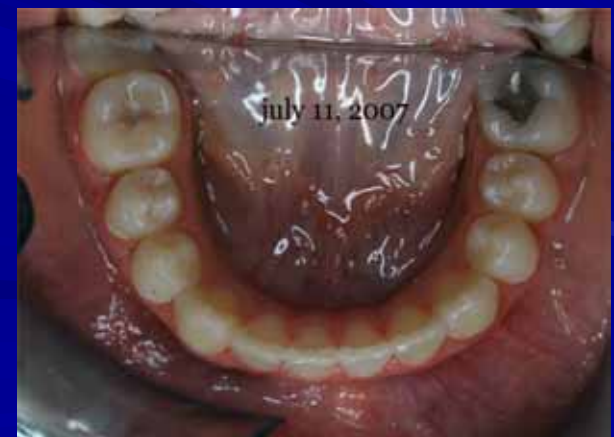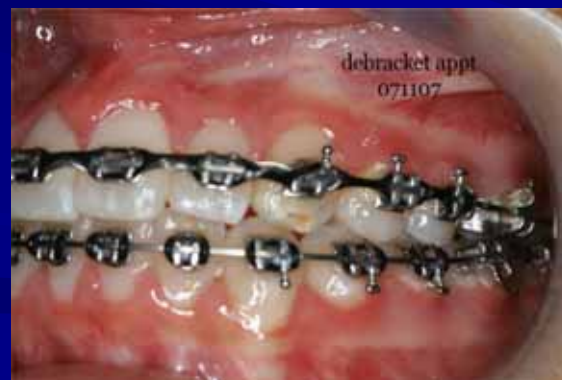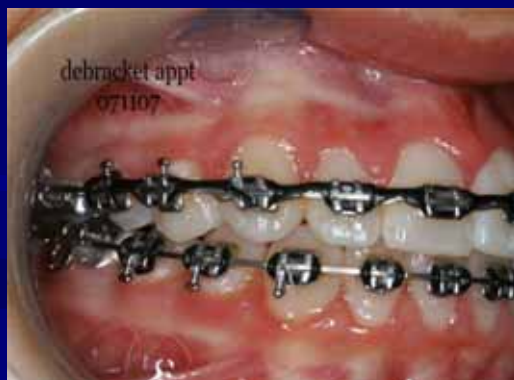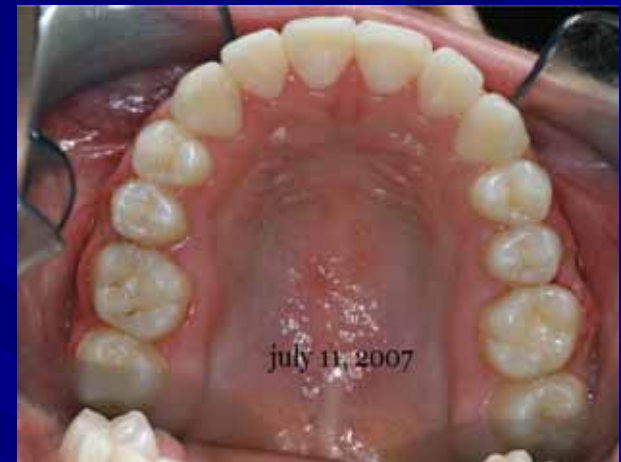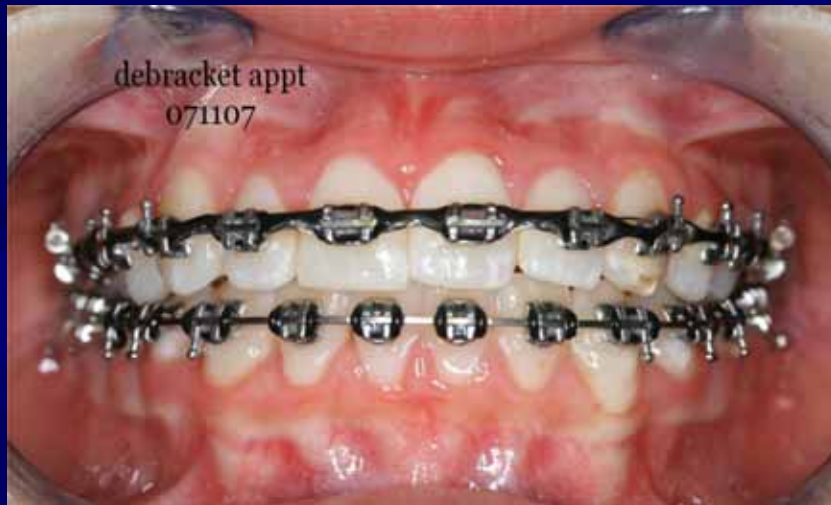Class I

Julie: 13 years of age

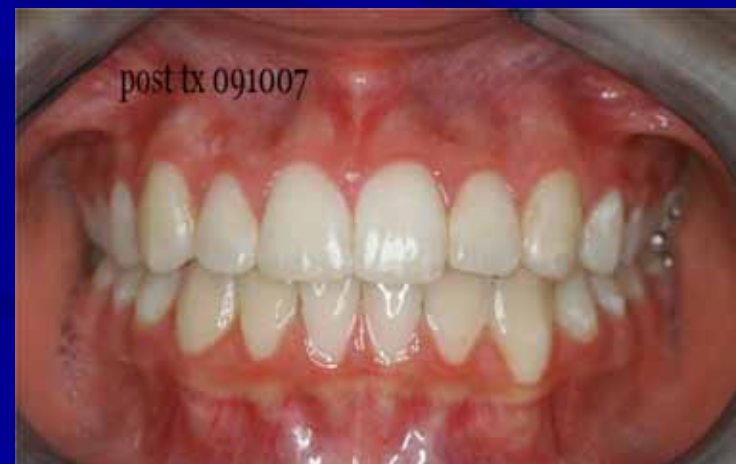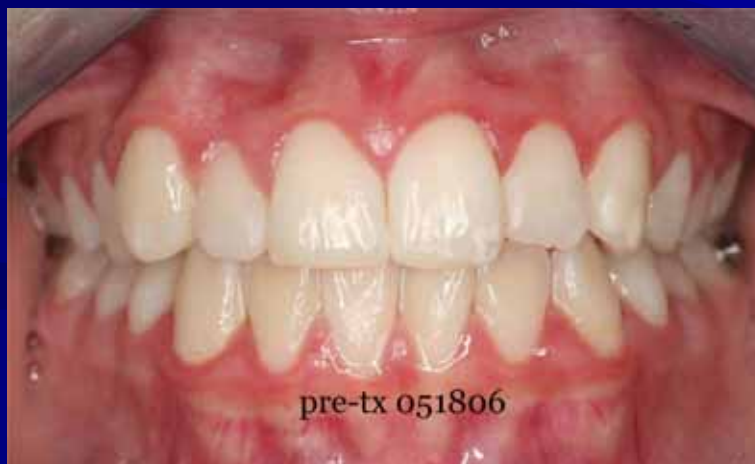Pre-treatment



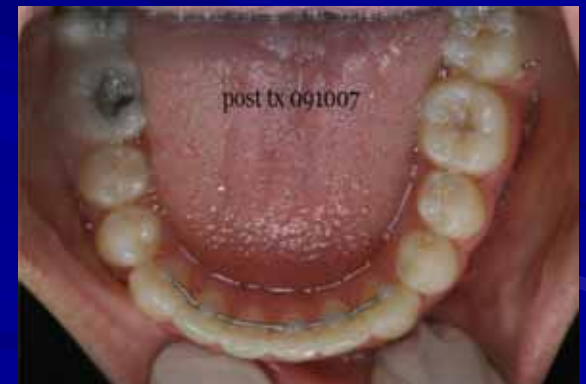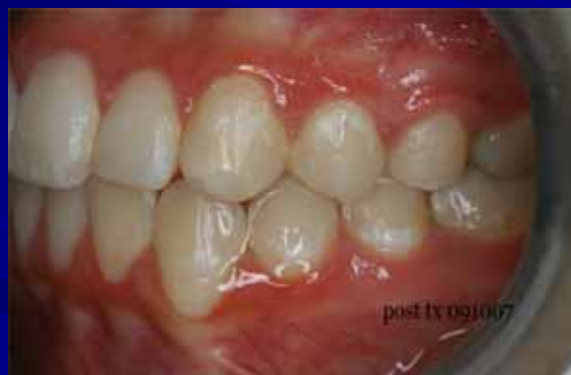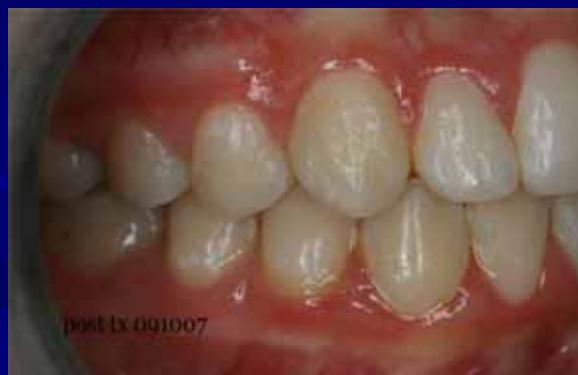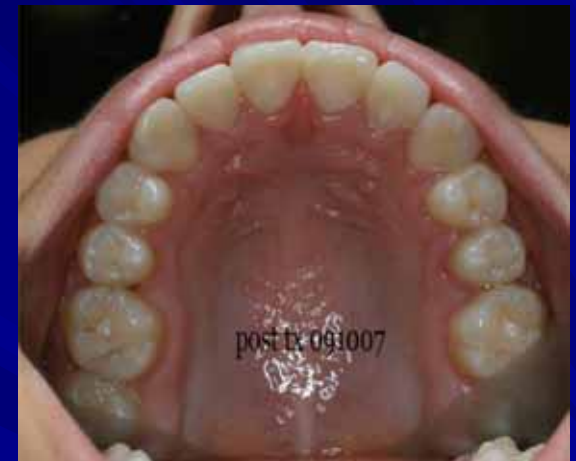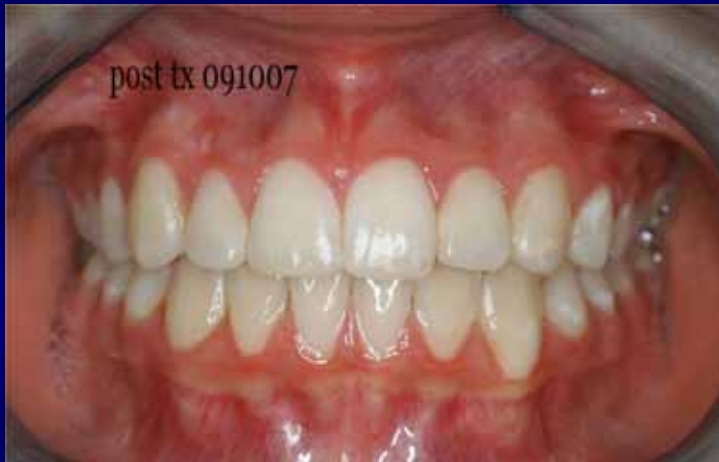Julie: 12 months full bracket Tx



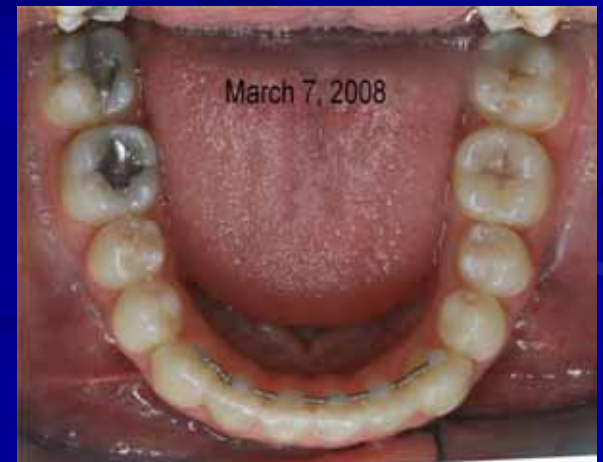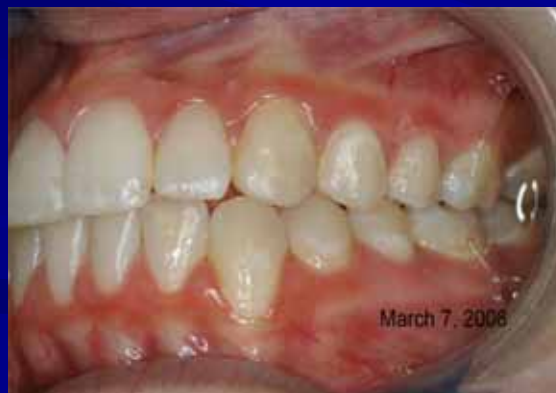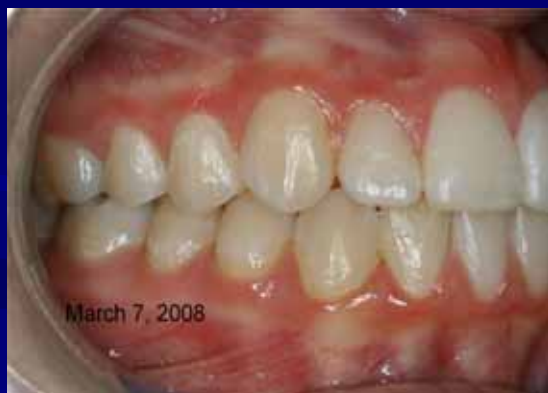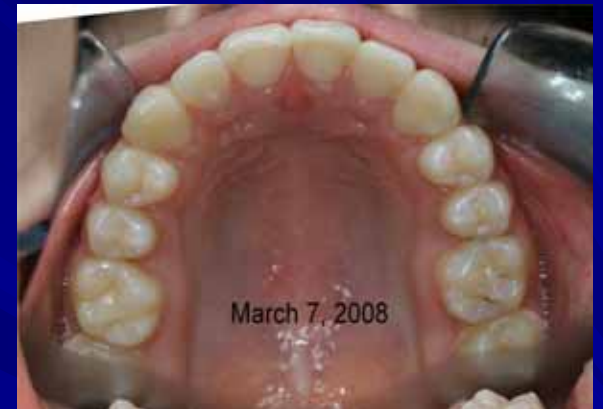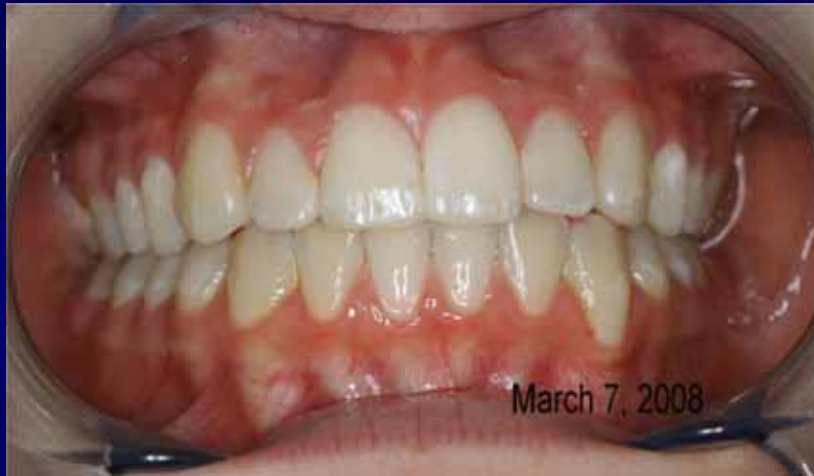Julie: 12 months active Tx



Julie: Post treatment

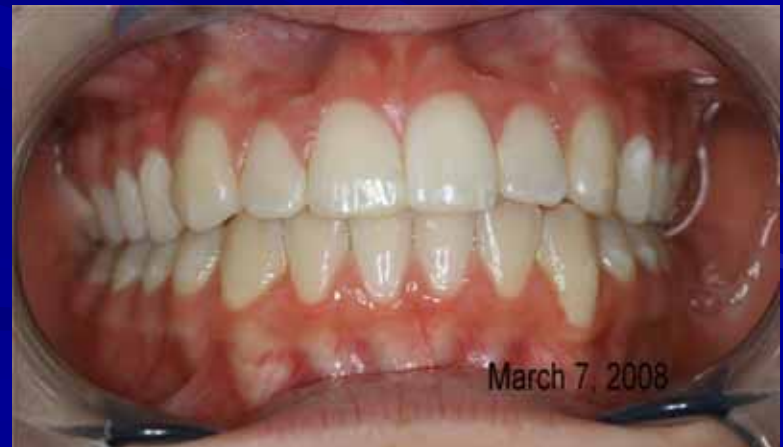

Julie: 8 months retention



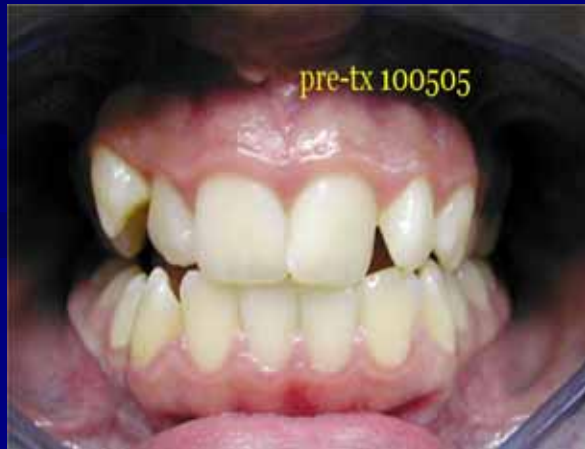Julie

- Full brackets 12 months
- Upper QCM Hawley
- Lower 3x3



Class I

Karlee: 14 years of age

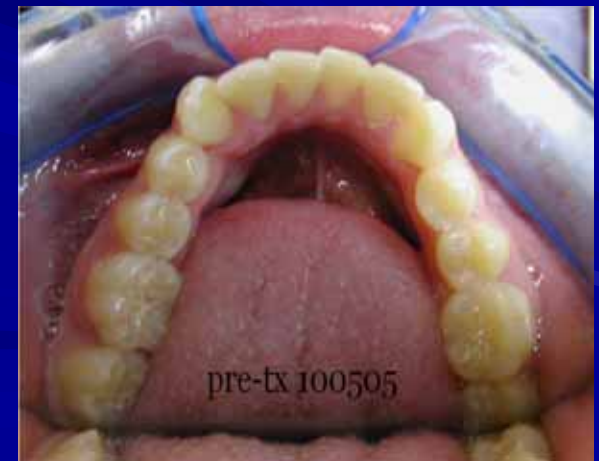
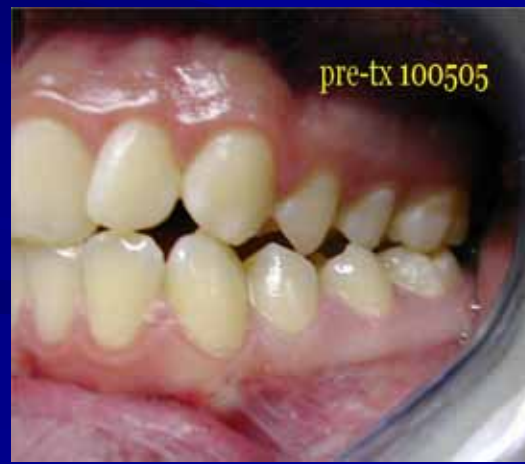
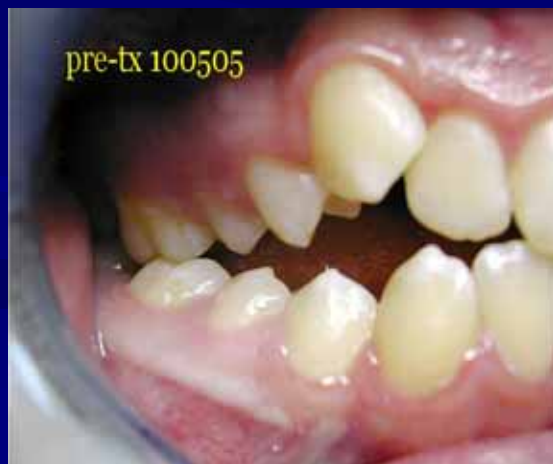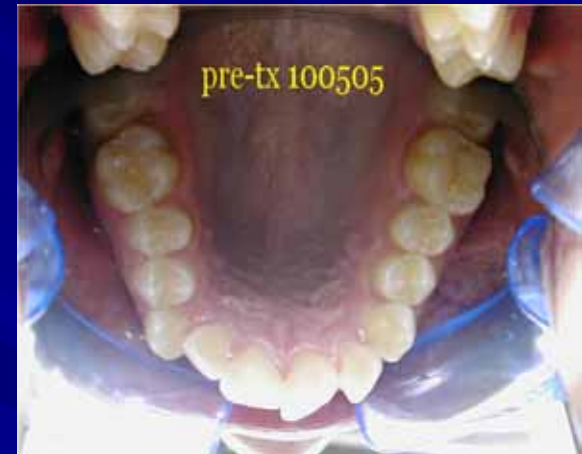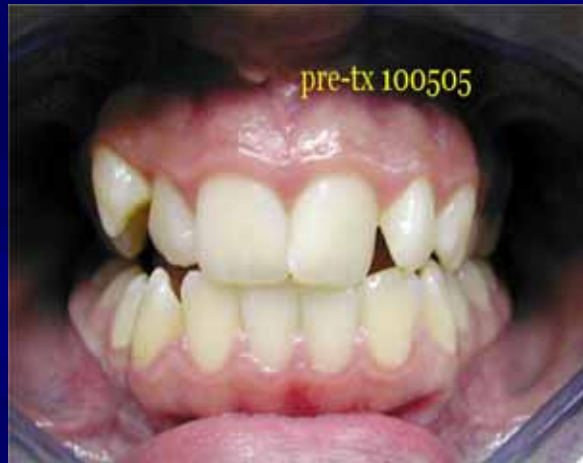- Class I 1/2 tooth
- End to end
- Class I facial profile
- Concern:
Straight teeth

Class I

Karlee: 14 years of age

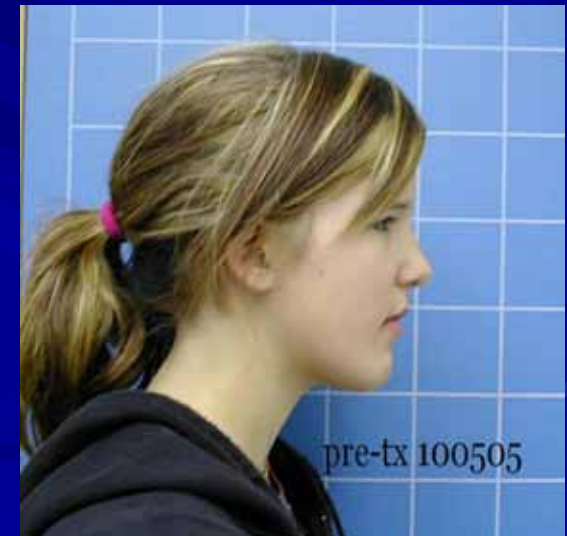Pre-treatment



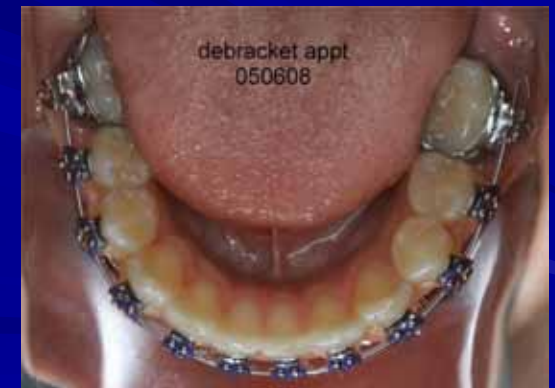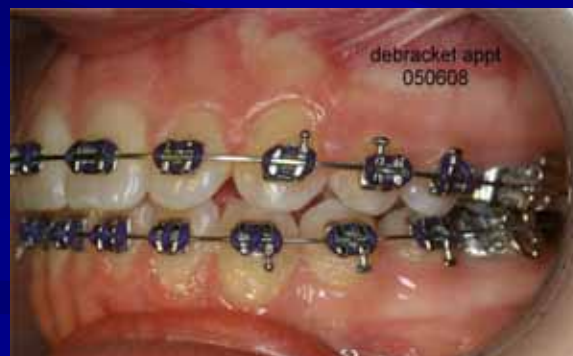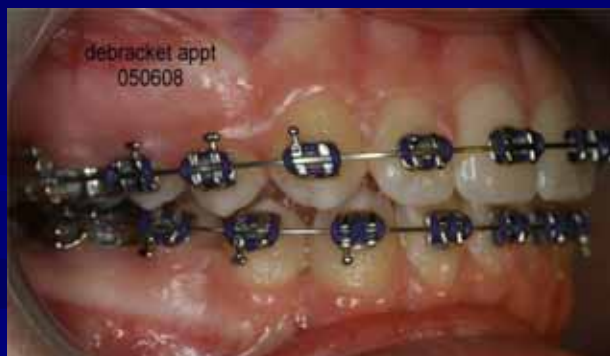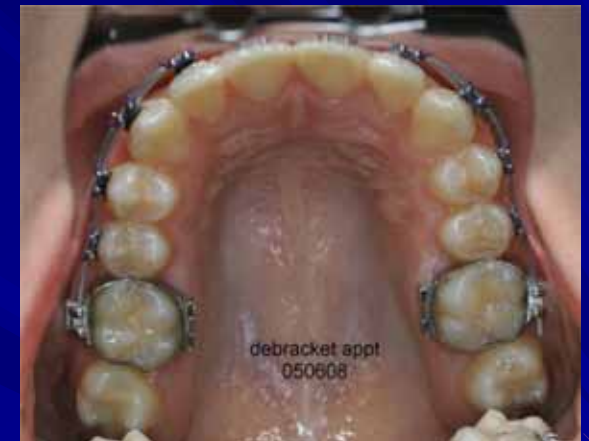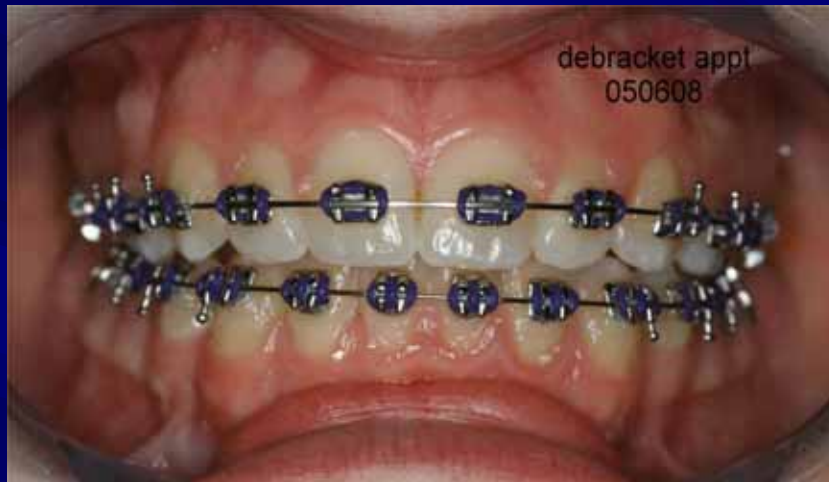Class I

Karlee: 14 years of age

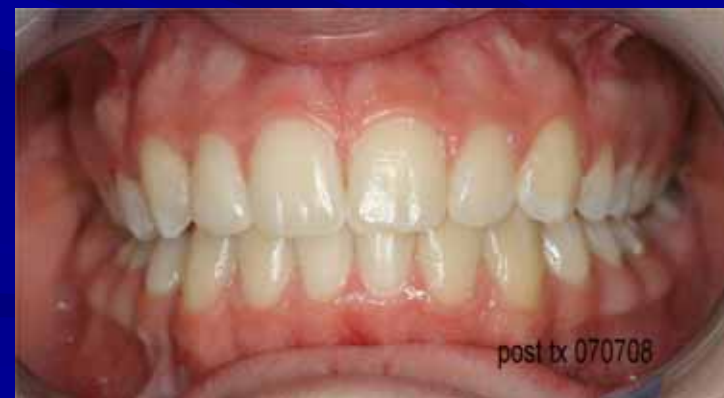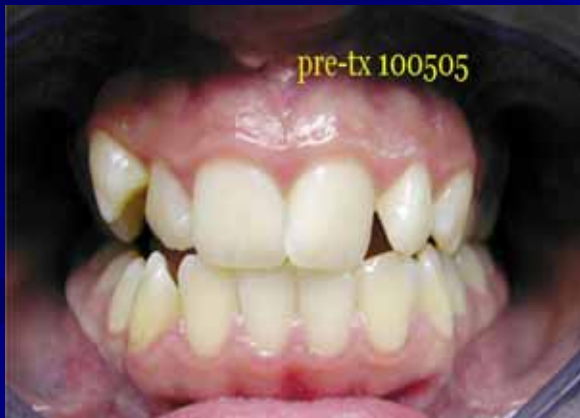Pre-treatment



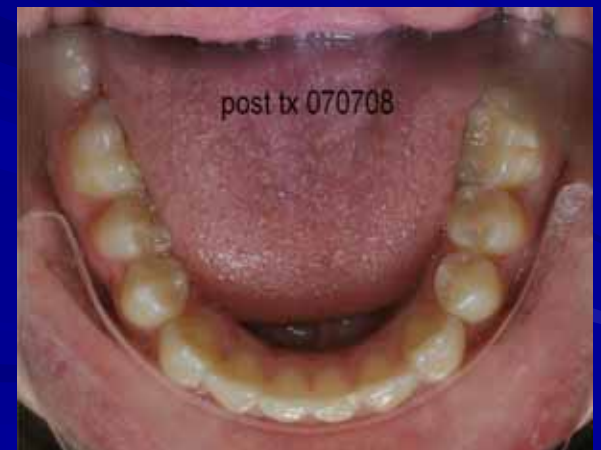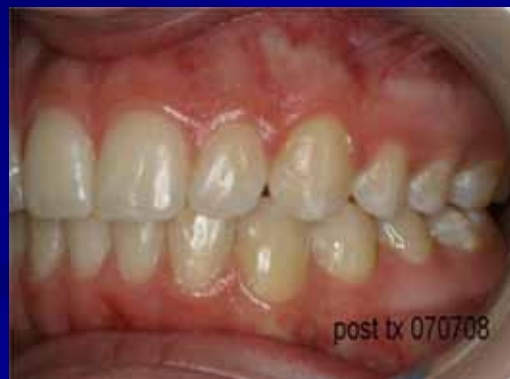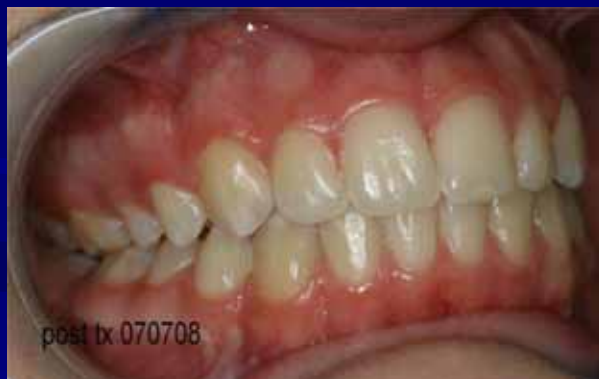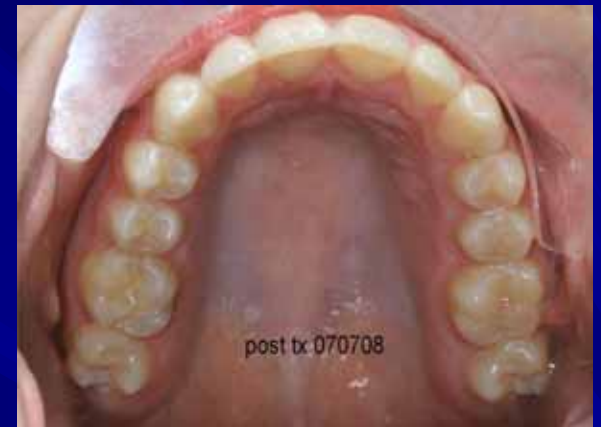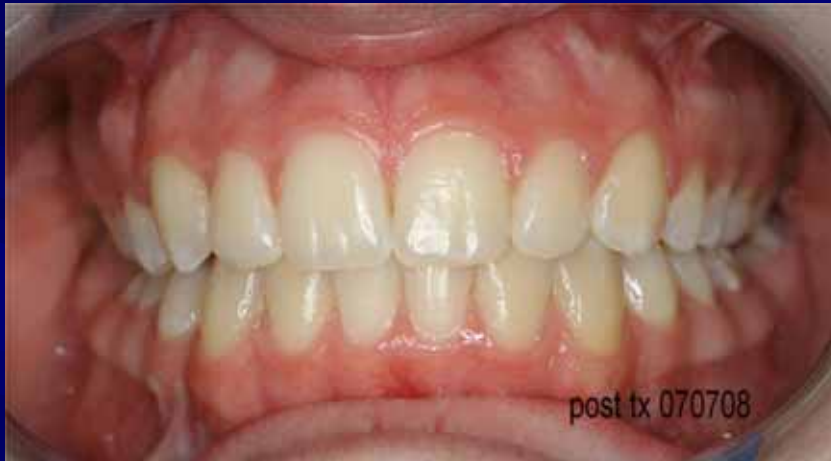Karlee: 16 months full bracket Tx



Karlee: 16 months active Tx

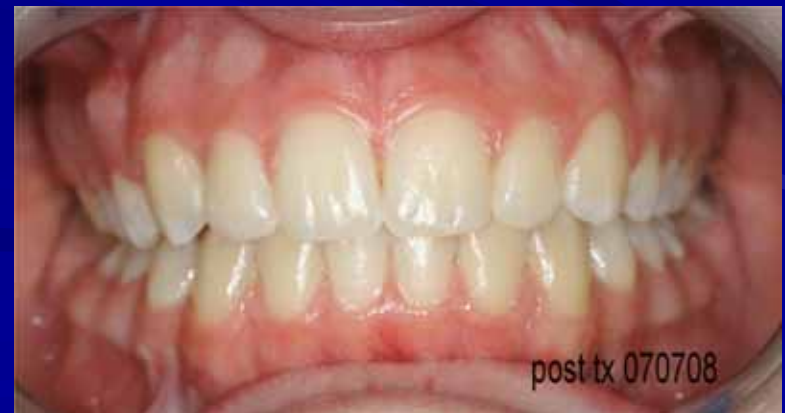

Karlee: Post treatment



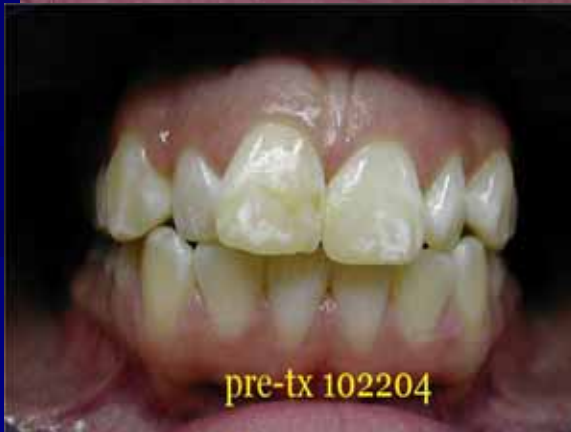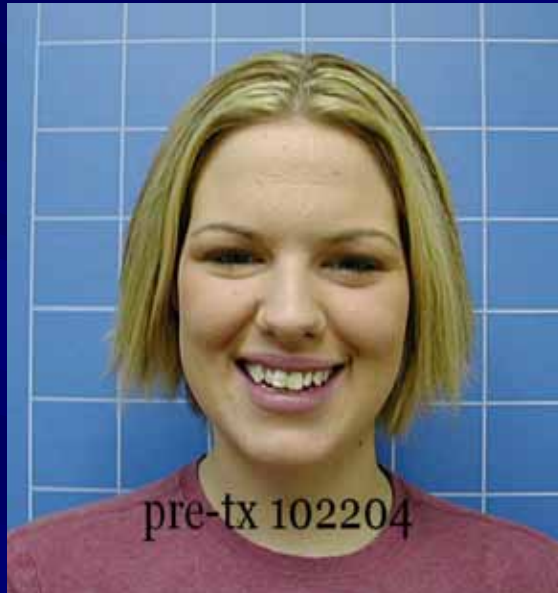Karlee

- Extraction of 47/37
- Full brackets 16 months
- Upper Quad Helix
- Intra oral vertical box elastics 4 ½ oz, ¼”
- Positioner for retention
- 17/27 will leave until 18/28 start erupting



Class I

Laura: 17 years of age

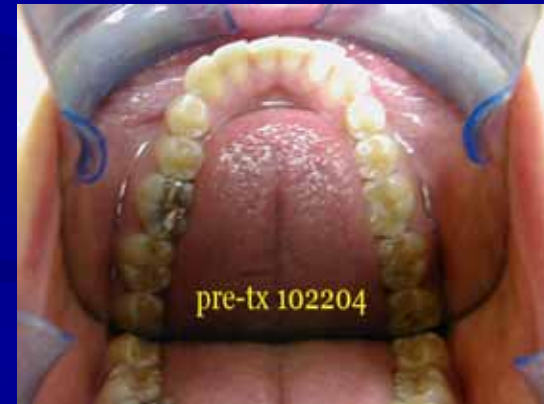
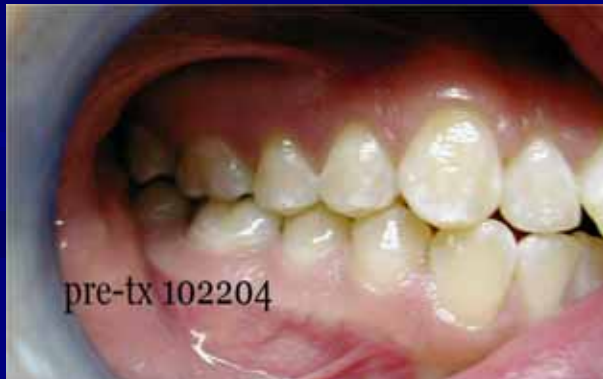
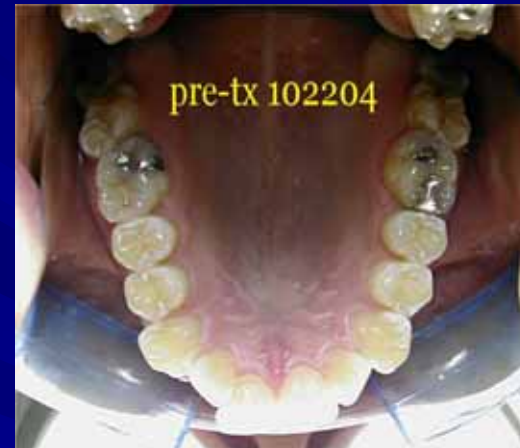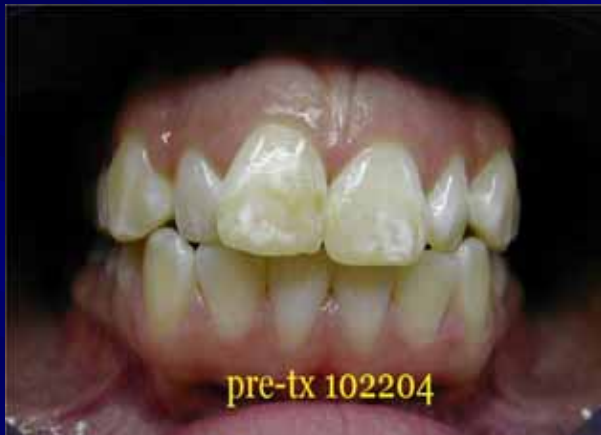- Class I full tooth
- Overjet 2 mm
- Overbite 2 mm
- Class I facial profile
- Concern: Straight 12

Class I

Laura: 17 years of age

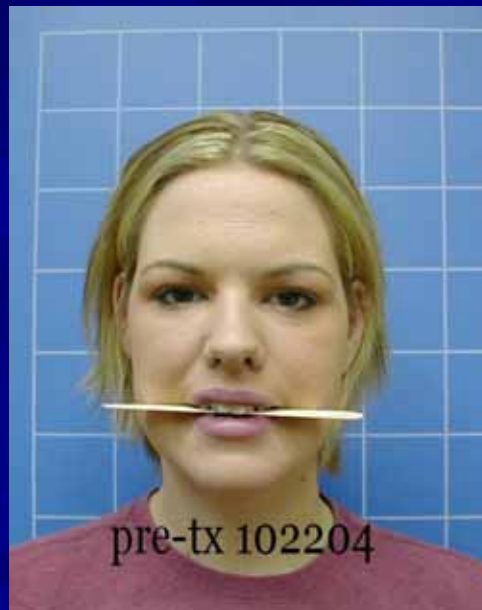Pre-treatment



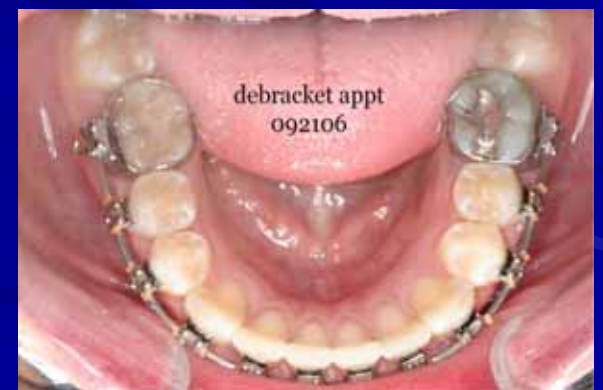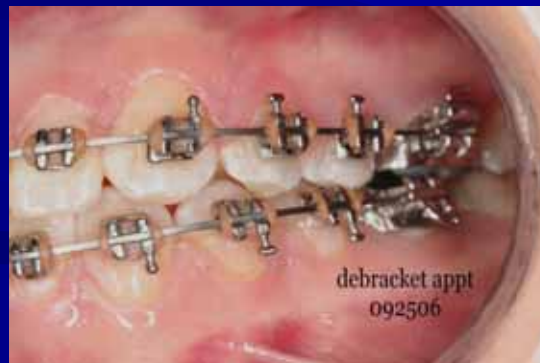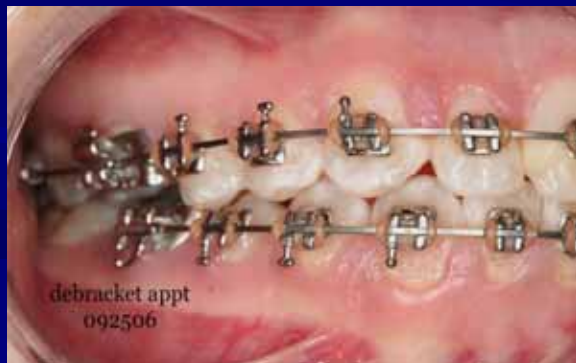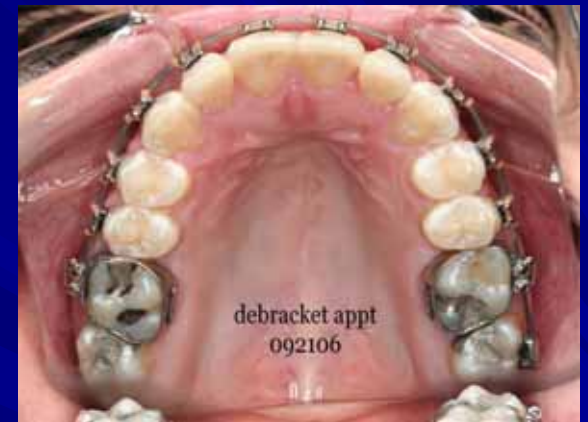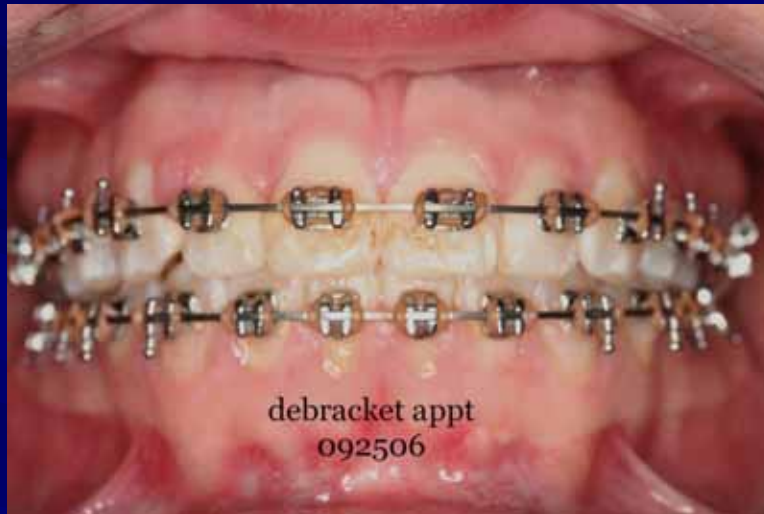Class I

Laura: 17 years of age

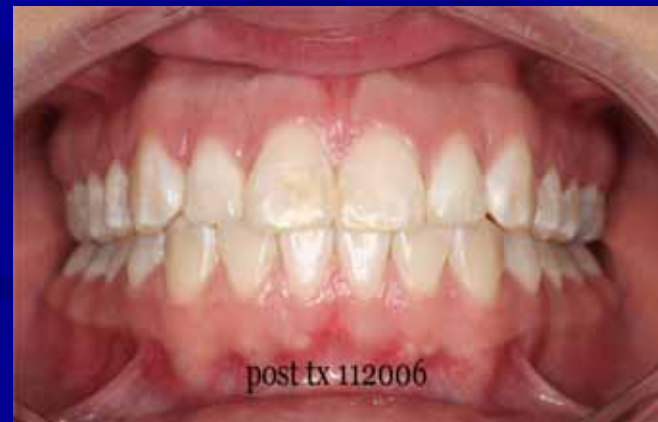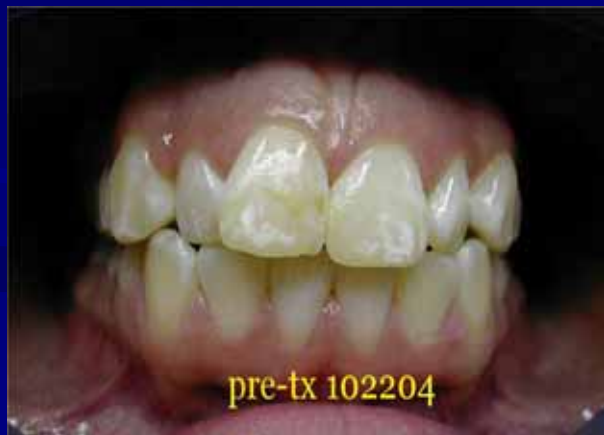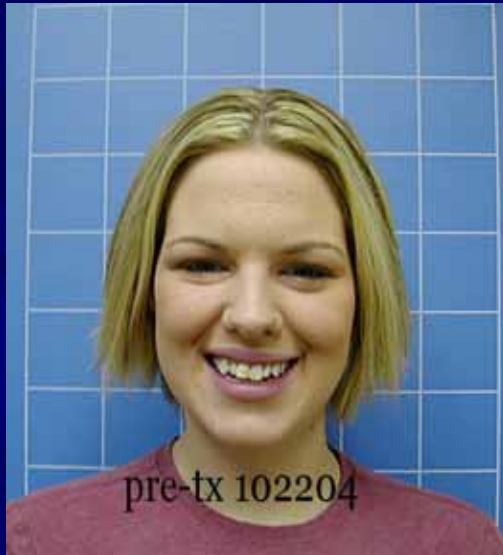Pre-treatment



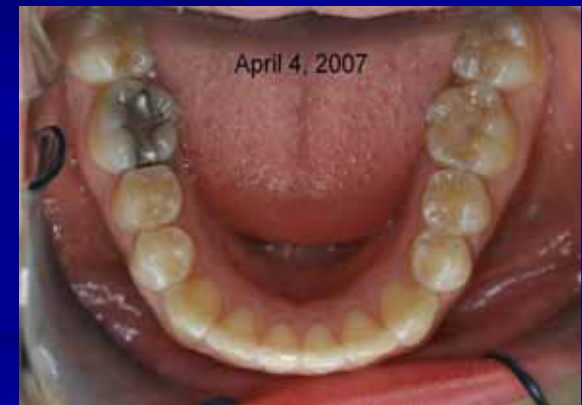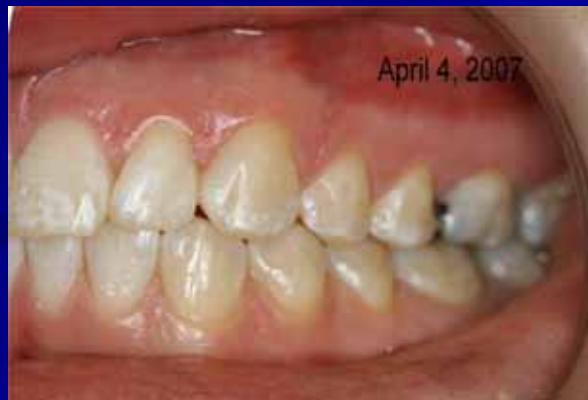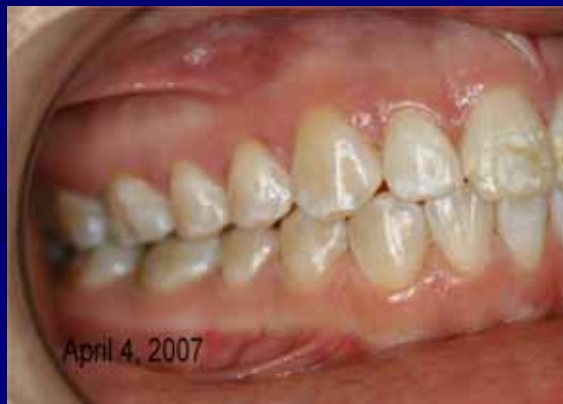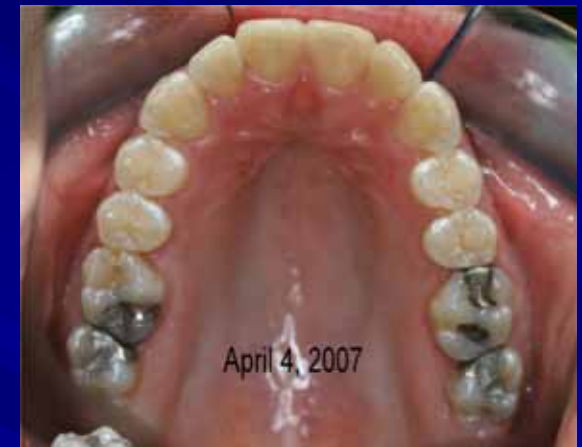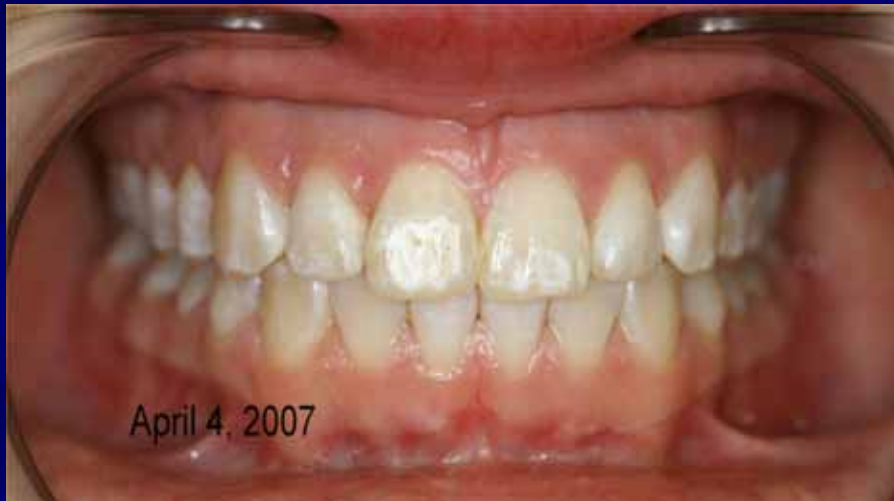Laura: 10 months full bracket Tx



Laura: 10 months active Tx

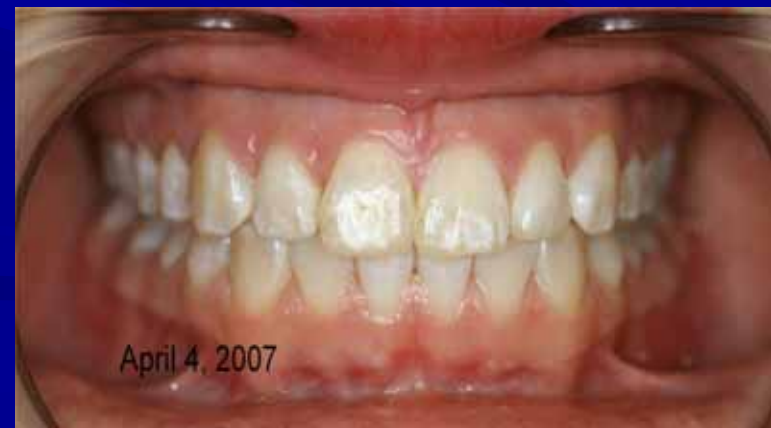

Laura: 7 months retention



Laura

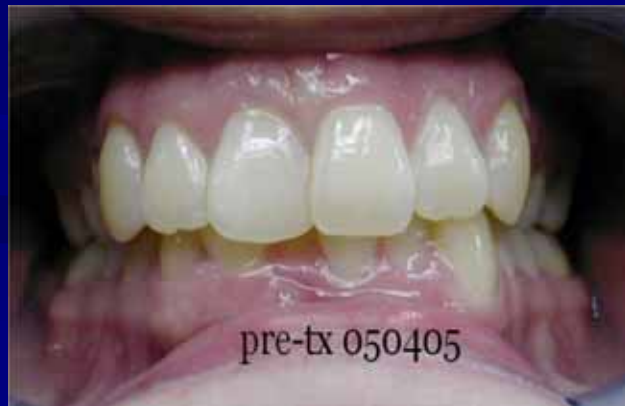- Full brackets with upper Hyrax 10 months
- Stop adjusting Hyrax at 3 months
- Removed Hyrax at 6 months
- De-bracket/ positioner for retention 7 months
- Presently slipcovers for retention



Class II Molar Full Bracket Treatment

Class II

Tanus: 31 years of age

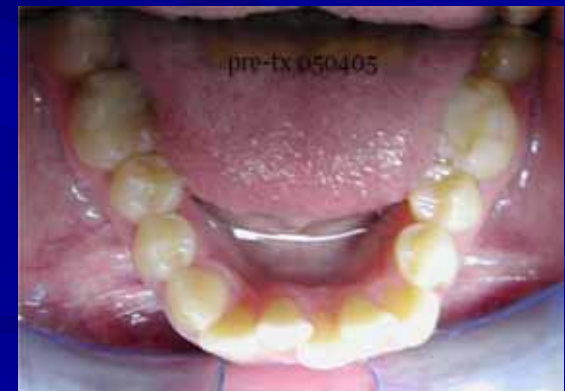
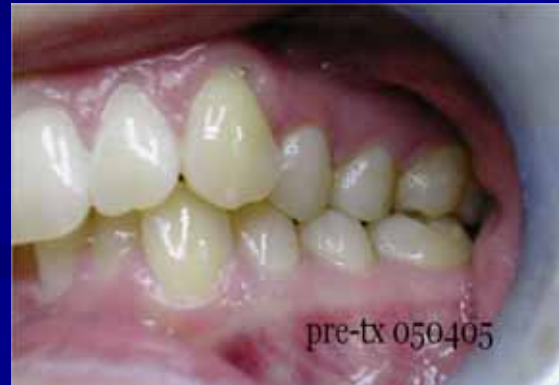
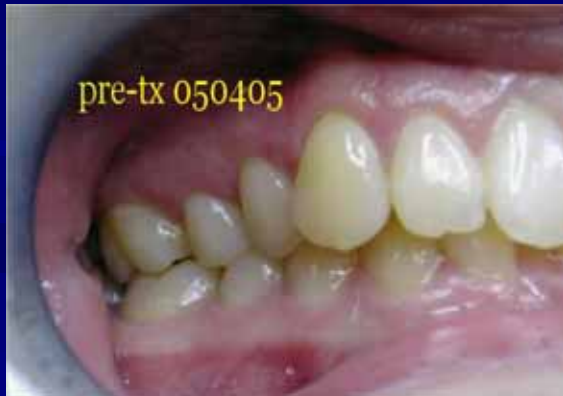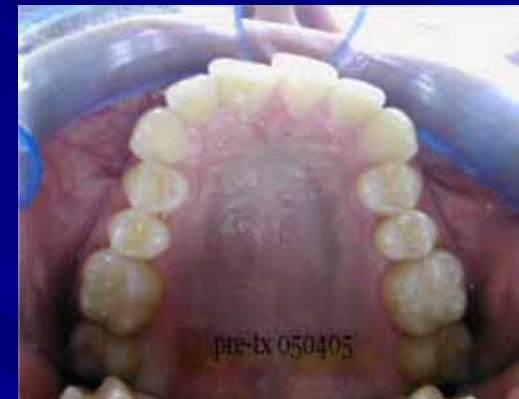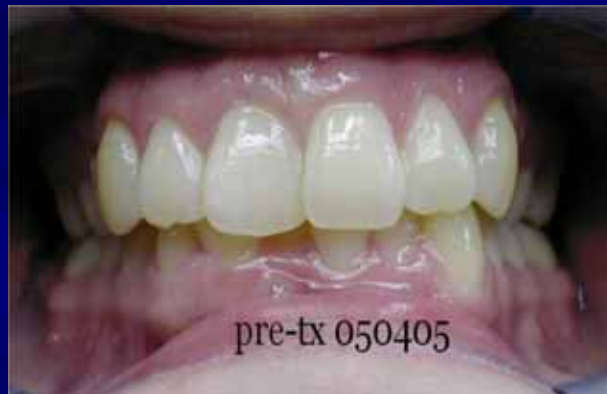- Class II ½ tooth
- Overjet 3 mm
- Overbite 60%
- Class facial profile
- No headaches

Class II

Tanus: 31 years of age

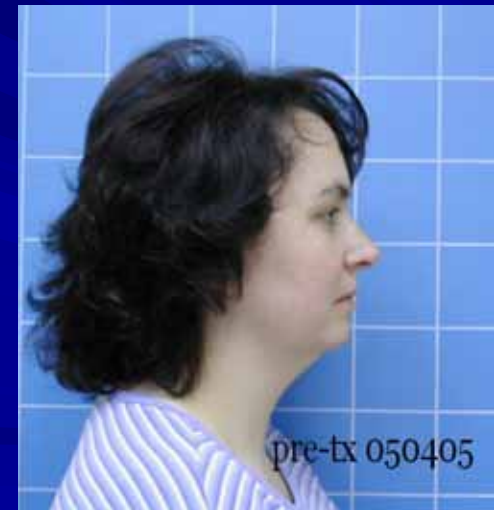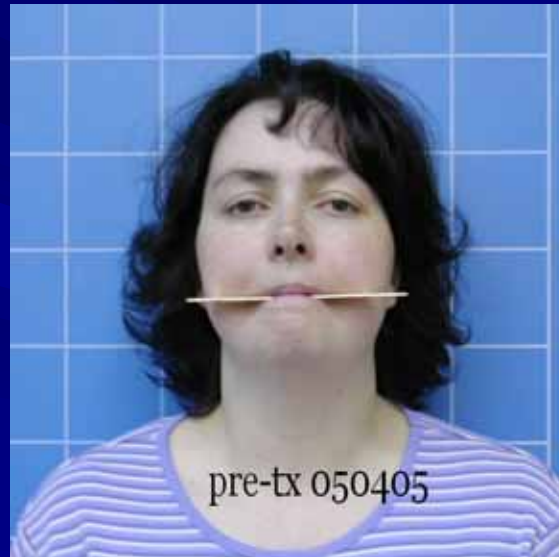Pre-treatment



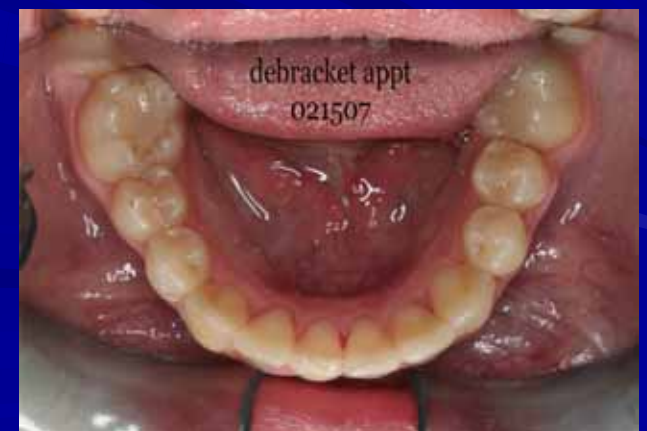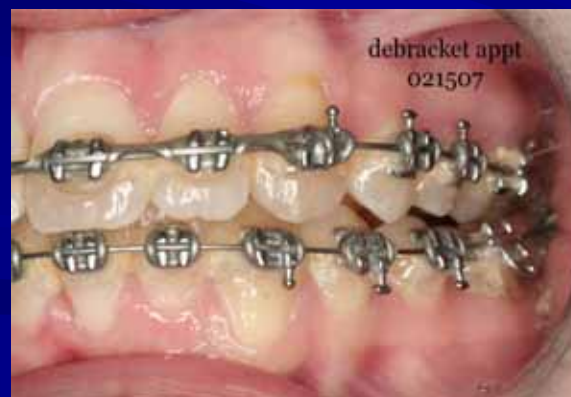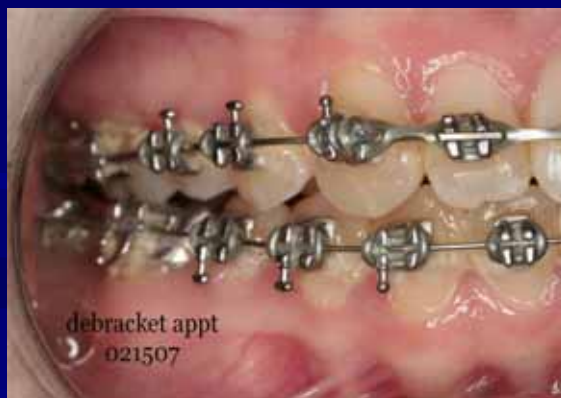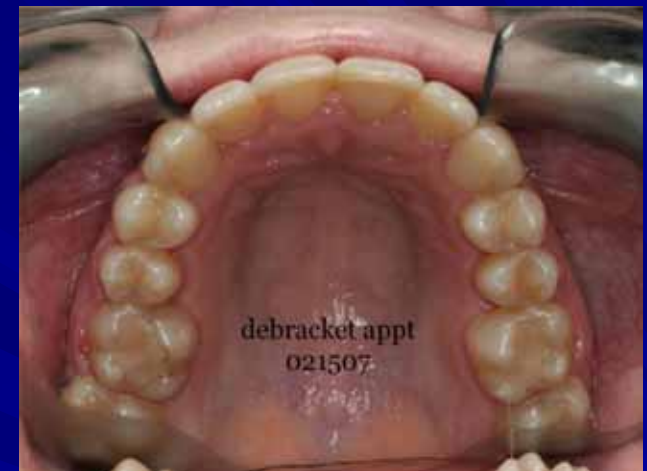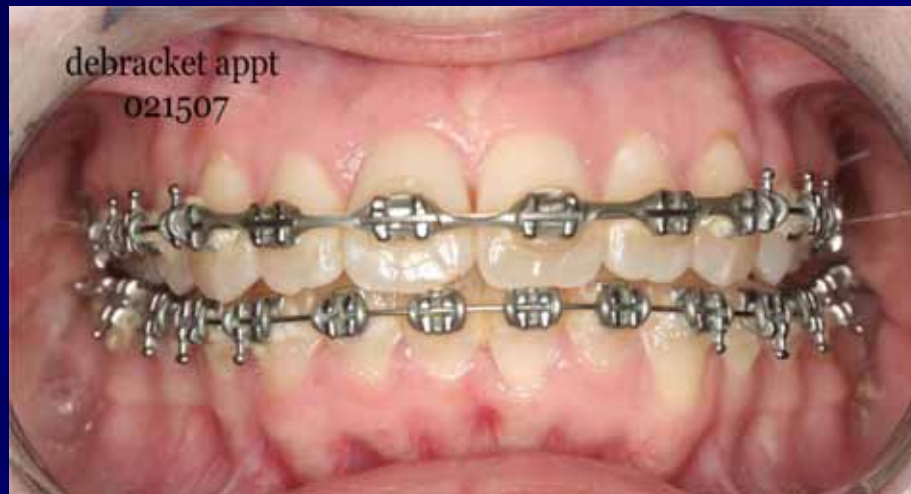Class II

Tanus: 31 years of age

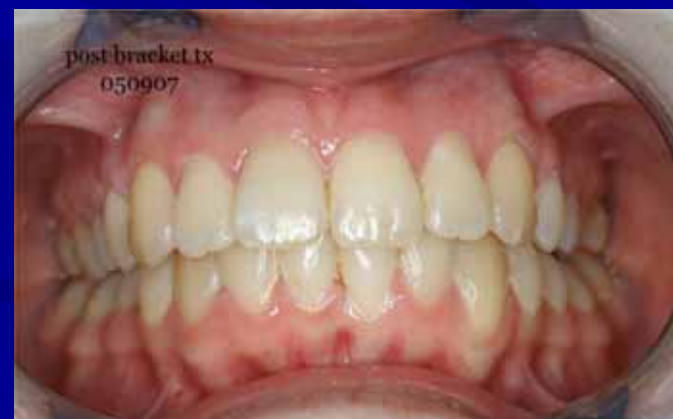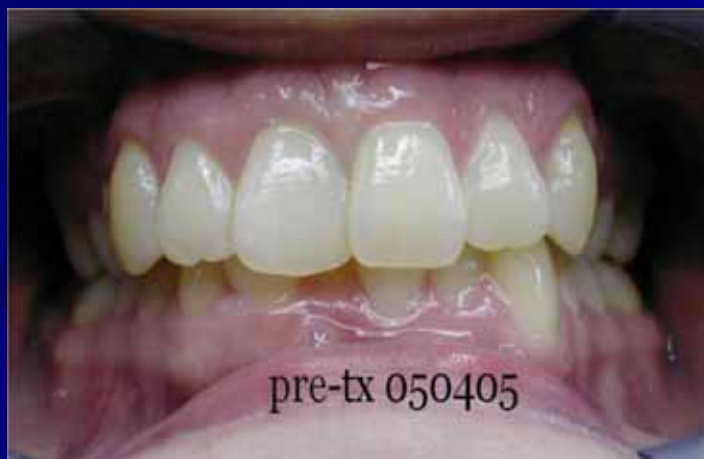Pre-treatment



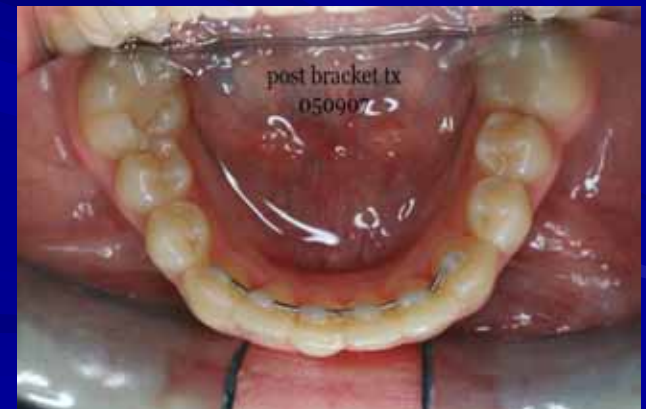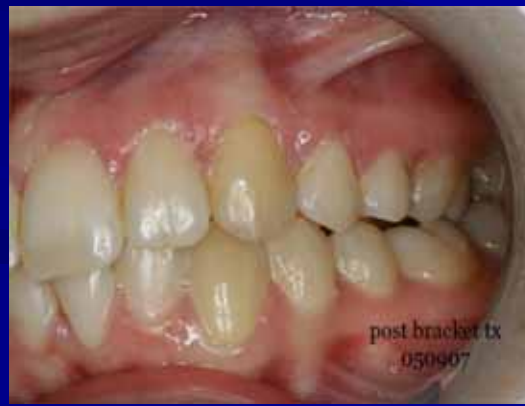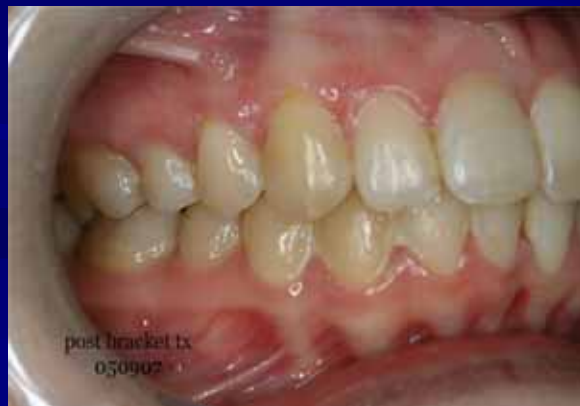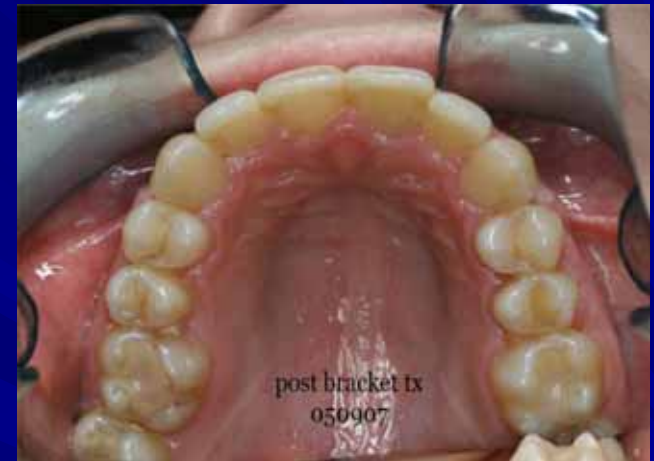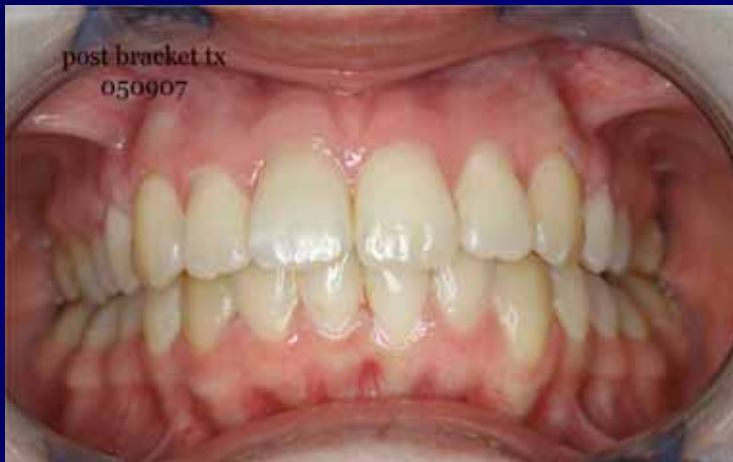Tanus: 17 months full bracket Tx



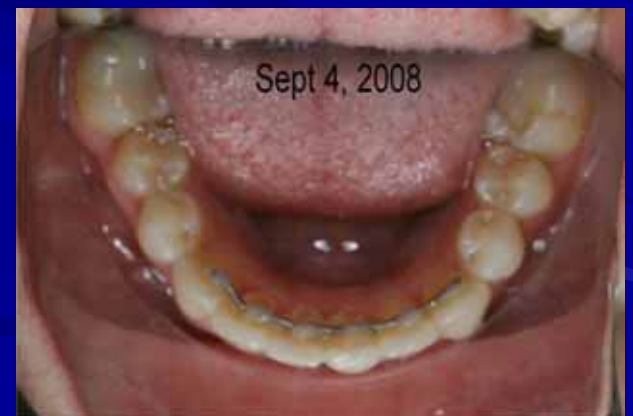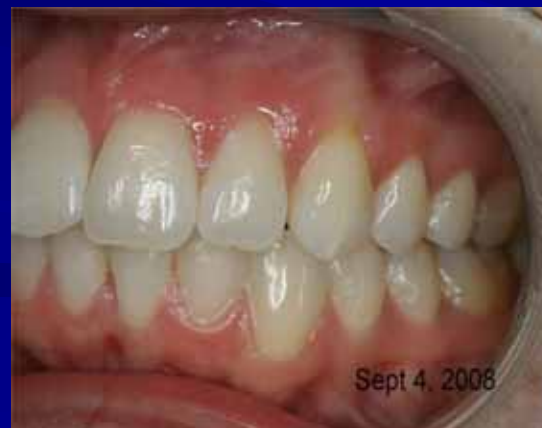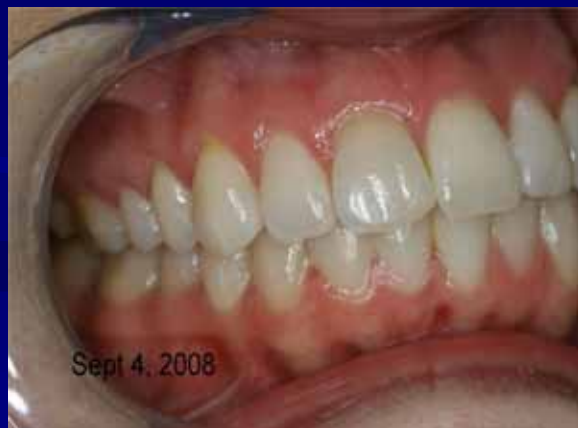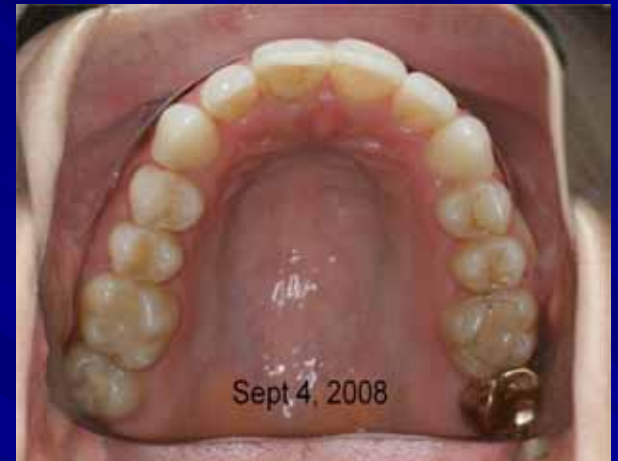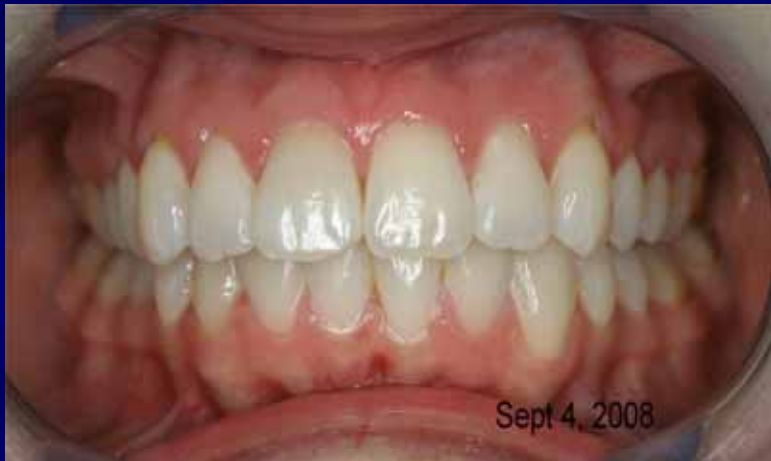Tanus: 17 months of active Tx



Tanus: Post treatment

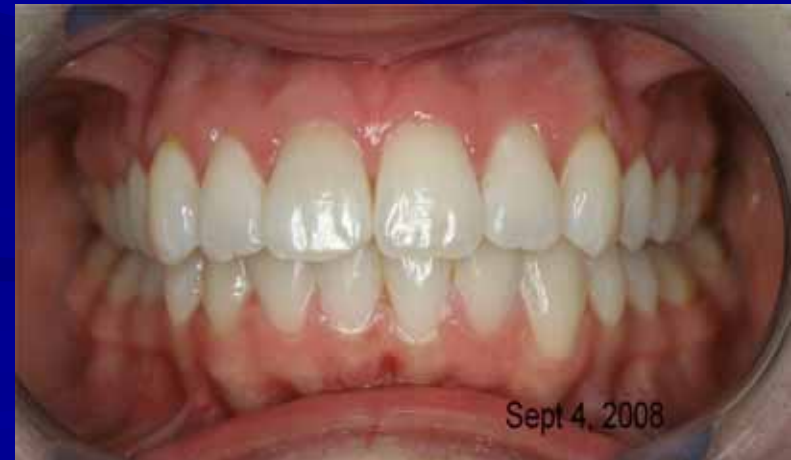

Tanus: 19 months retention




Tanus

- Full brackets with tripods
- Class II elastics
- Slenderized lower 5's
- Intra oral vertical box elastics
- Upper Hawley/ lower bonded 3x3

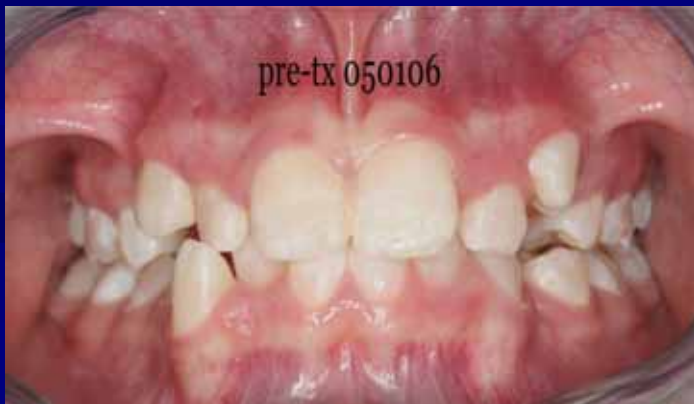

Class II

Anna: 13 years of age



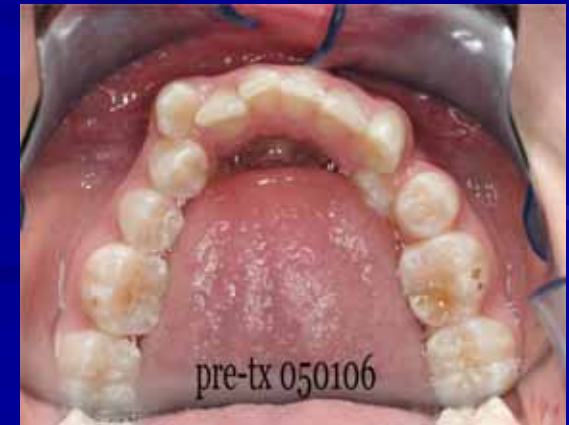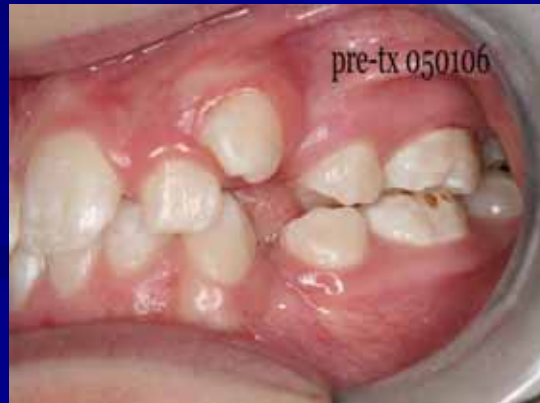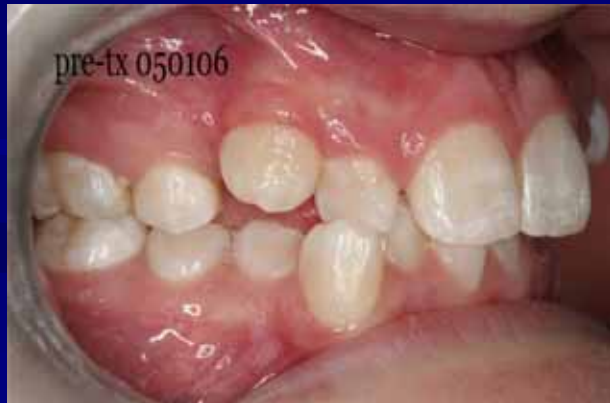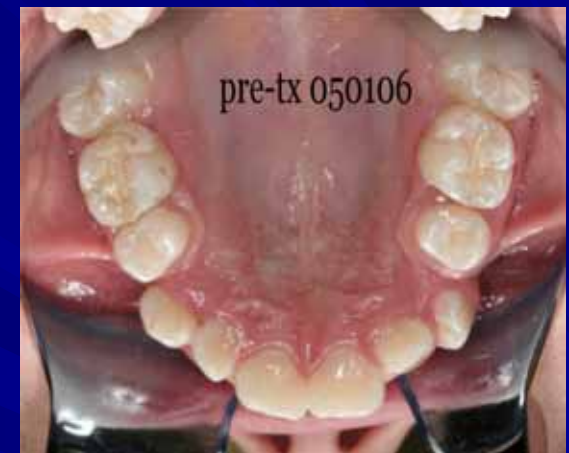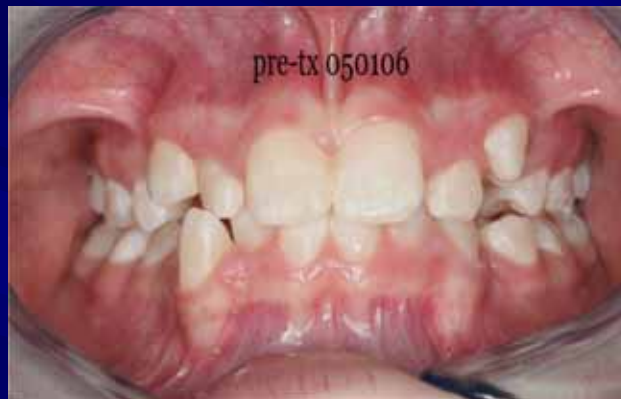- Class II ½ tooth
- Overjet 2mm
- Overbite 50%
- Mid face deficiency
- Class I facial profile
- Constricted mx
- Previous Tx started at another office with extractions of Mx 1st bicuspids



Class II

Anna: 13 years of age

Pre-treatment



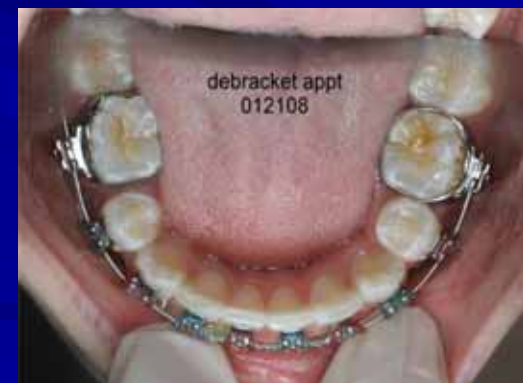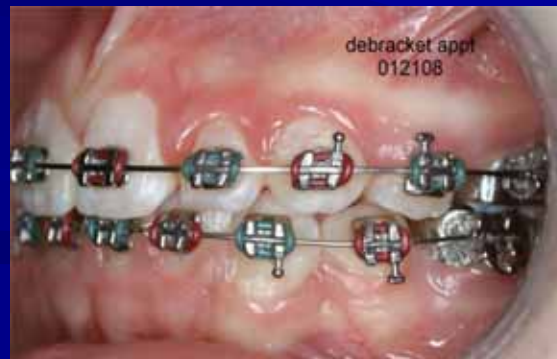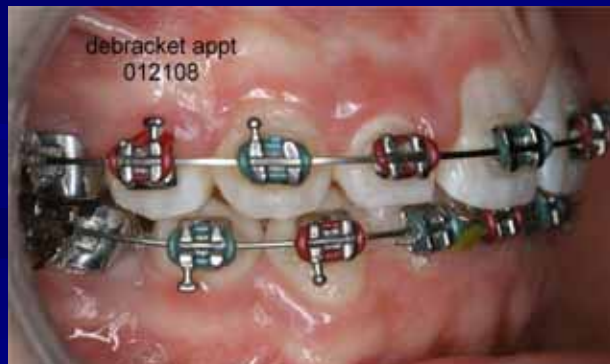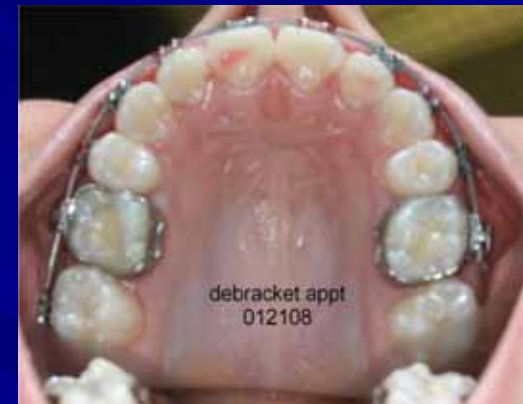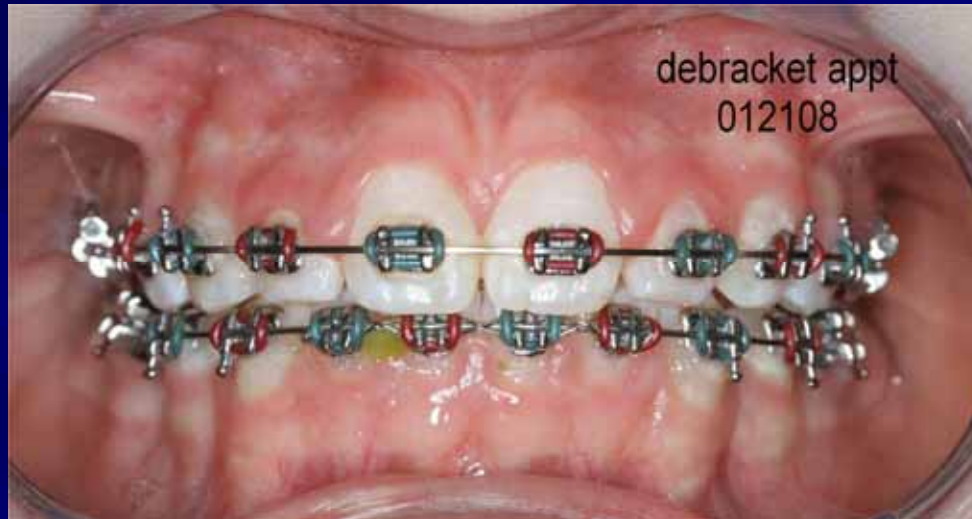Class II

Anna: 13 years of age

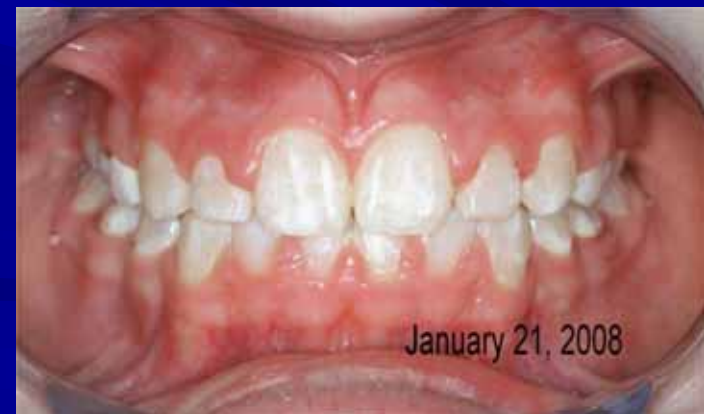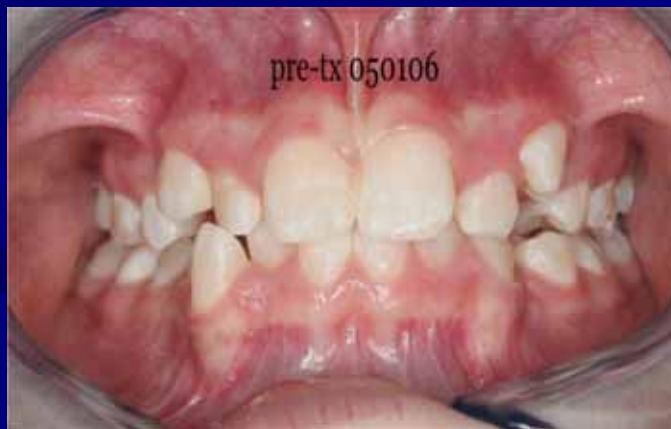Pre-treatment



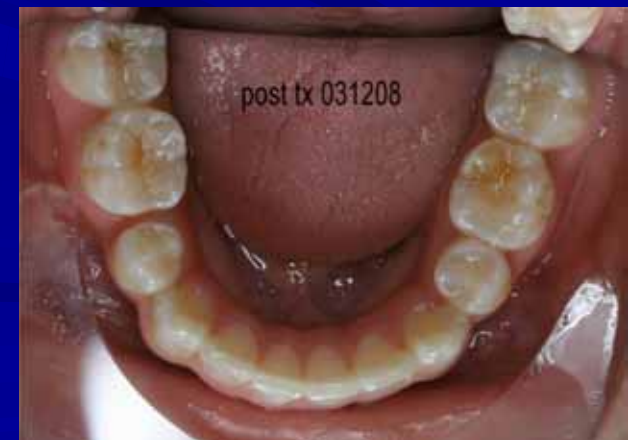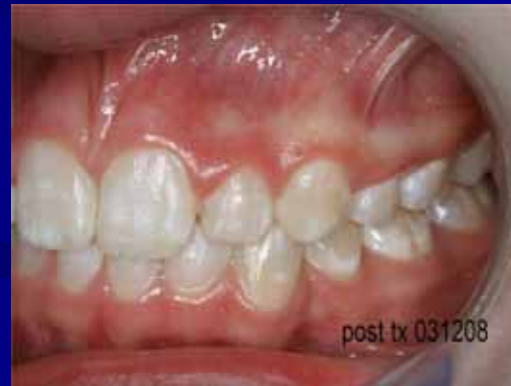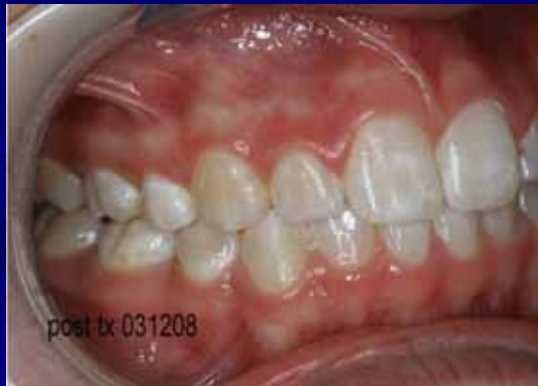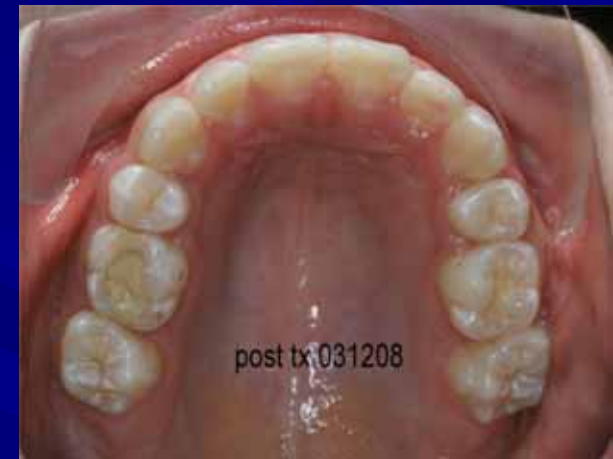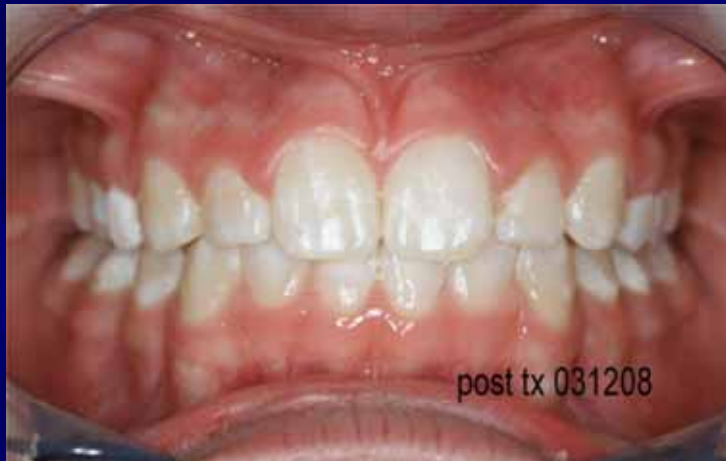Anna: 18 months of full bracket Tx



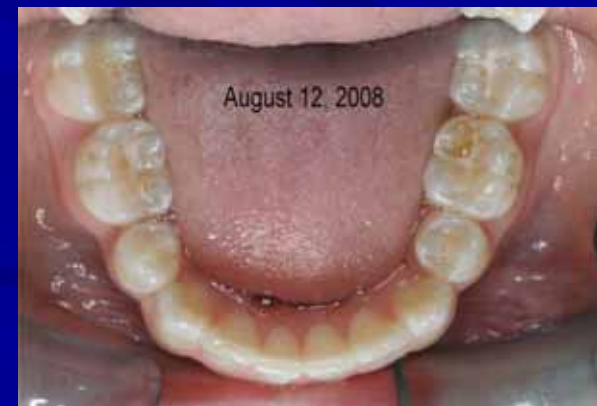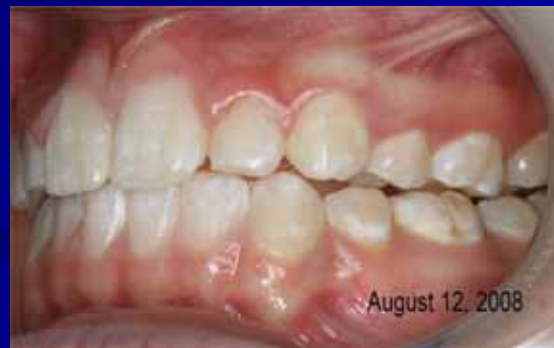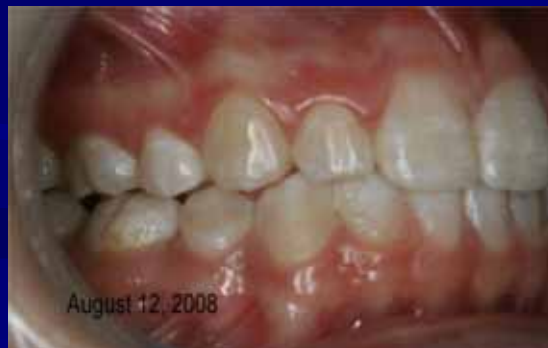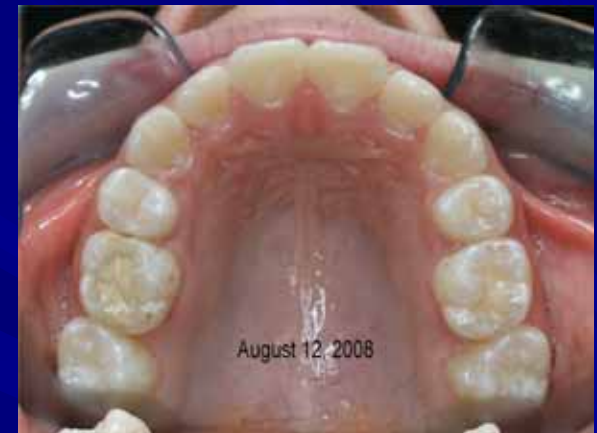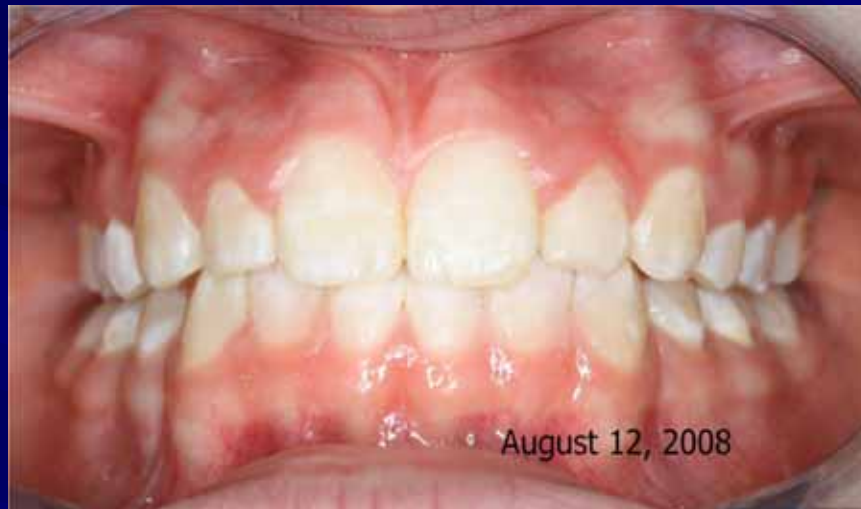Anna: 18 months active Tx



Anna: 2 months positioner retention

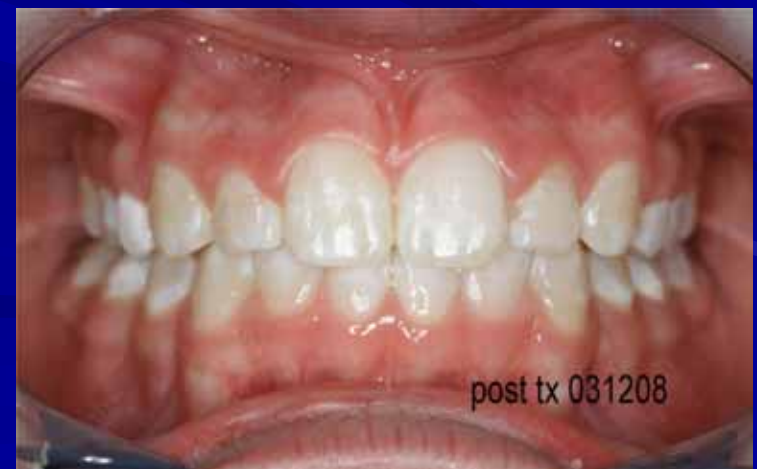

Anna: 7 months positioner retention



Anna

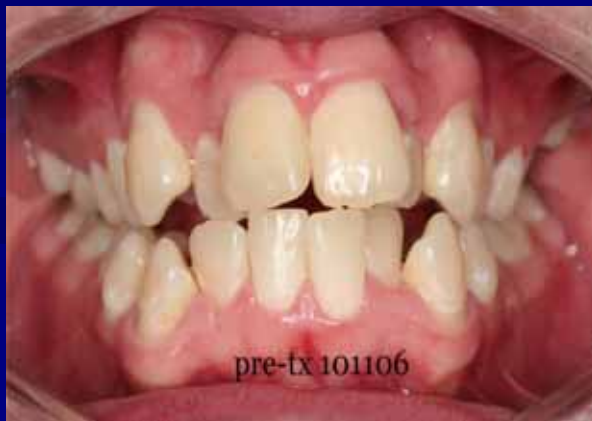- Extract Md 2nd Bicuspids
- Full brackets/tripod
- Intra oral elastics from upper 3-4's to lower 4's R/L
- 16 months removed tripods
- 7 months positioner for retention
- Upper slipcover, lower 3x3



Class III Molar Full Bracket Treatment

Class III

Ian: 22 years of age

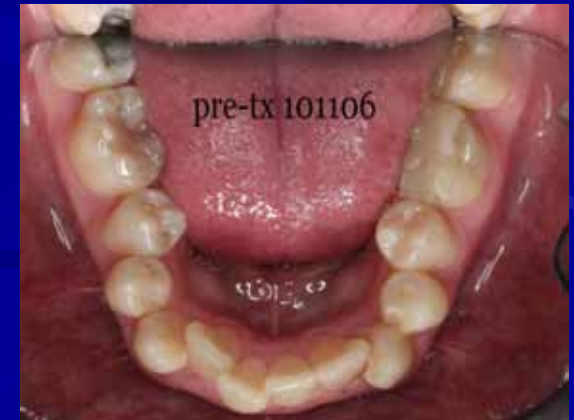
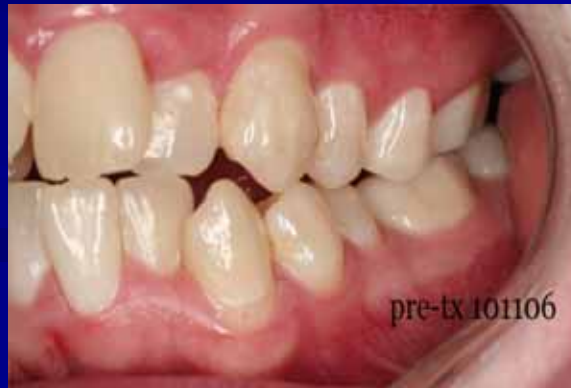
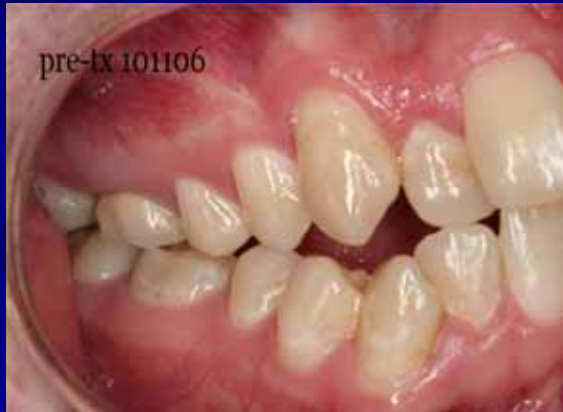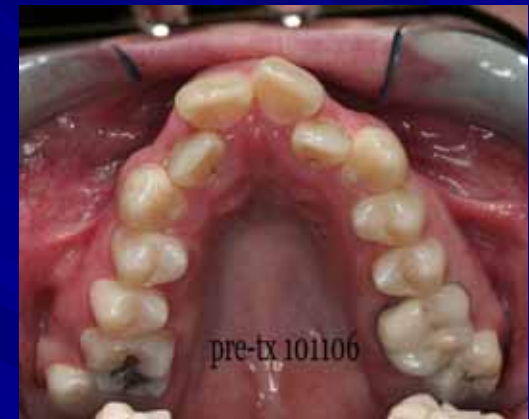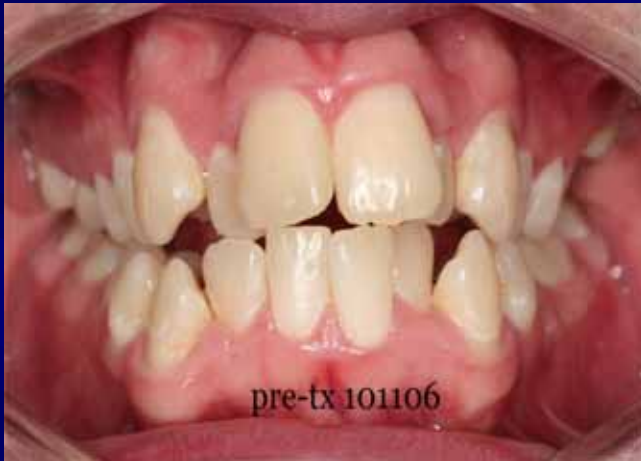- Class III ½ tooth
- Overjet 3 mm
- Overbite 0
- Class I facial profile
- Headaches 2-3x week
- Concern: Crowding

Class III

Ian: 22 years of age

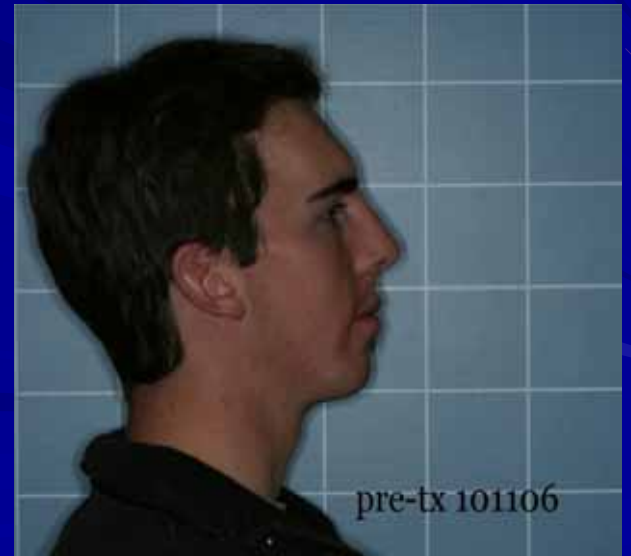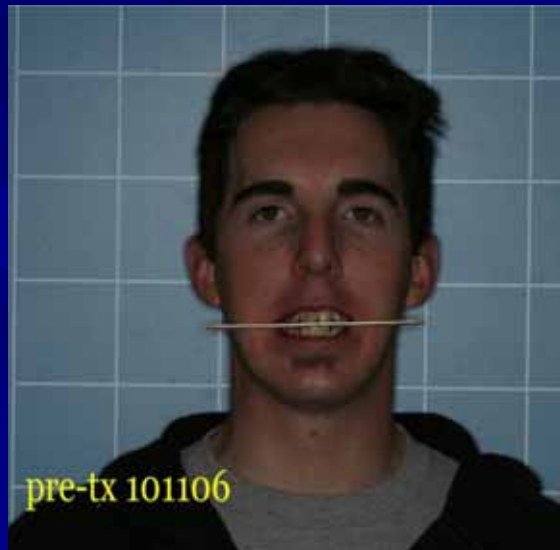
Pre-treatment



Class III

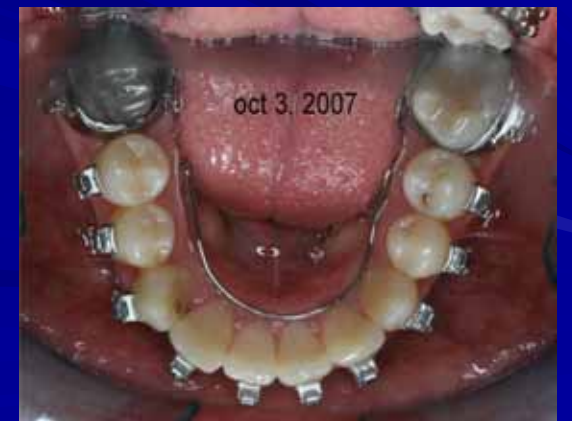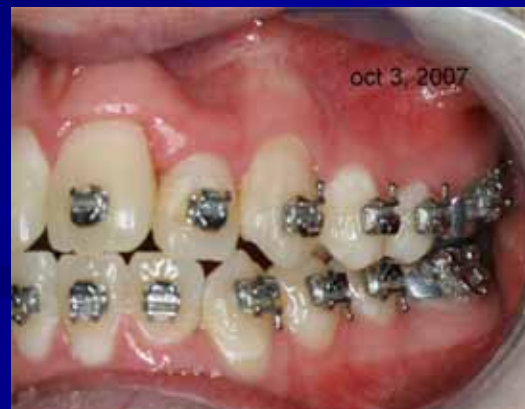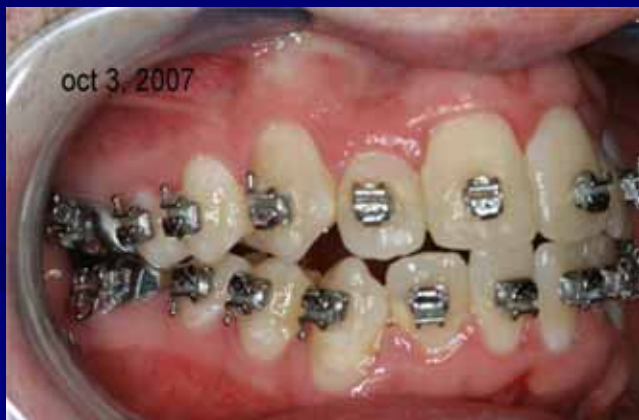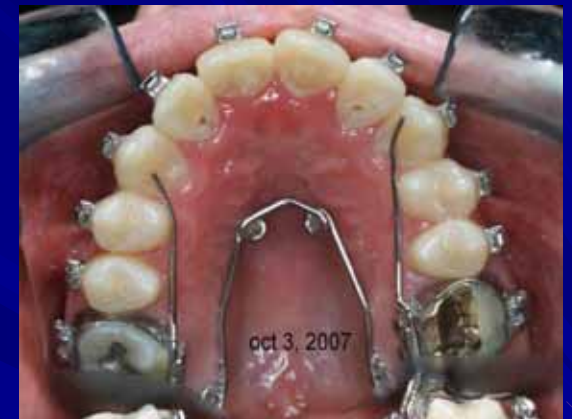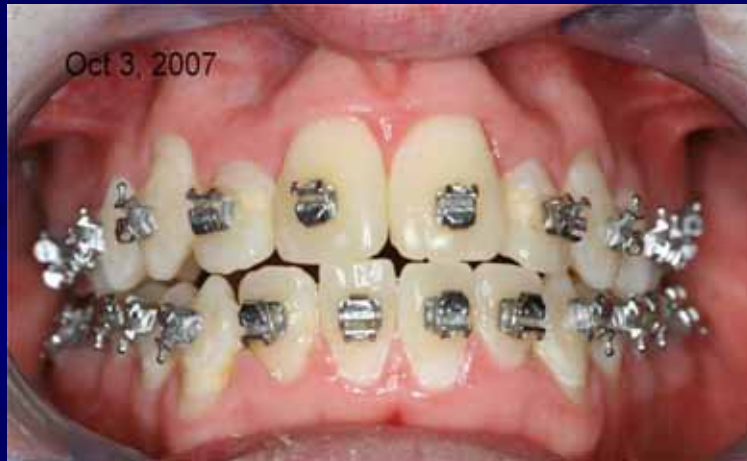Ian: 22 years of age

Pre-treatment

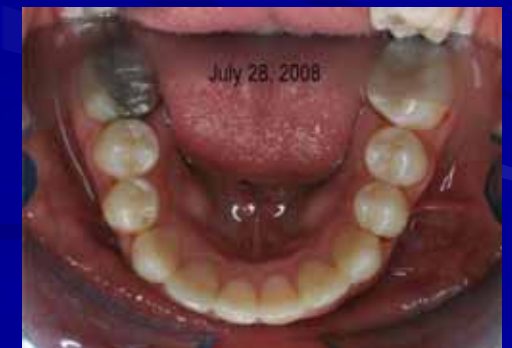
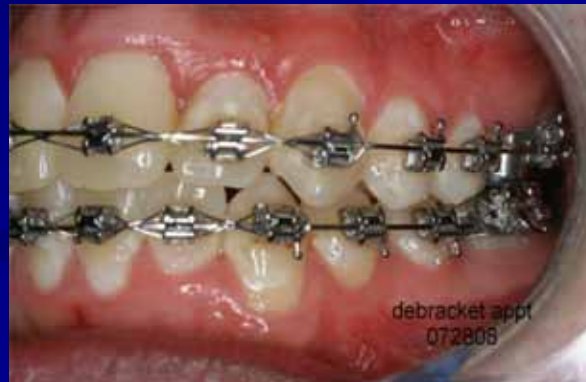
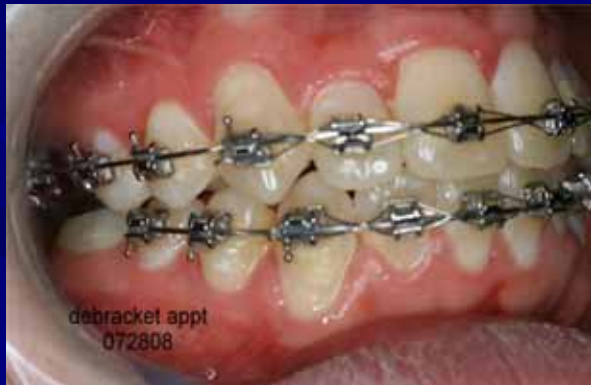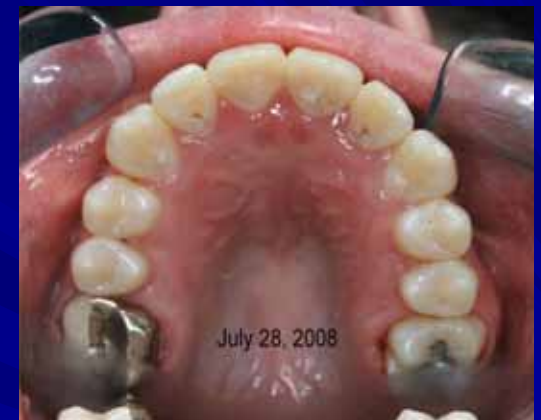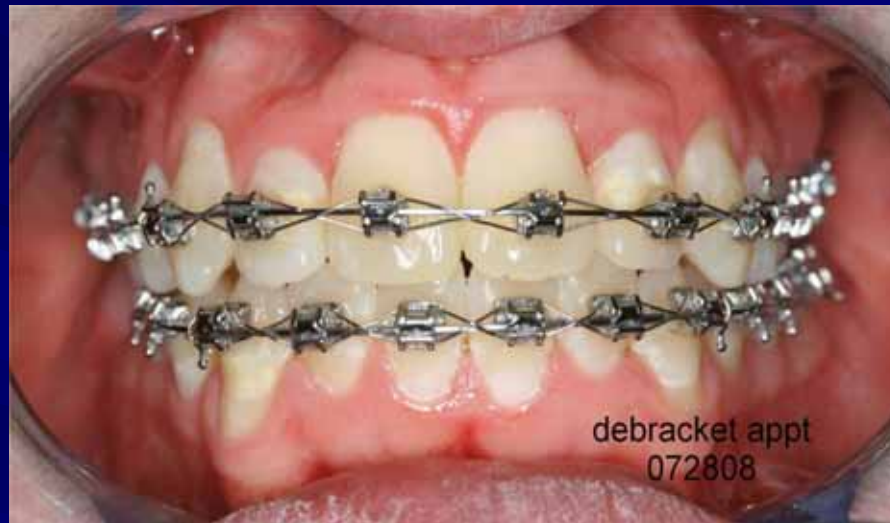Ian: 6 months of treatment

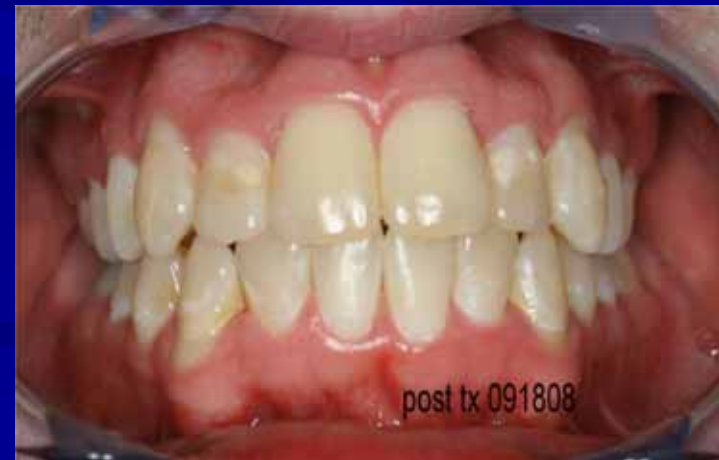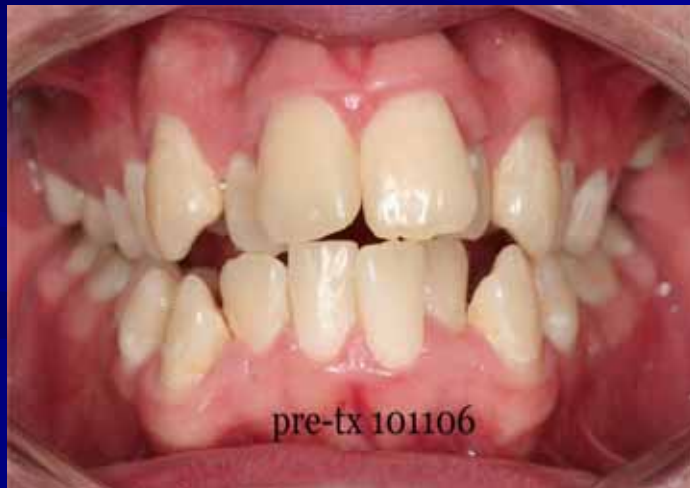Full brackets



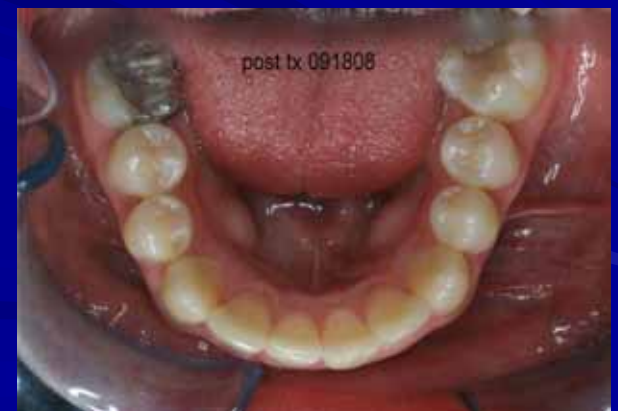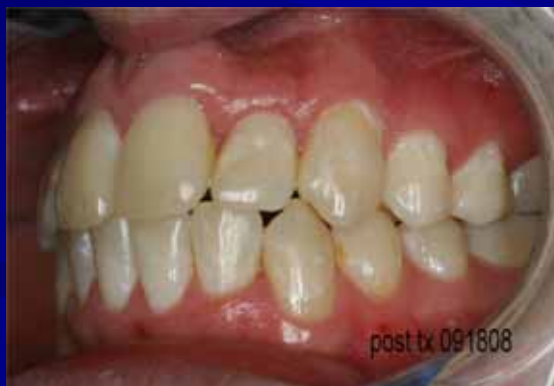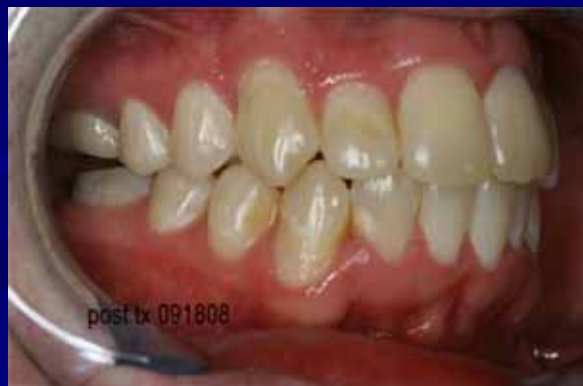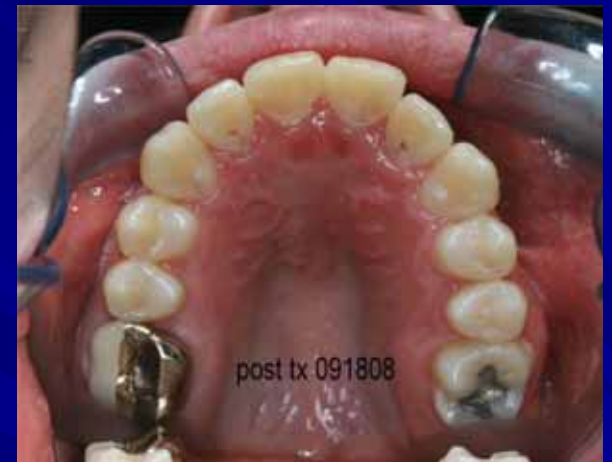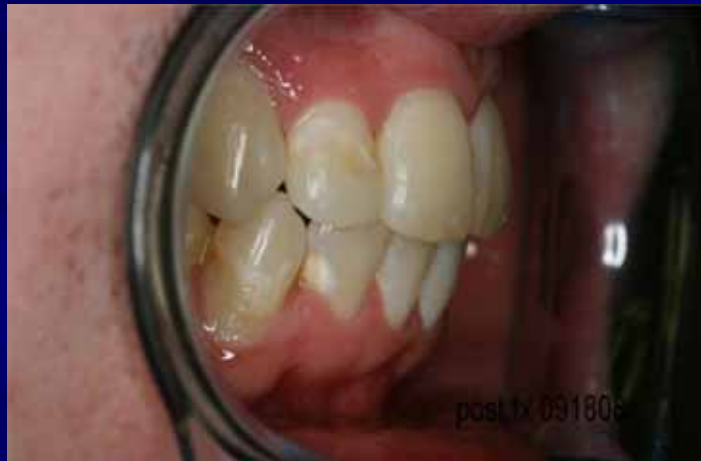Ian: 15 months full brackets Tx



Ian: 15 months active treatment

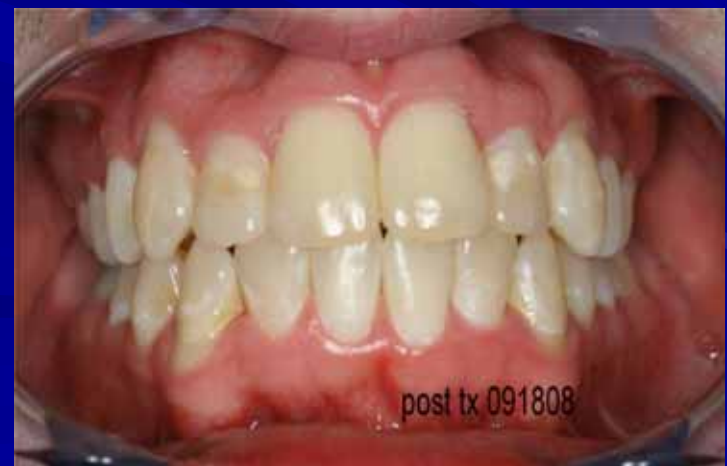

Ian: Post treatment



Ian

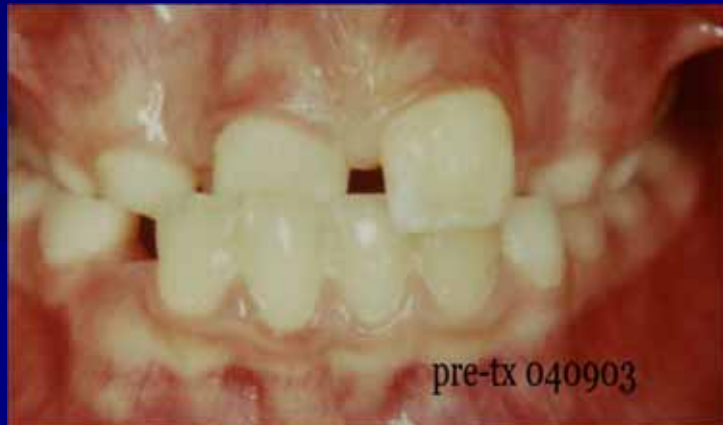- Full brackets
- Upper Quad Helix
- Lower removable holding arch
- 9 months removed Quad
- Positioner for retention 3 months
- Upper & lower bonded 3x3's



Class III Molar Facemask Treatment

Class III

Jana: 8 years of age

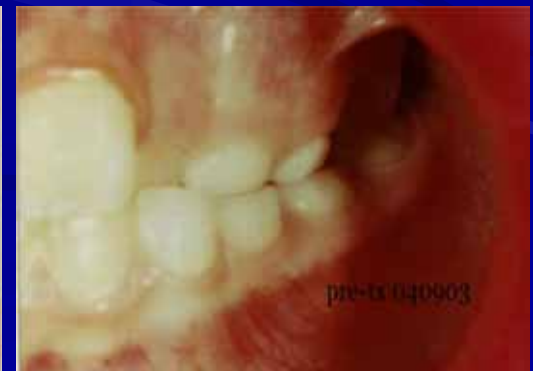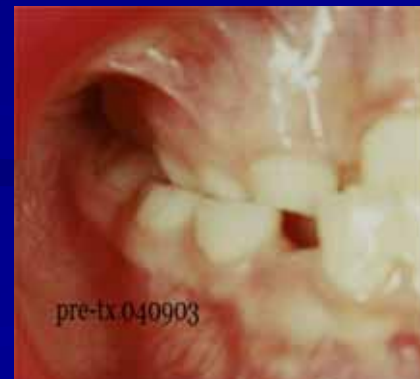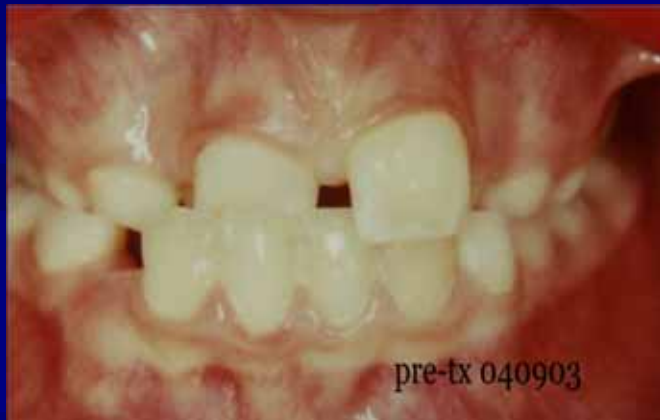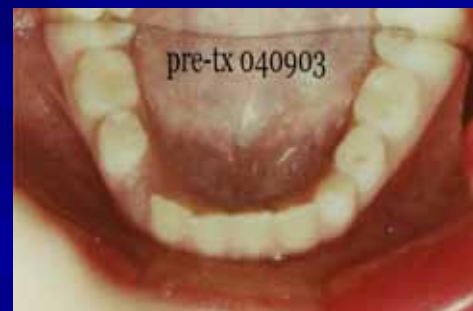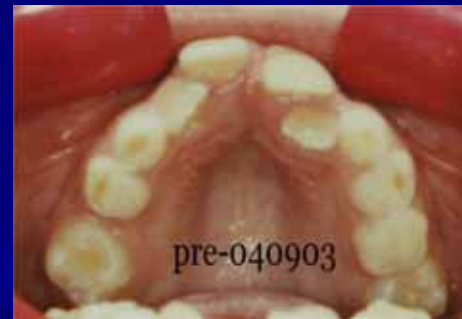



- Overjet 1mm
- Overbite 20%
- Anterior crossbite
- Mid face deficiency
- Class III facial profile
- Concern:
Anterior crossbite

Class III

Jana: 8 years of age

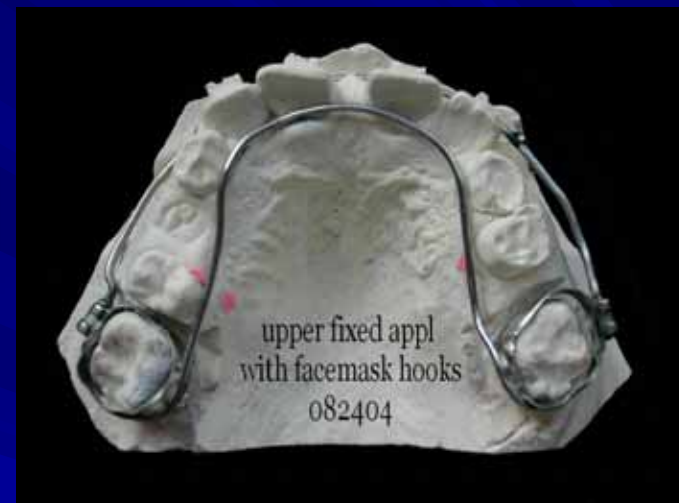
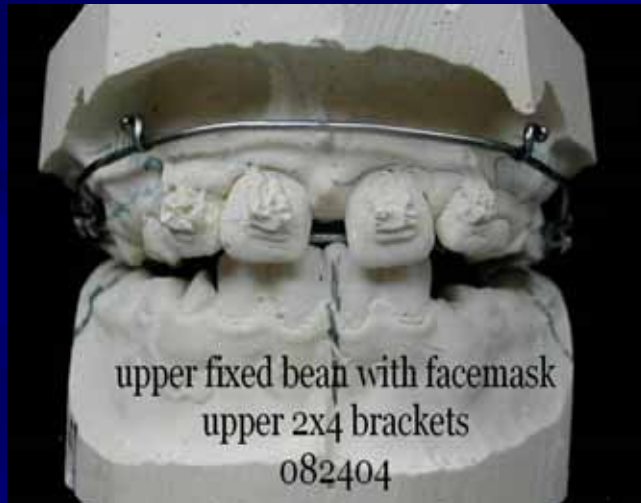Pre-treatment



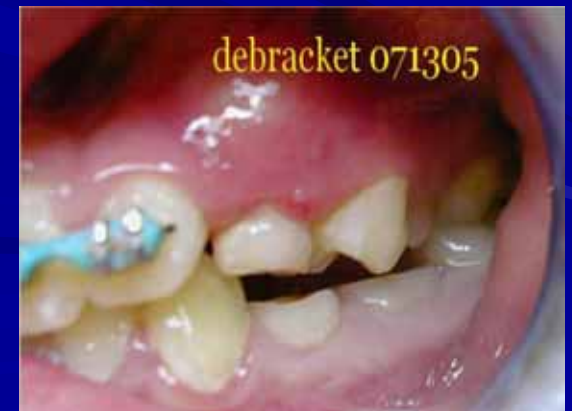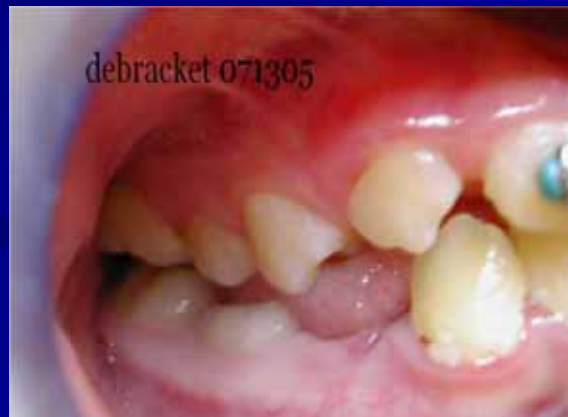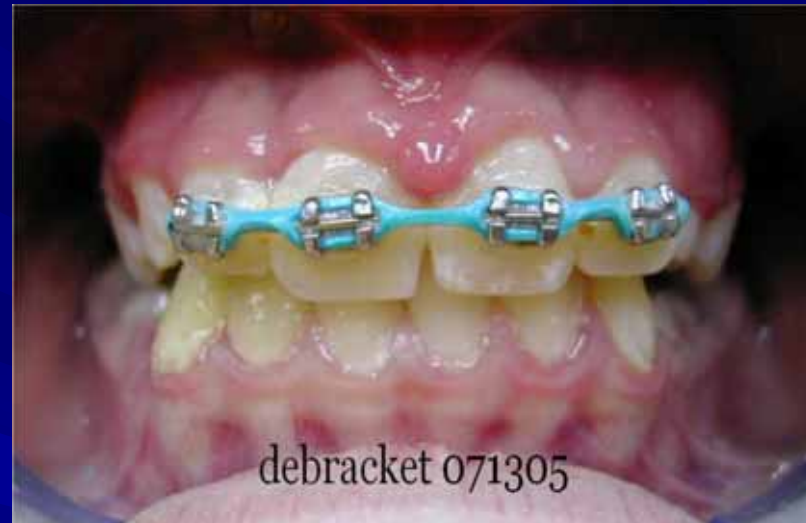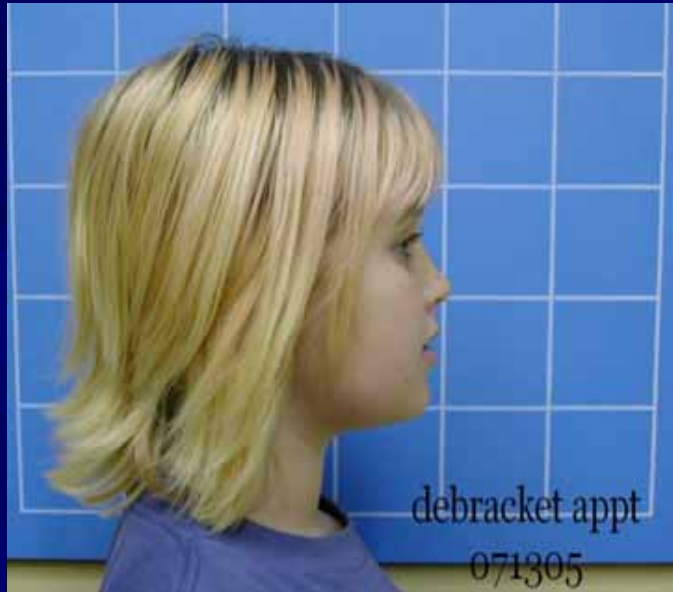Jana: Pre-treatment study models



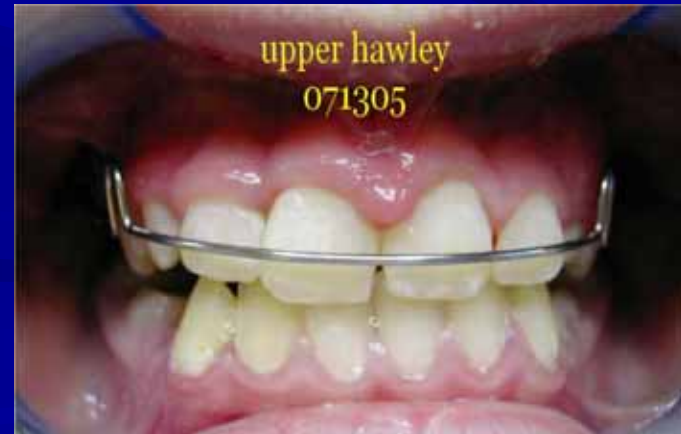
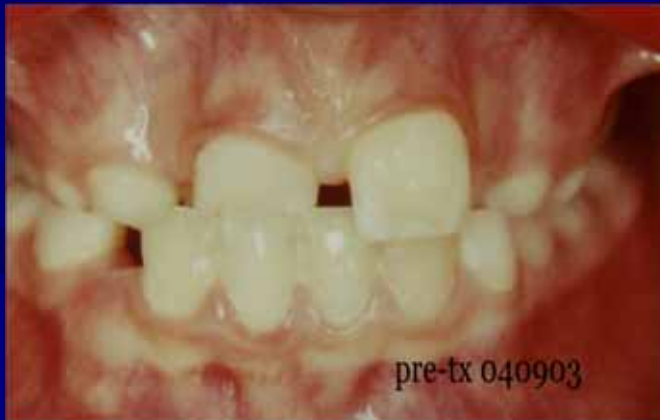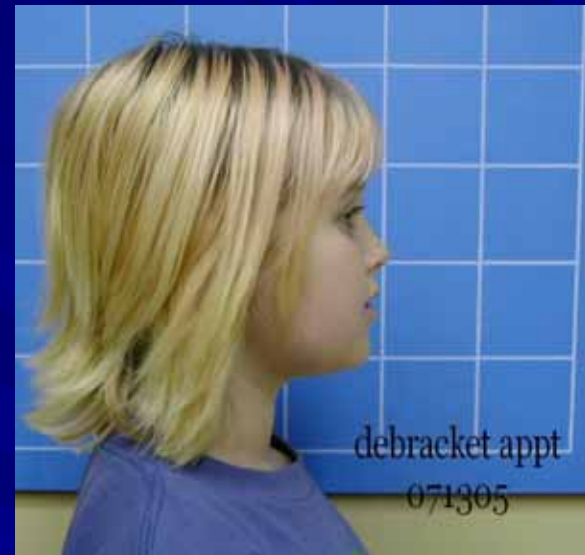Jana: Post upper 2nd Sagittal Pre upper Bean appliance with sectional brackets



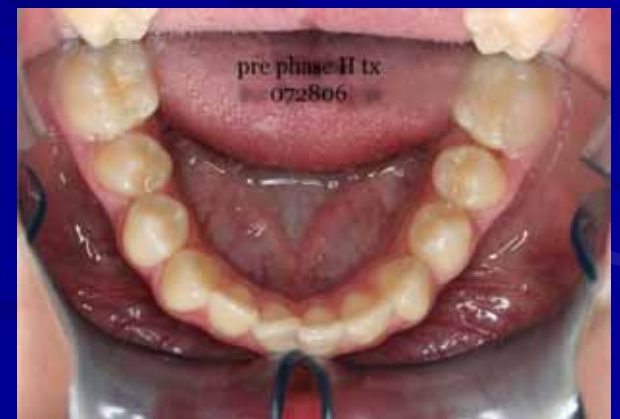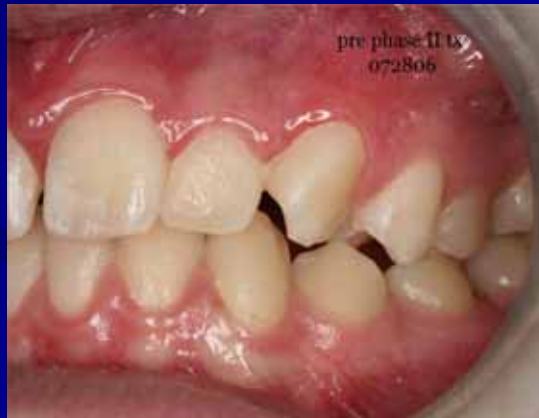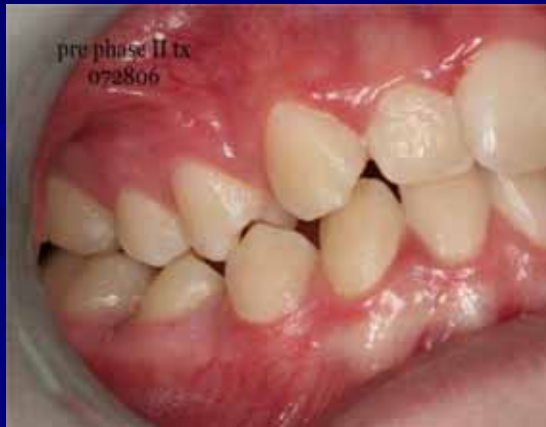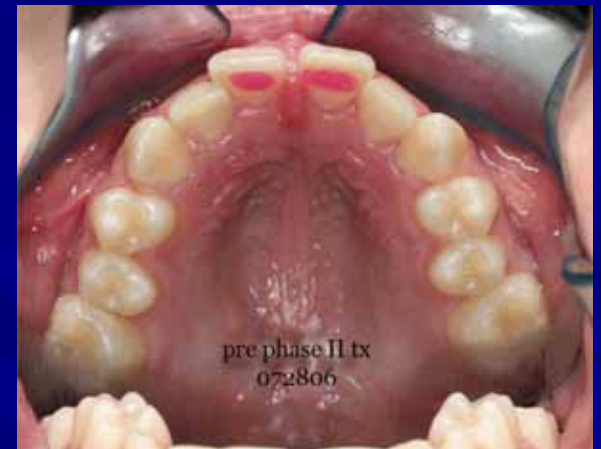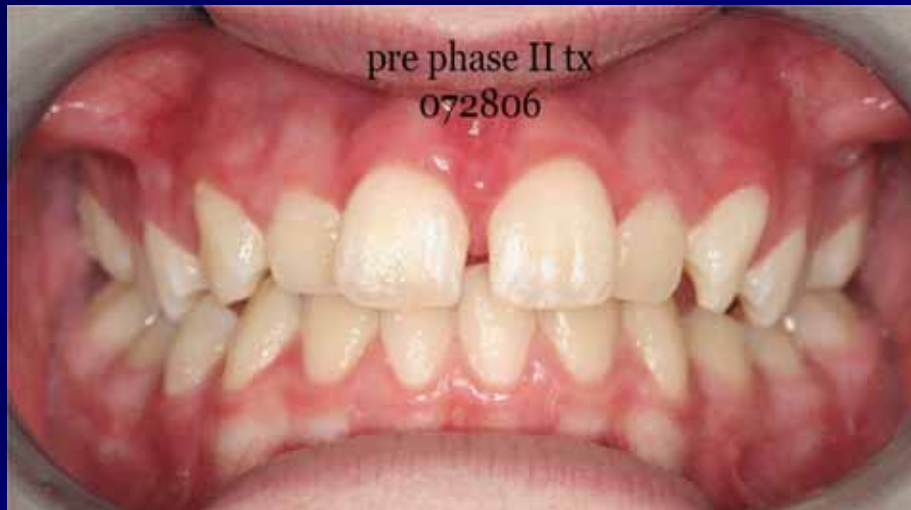Jana: Sectional brackets/Facemask Tx 12 months



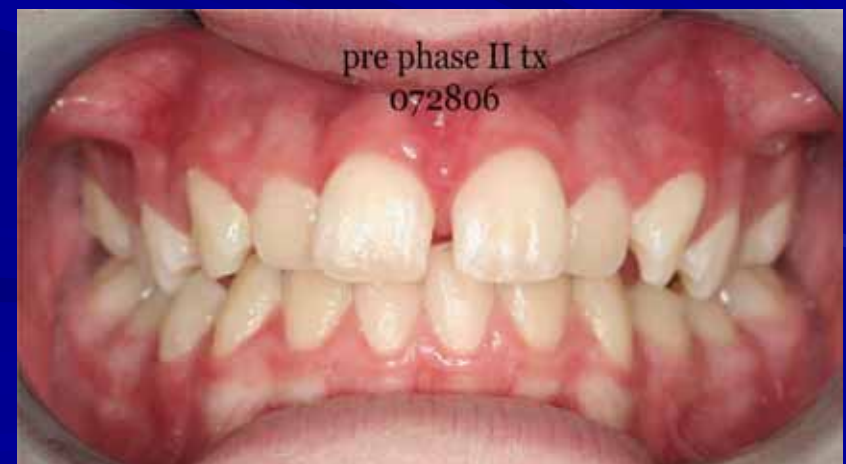
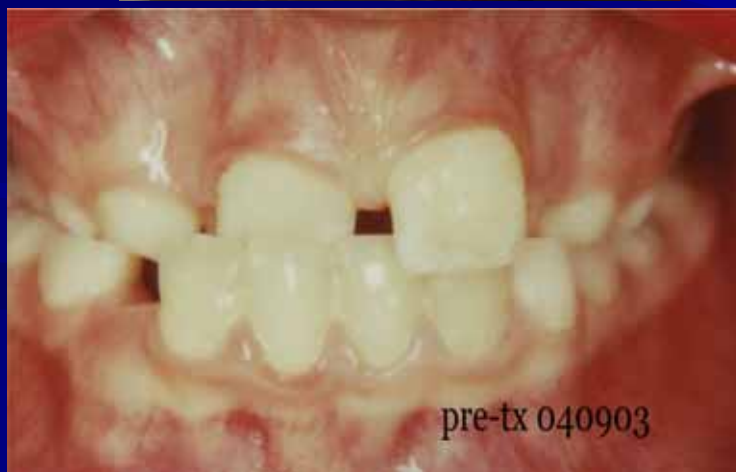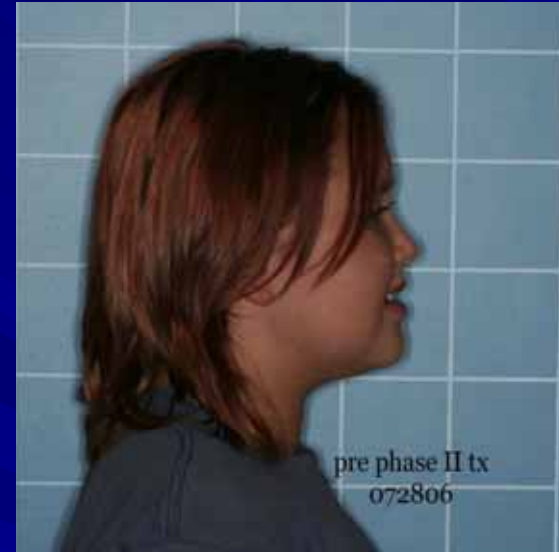Jana: Pre & Post Phase I Tx 26 months



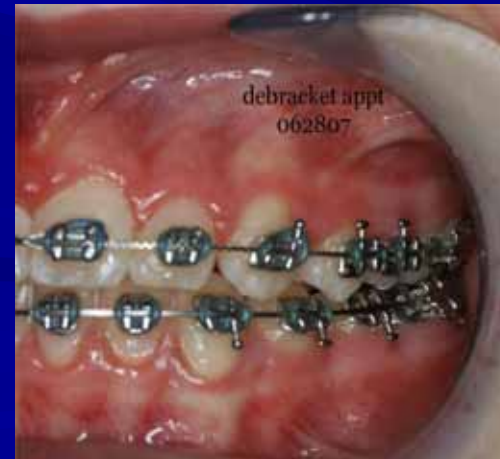
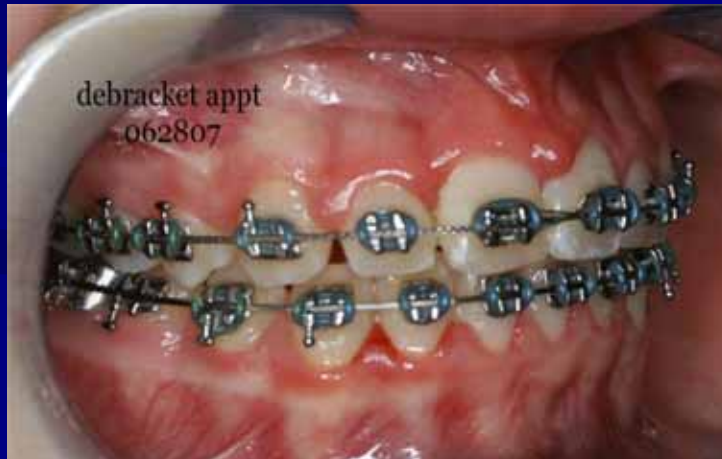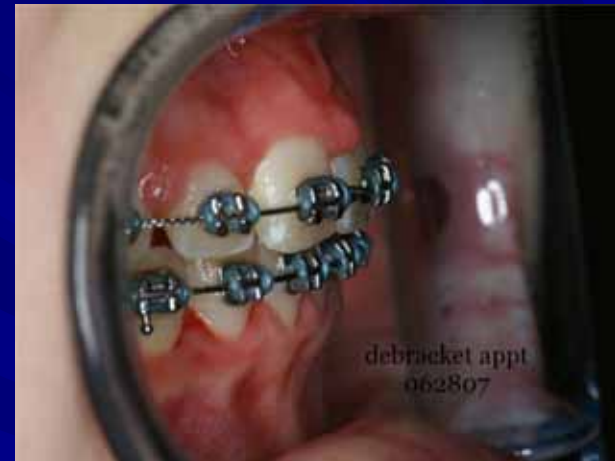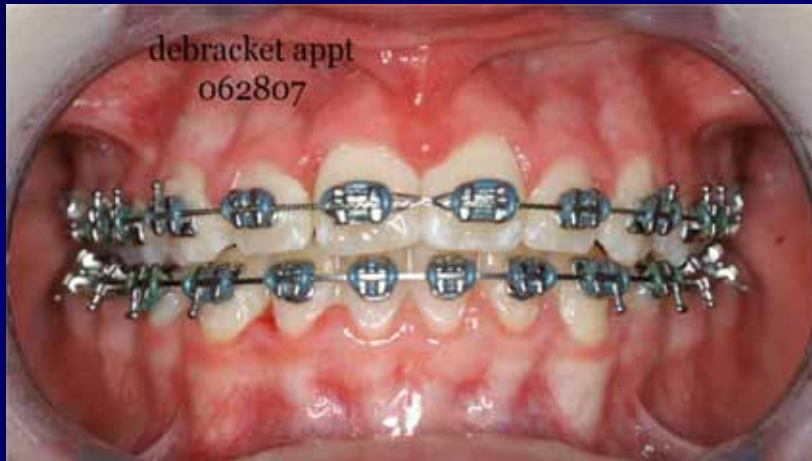Jana: Pre Phase II Tx



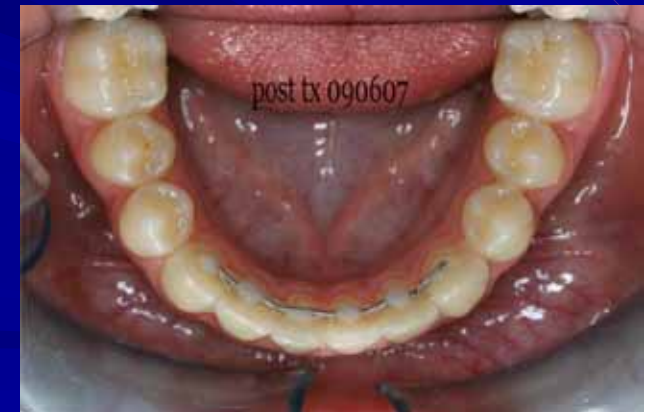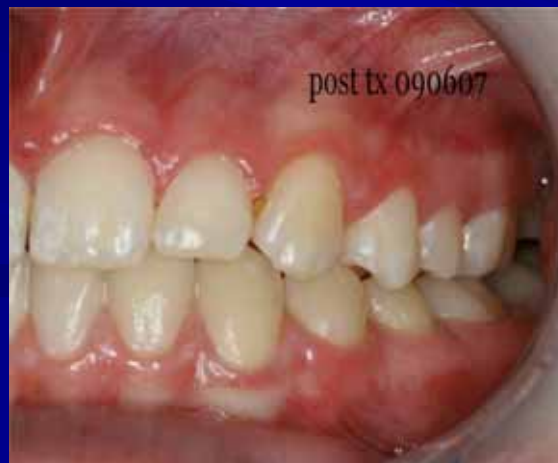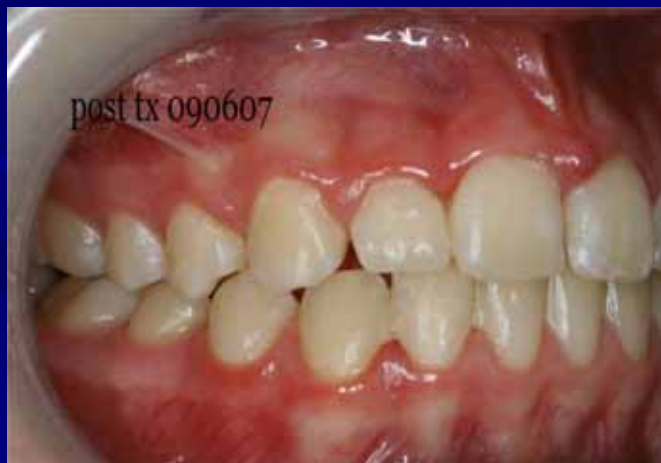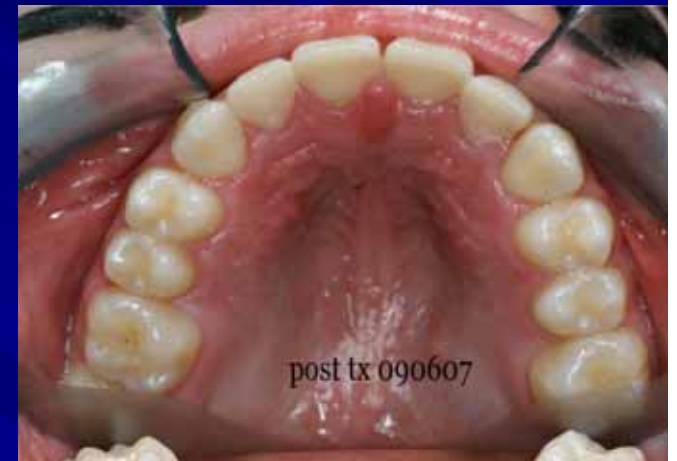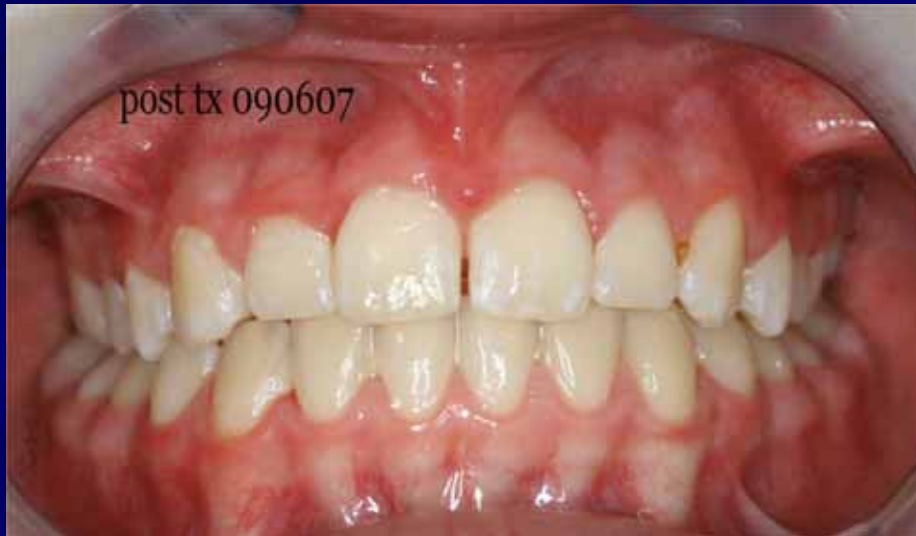Jana: Pre Phase I & II 39 months



Jana: 9 months full bracket Tx

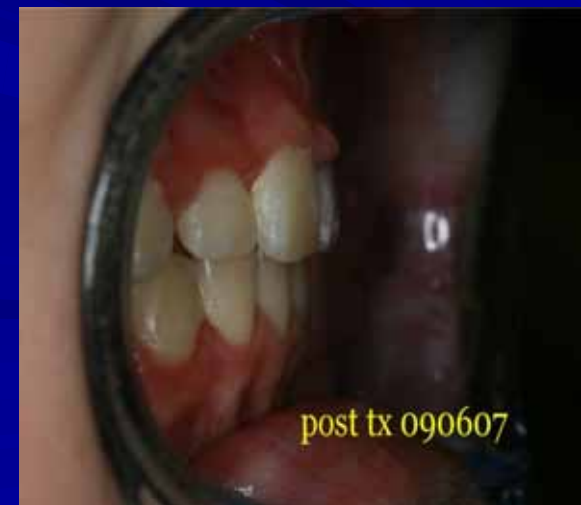

Jana: Post Tx



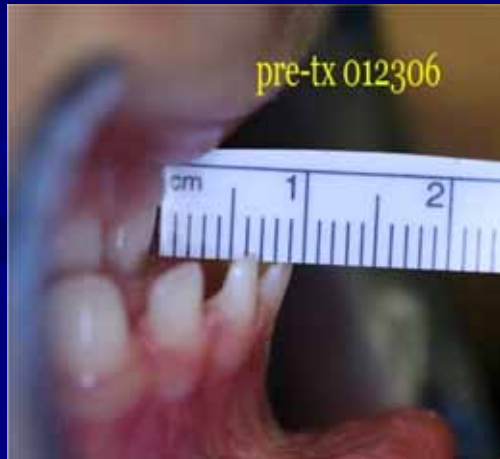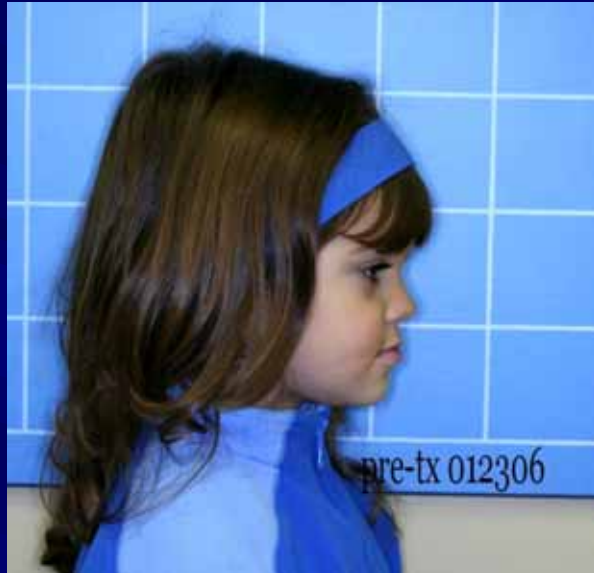Jana

- Upper 3-way Sagittal 6 months
- 2nd Sagittal with facemask
hooks/facemask 8 months
- Upper fixed Bean/sectional brackets
with facemask 12 months
- Removed Bean appliance at
11 months
- De-bracket/Hawley for retention
- 2 months lost Hawley replaced with
Wilson's holding arch 12 months
- Phase II treatment full brackets
9 months
- Presently upper Hawley/lower 3x3
for retention



Class III

Lauren: 4 years of age

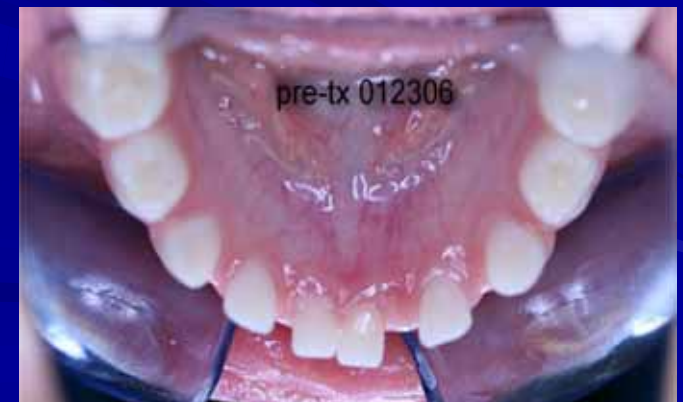
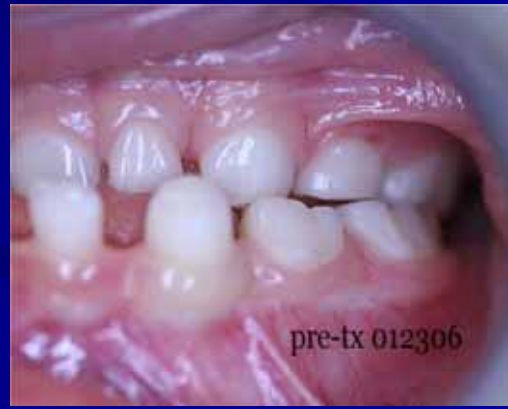
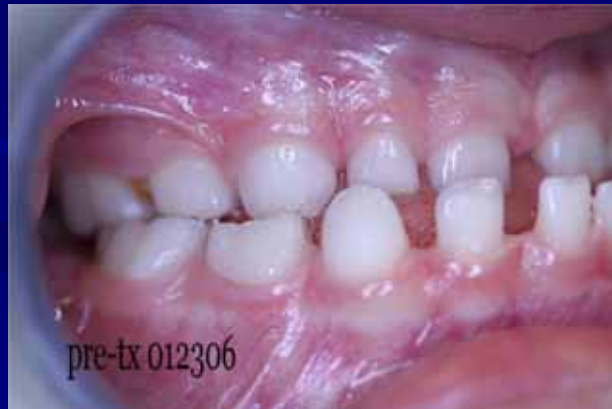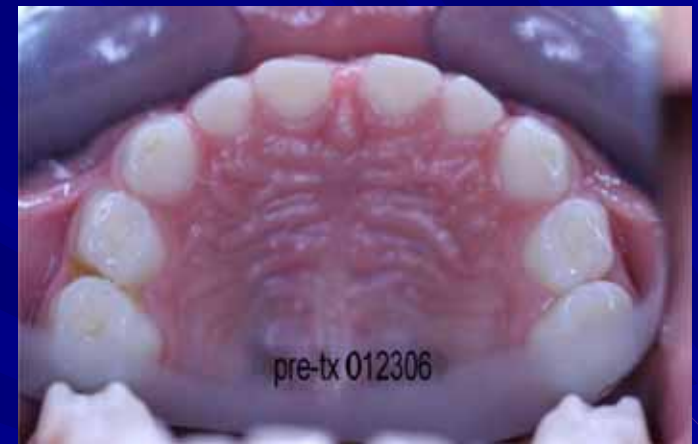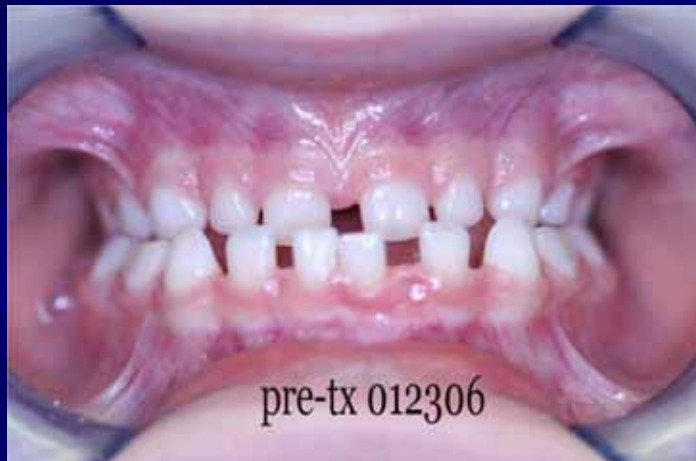- Class III molar
- Overjet -6mm
- Overbite -50%
- Midface Deficient
- Lip sucking habit
- Concerns: Mid face, neck aches, reverse overbite

Class III

Lauren: 4 years of age

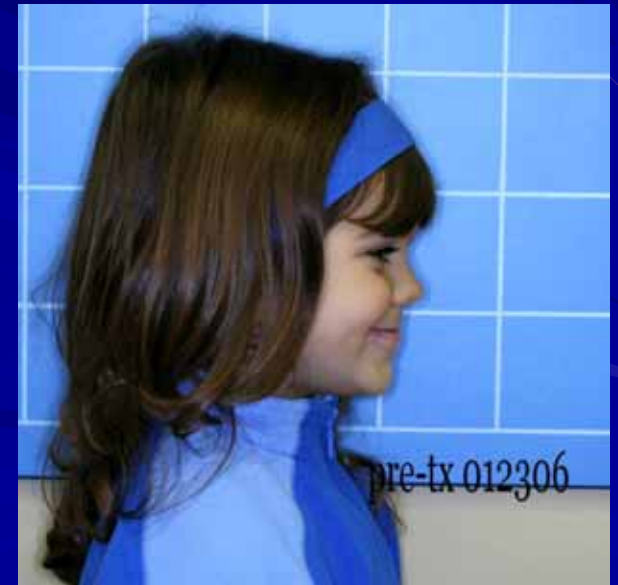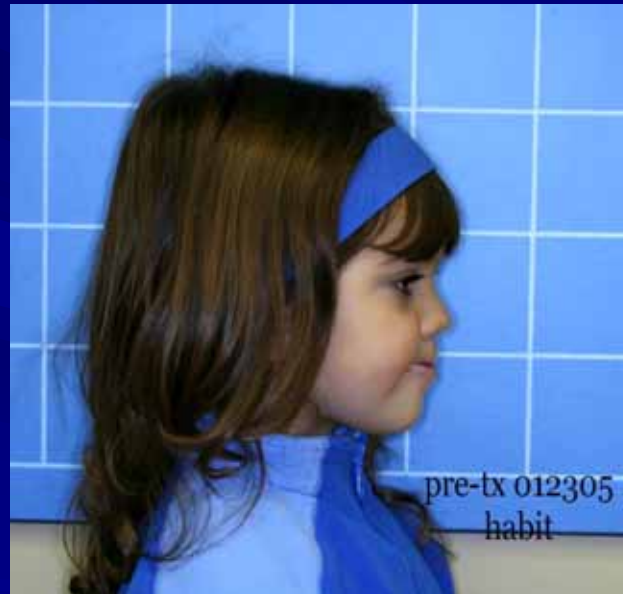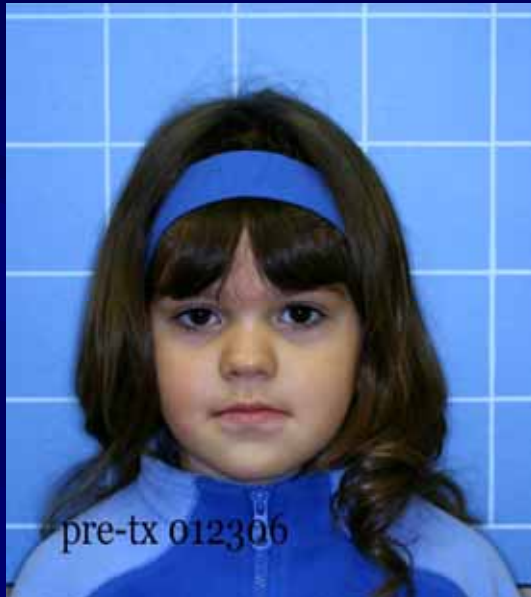Pre-treatment



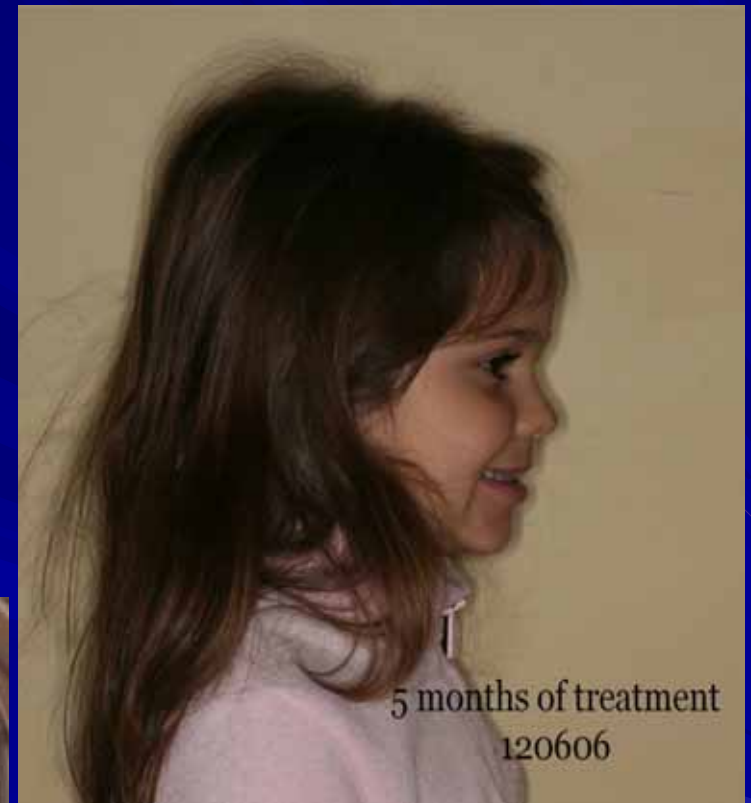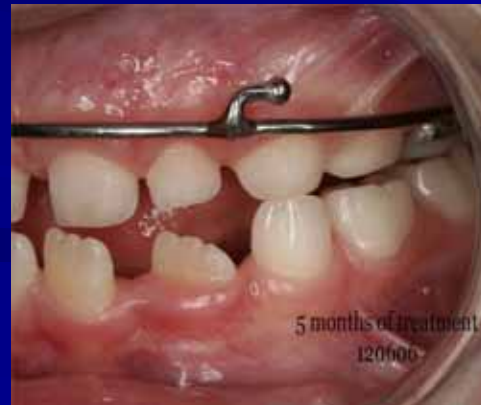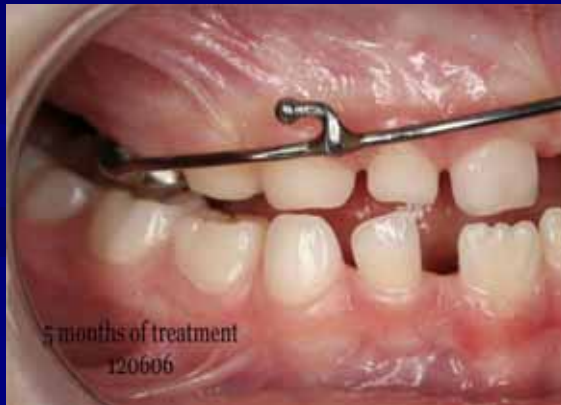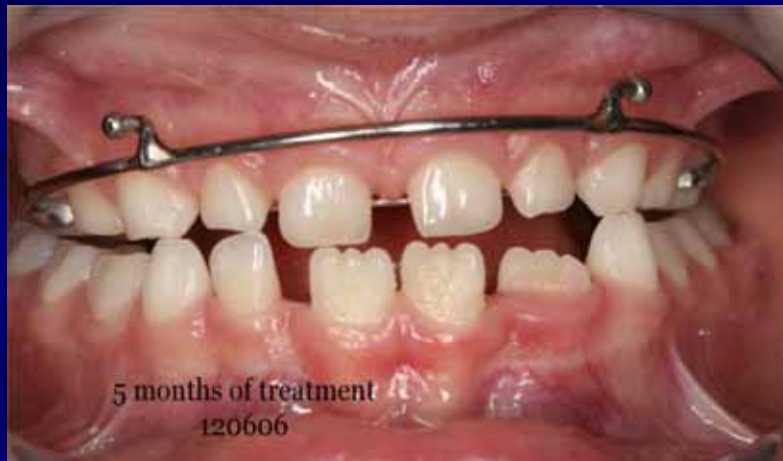Class III

Lauren: 4 years of age

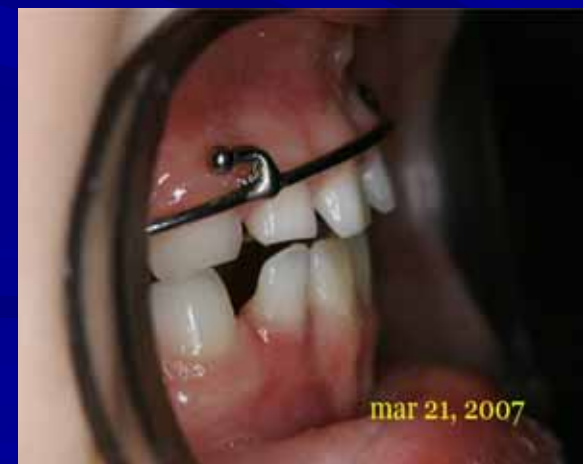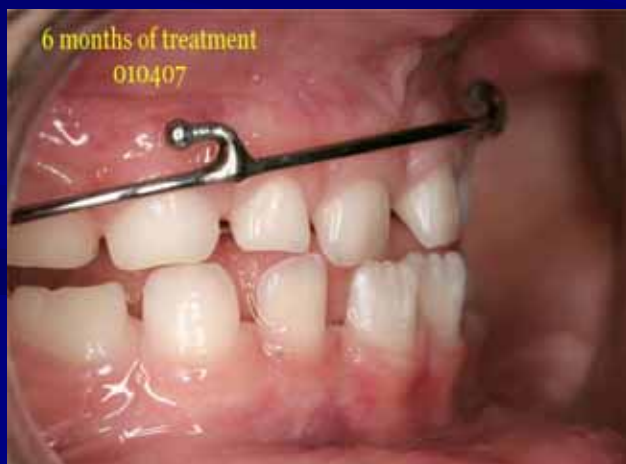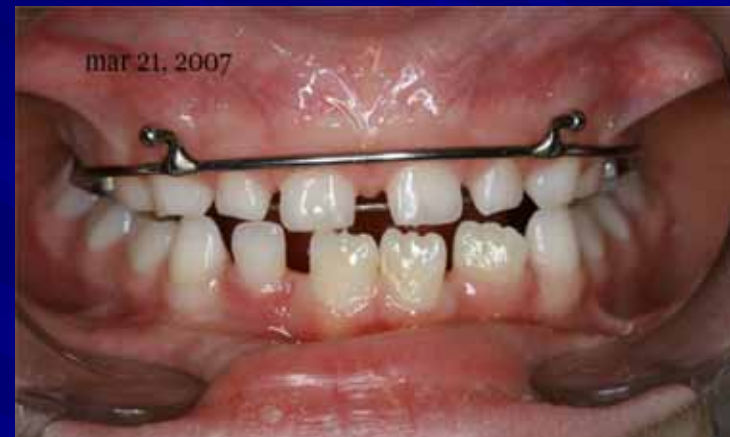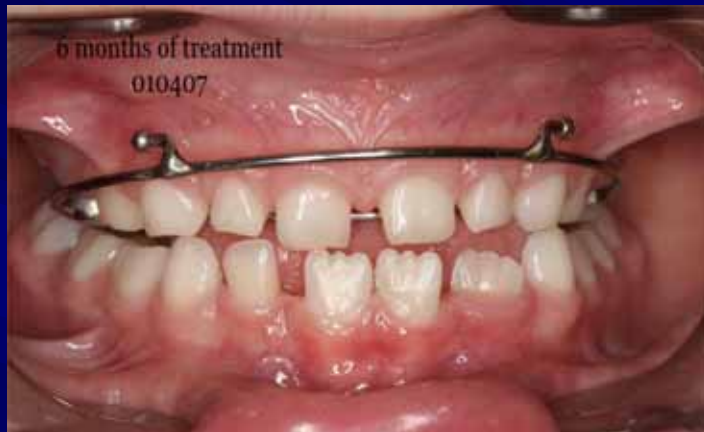Pre-treatment



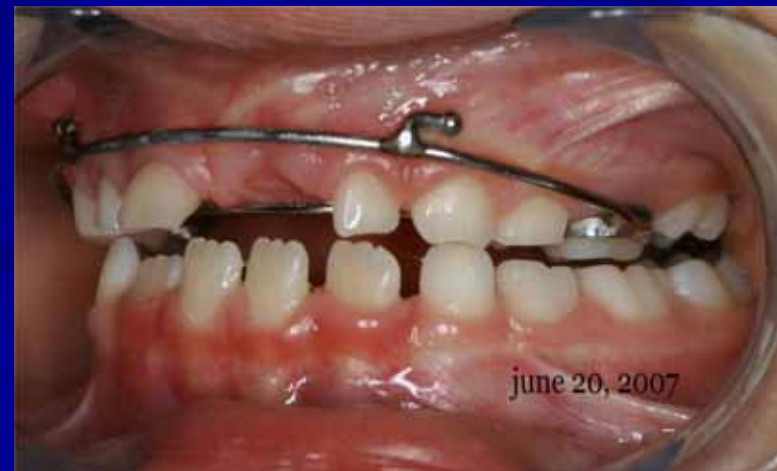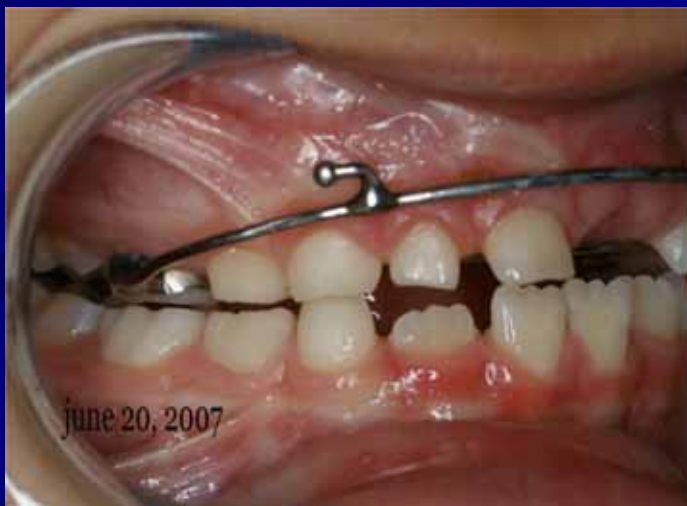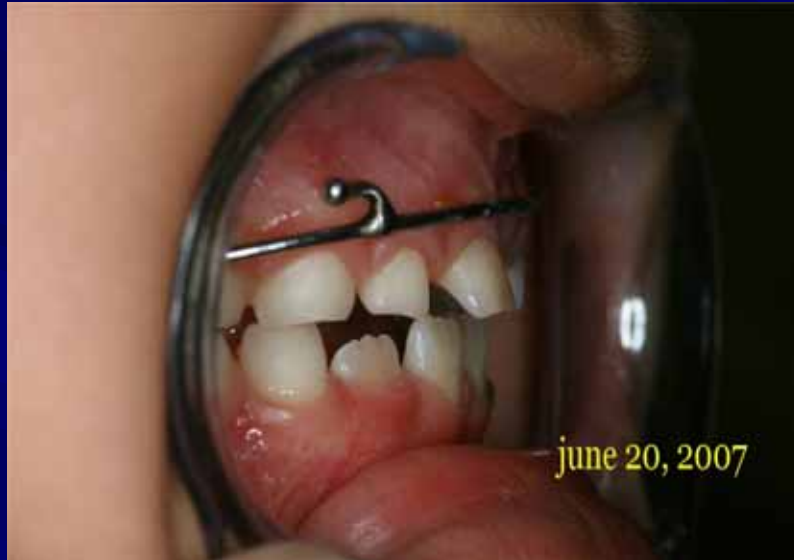Lauren: Upper fixed Bean at 5 months



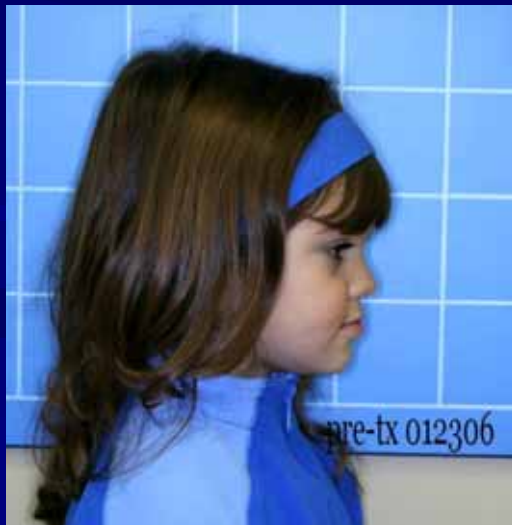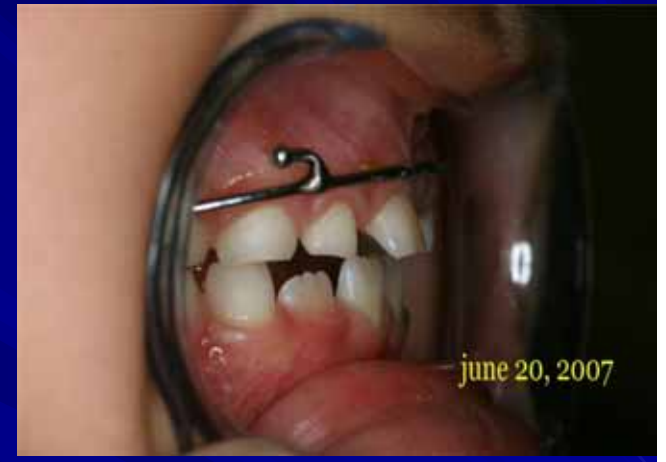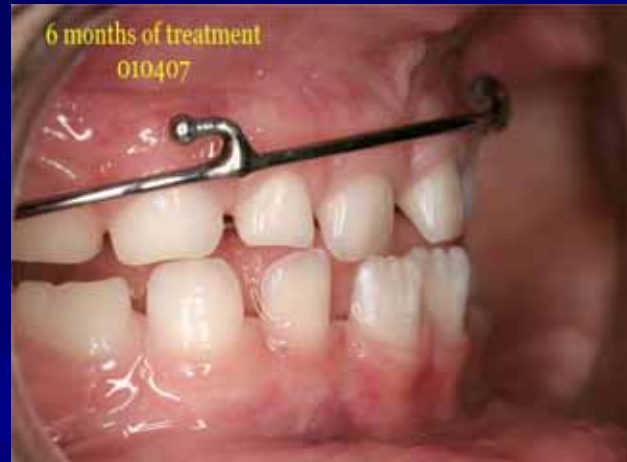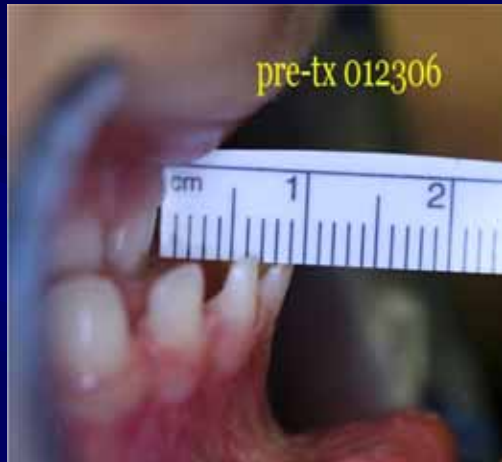Lauren: 6 & 8 months of active Tx



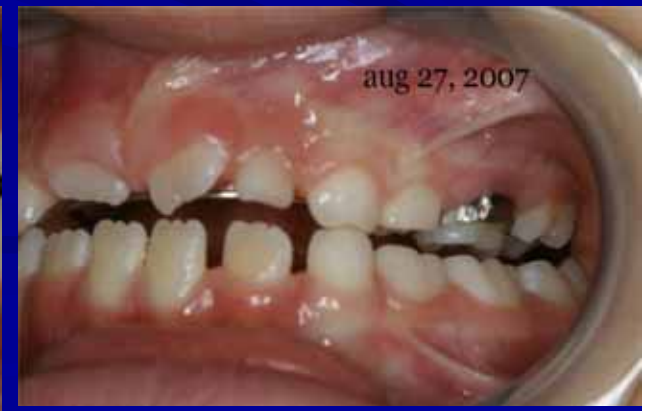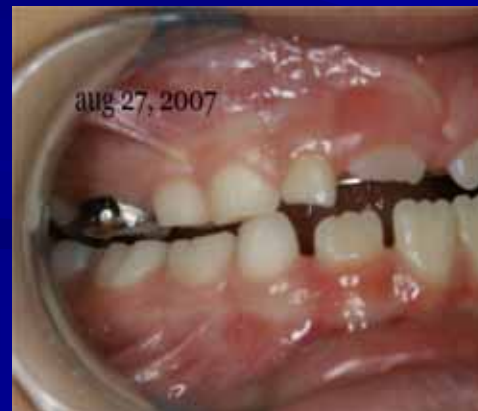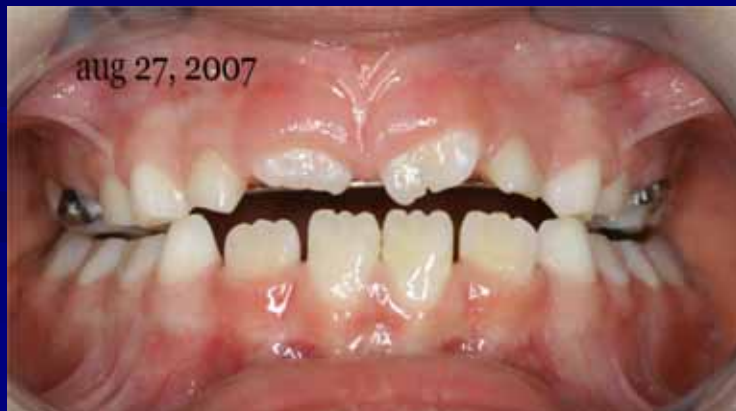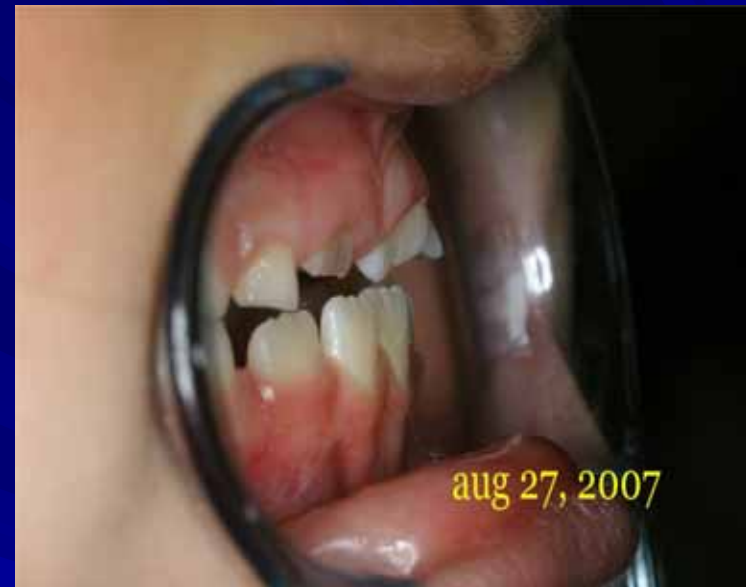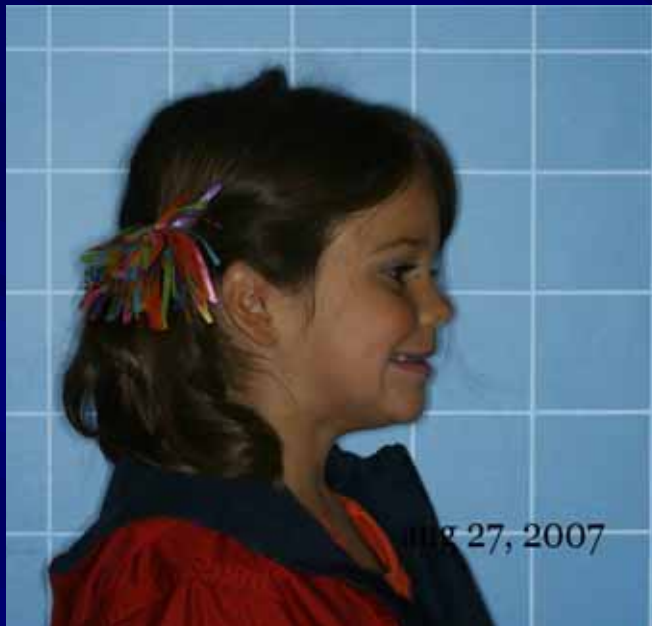Lauren: Holding phase at 12 months



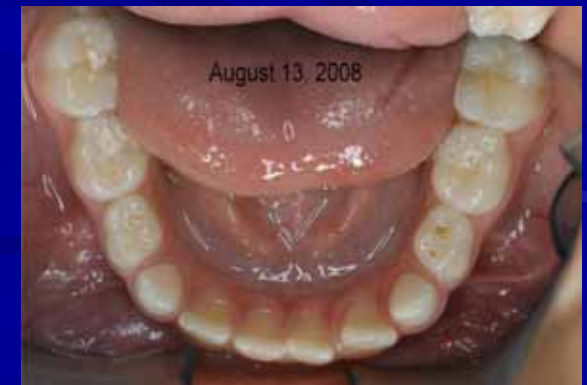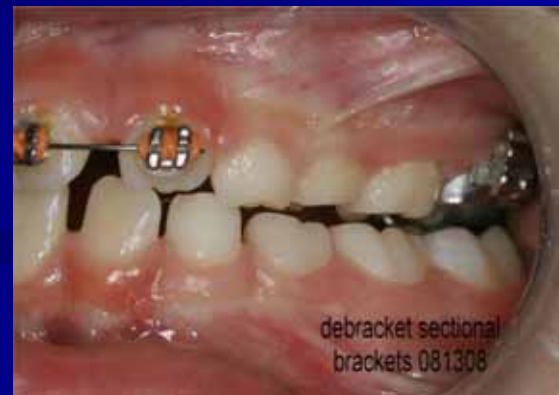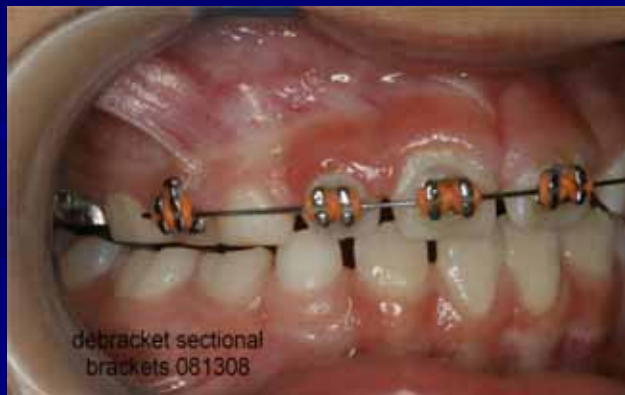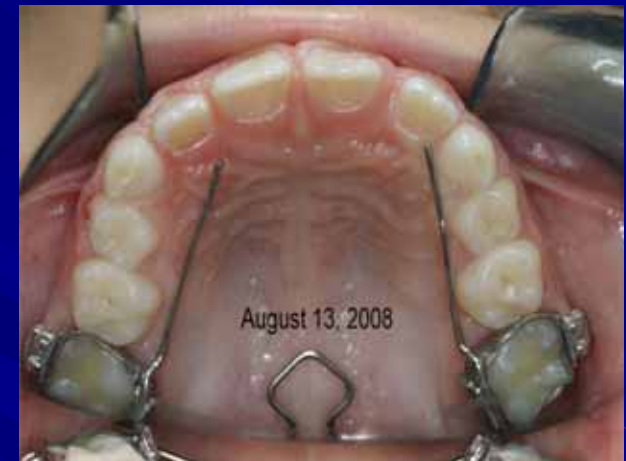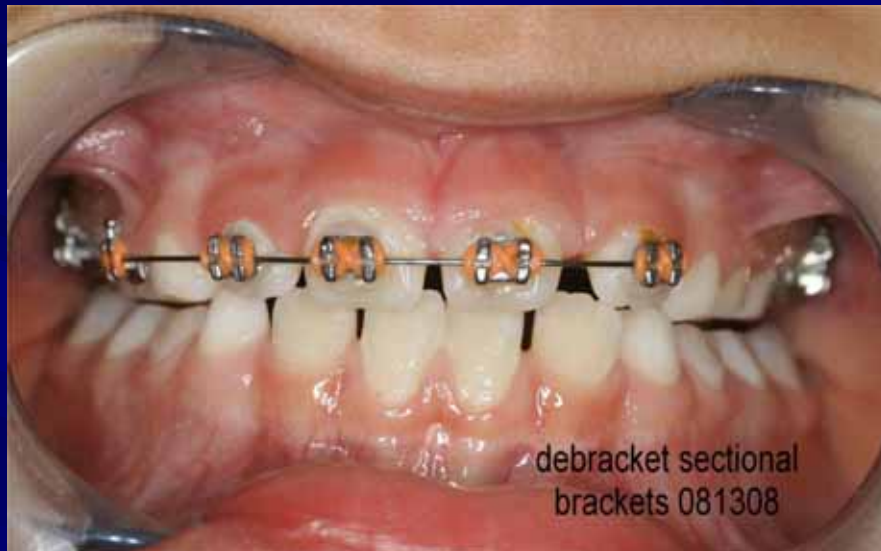Lauren: Pre & Mid treatment



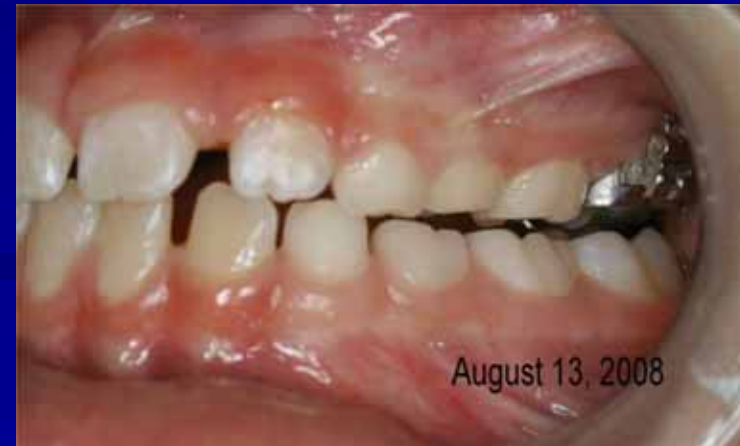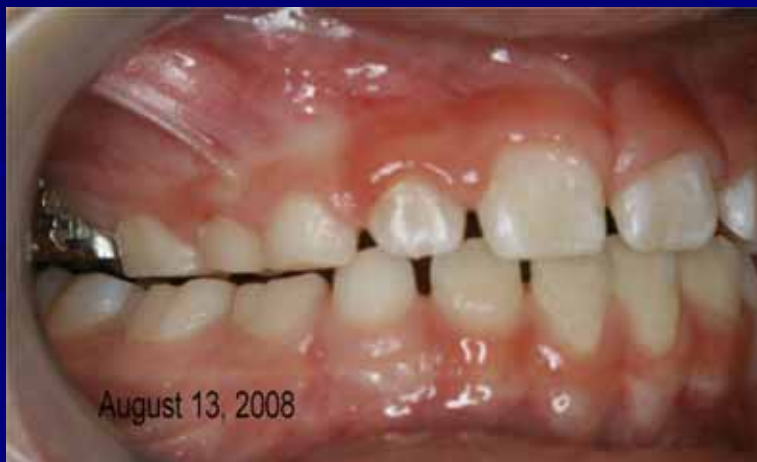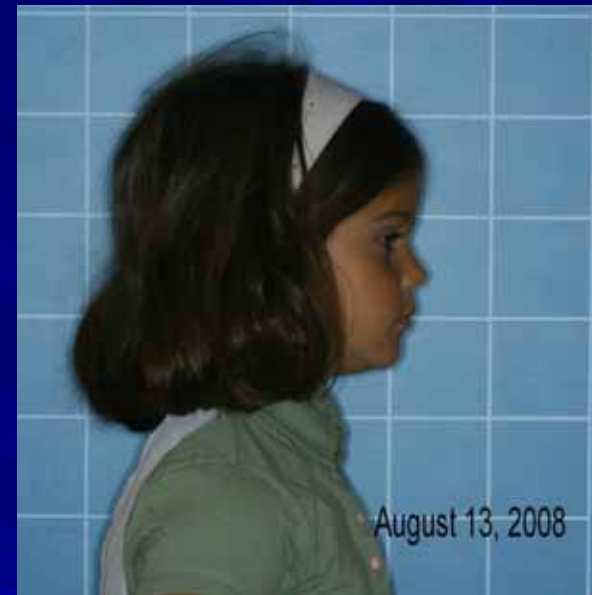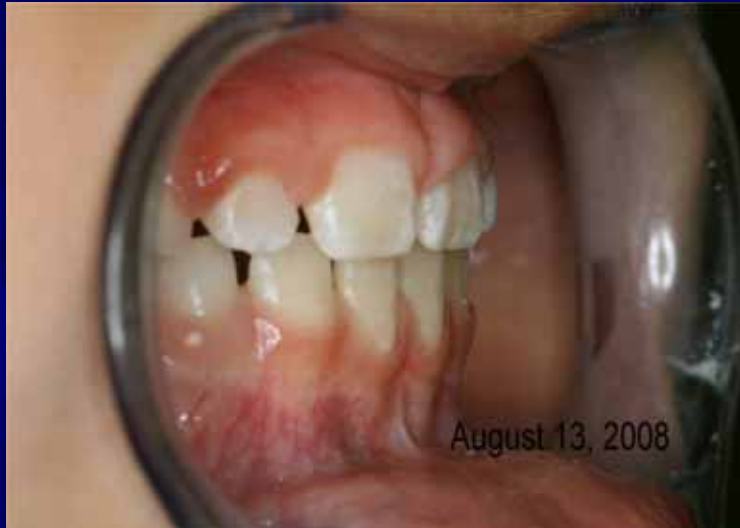Lauren



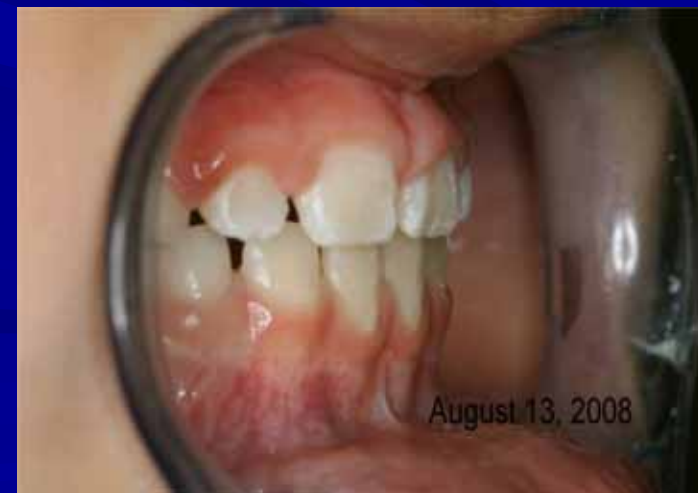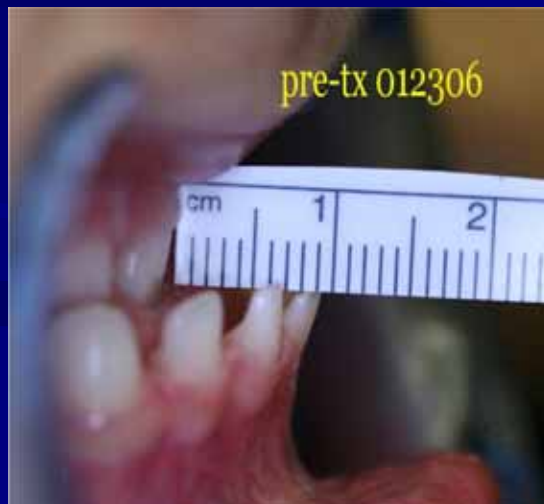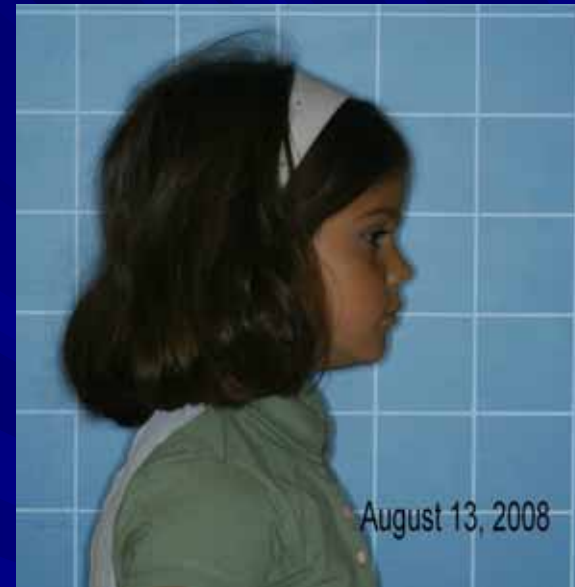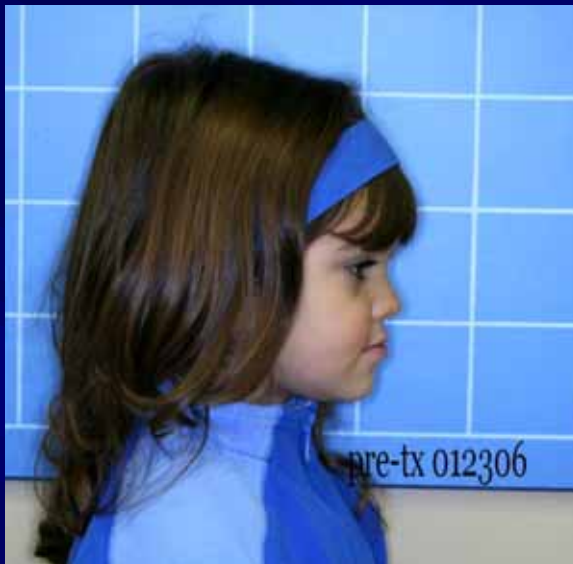Lauren: 3 months sectional bracket Tx



Lauren: Post Phase I Tx

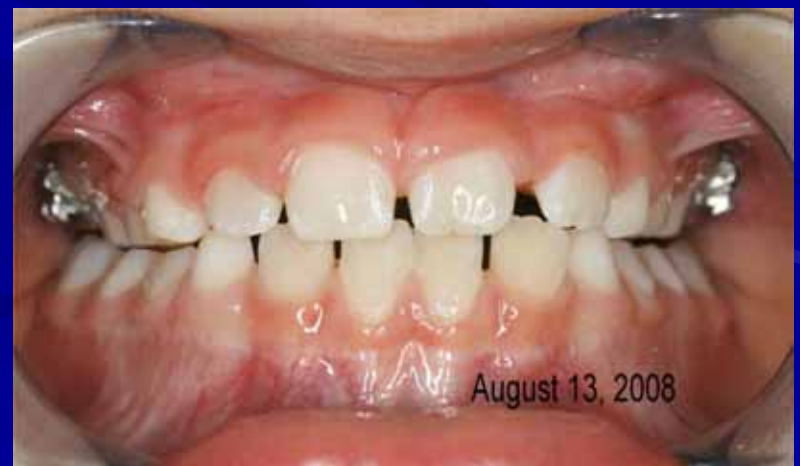
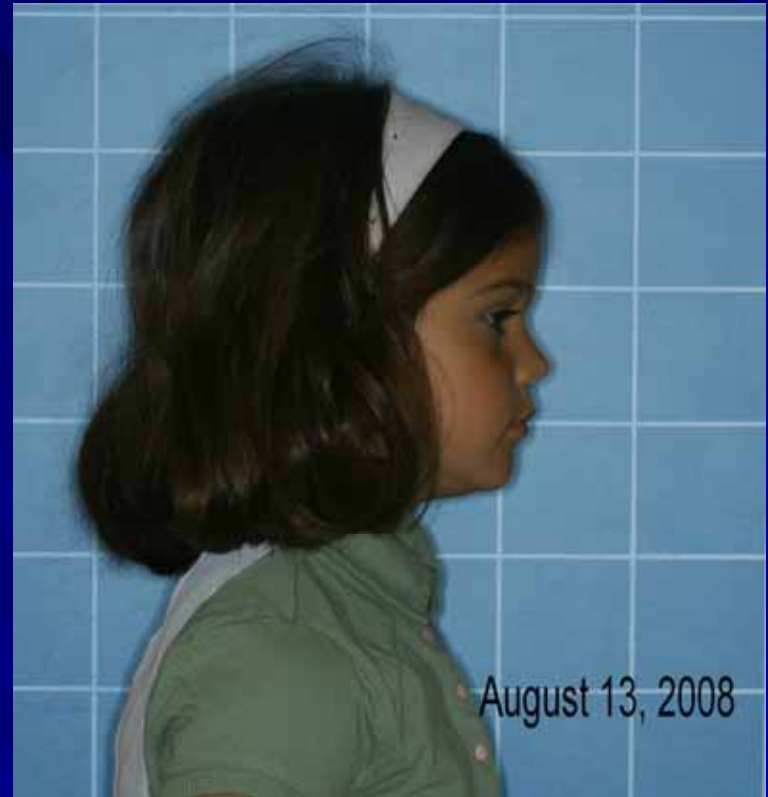
Lauren: Pre & Post Phase I Tx



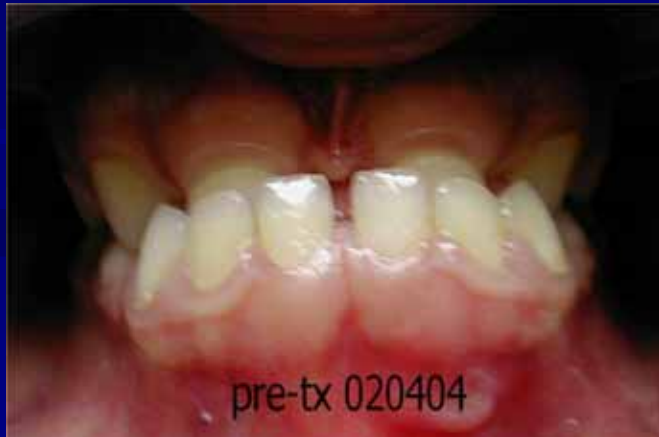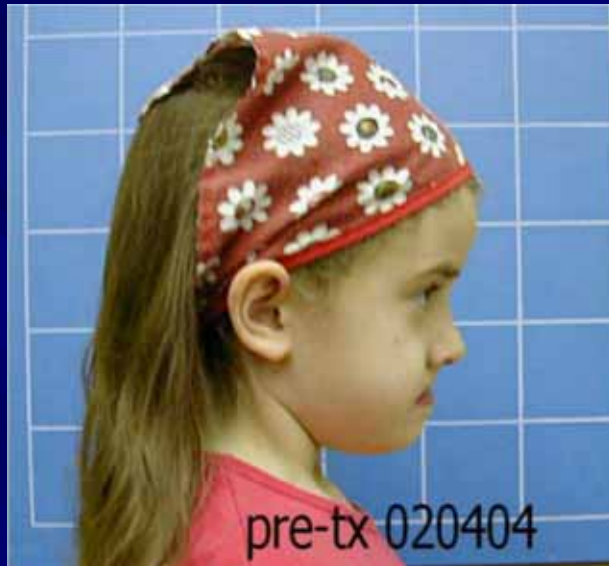Lauren

- Upper fixed Bean with facemask hooks 11 months
- Reverse pull face crib with 6oz 5/16 elastics
- Removed labial bow from Bean appliance — holding phase 8 months
- Upper 3-way Sagittal 4 months
- Upper sectional brackets 3 months
- De-bracket/ upper Wilson's for retention



Class III

Jazlyn: 6 years of age

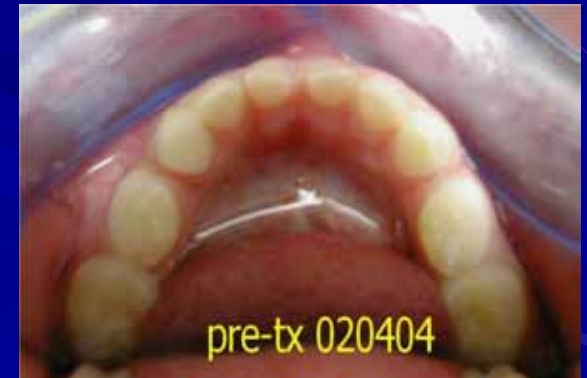
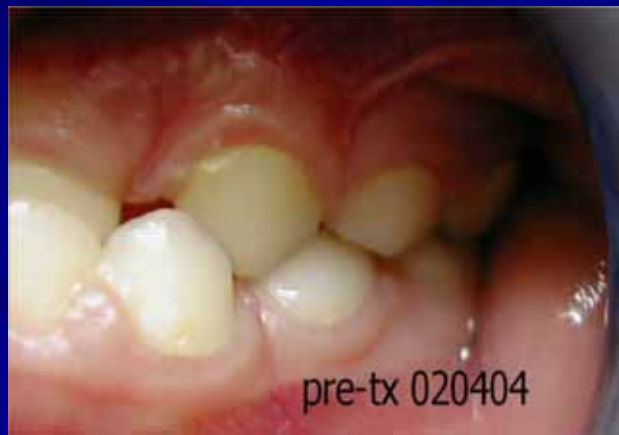
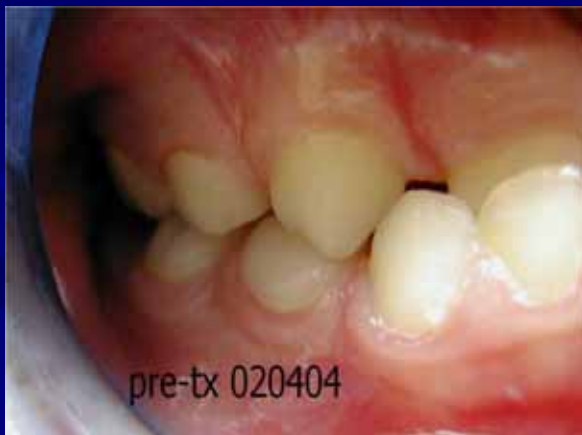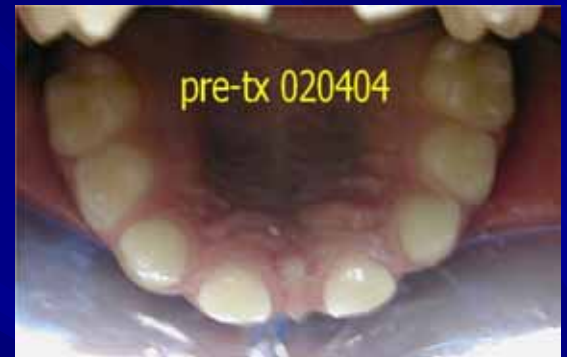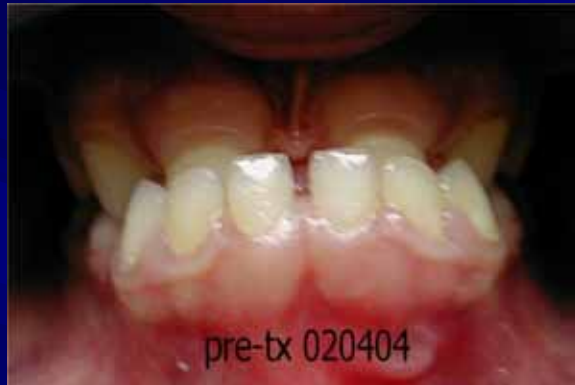- Class III full tooth
- Overjet -3mm
- Overbite -80%
- Congenitally missing 12/22
- Class III facial profile
- Mid face deficiency
- Concern: Bite

Class III

Jazlyn: 6 years of age

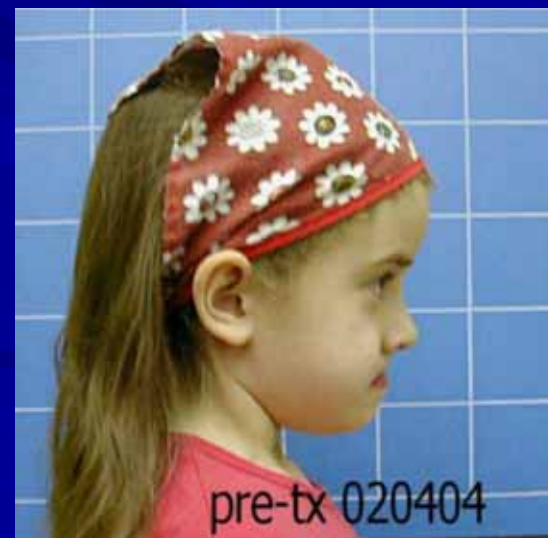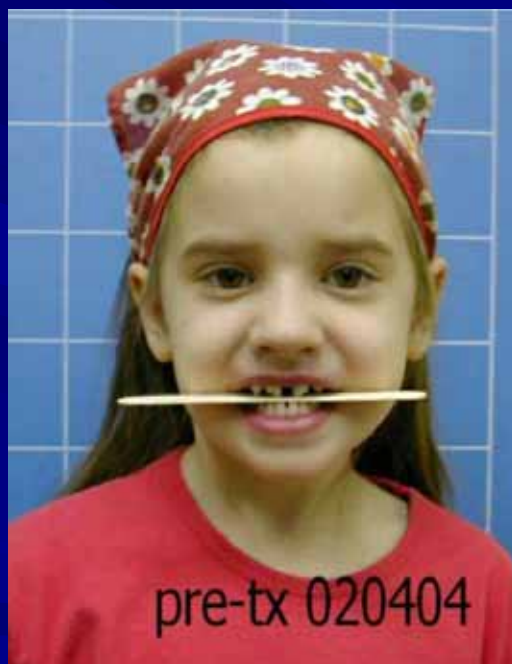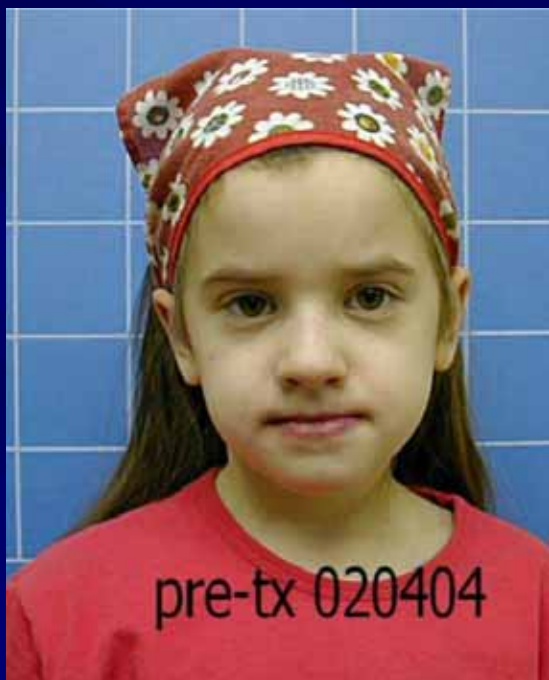Pre-treatment



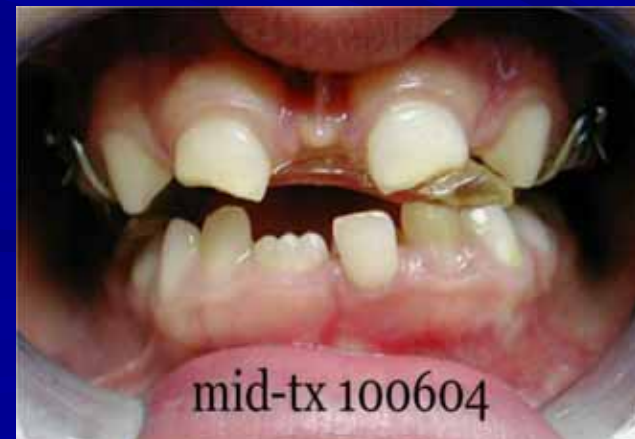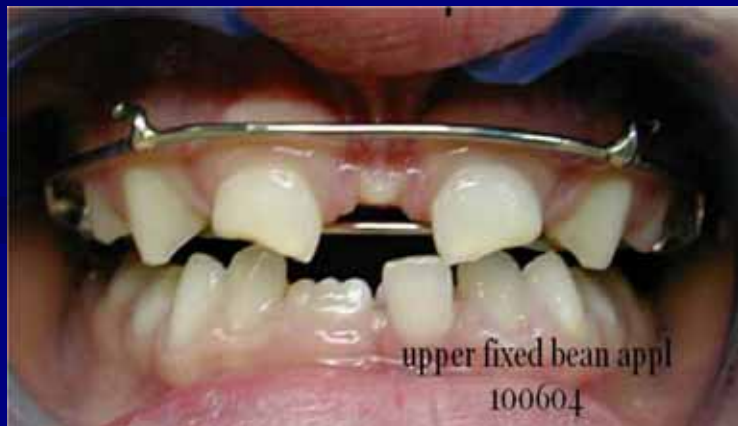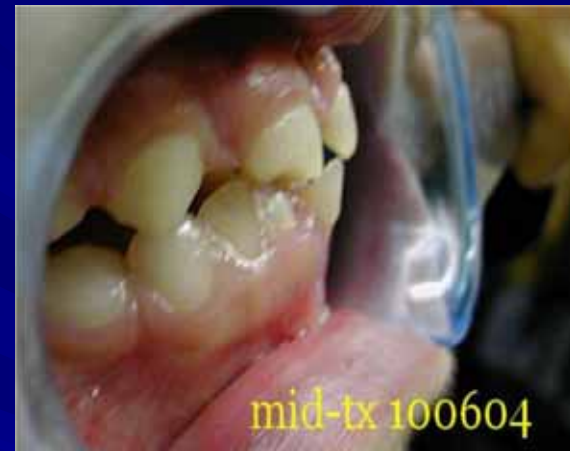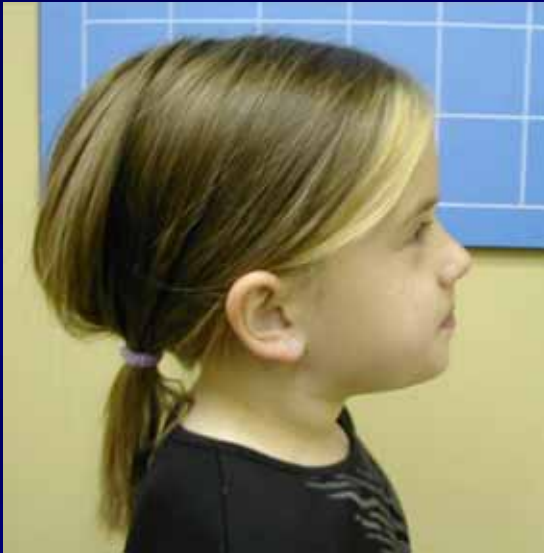Class III

Jazlyn: 6 years of age

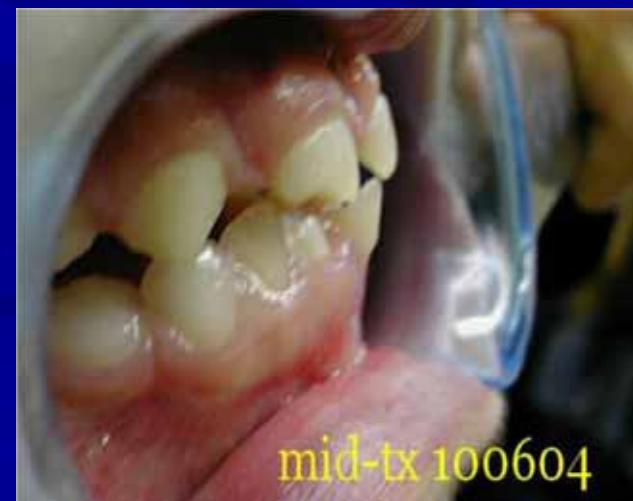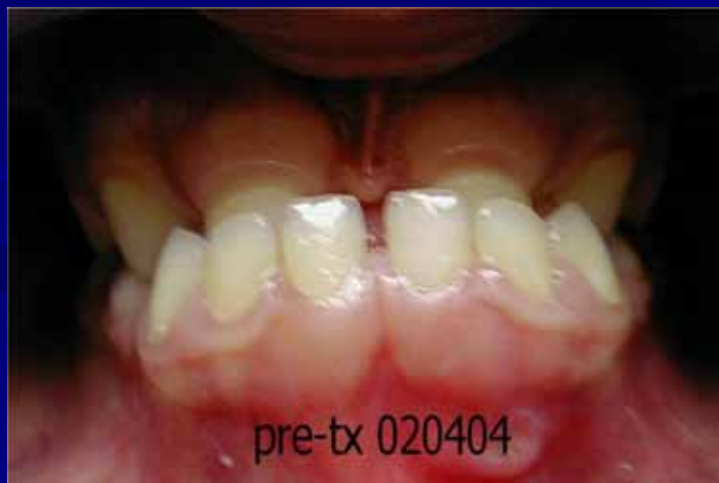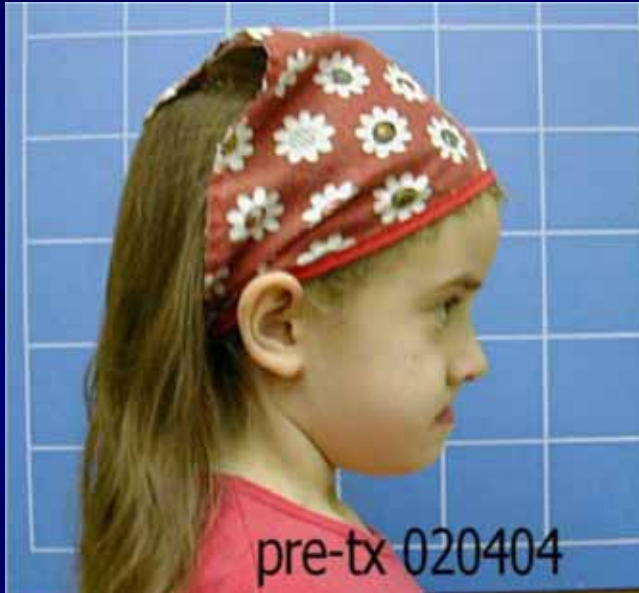Pre-treatment



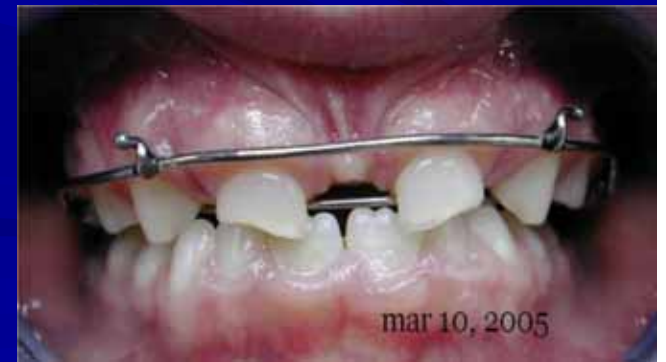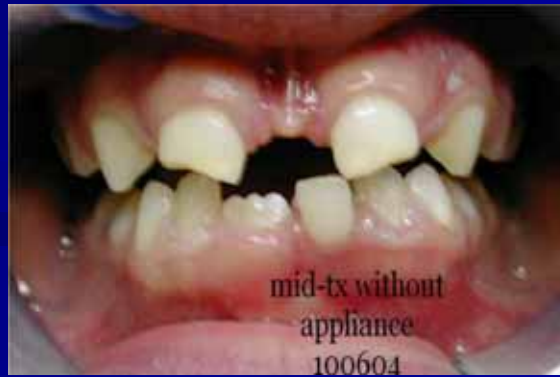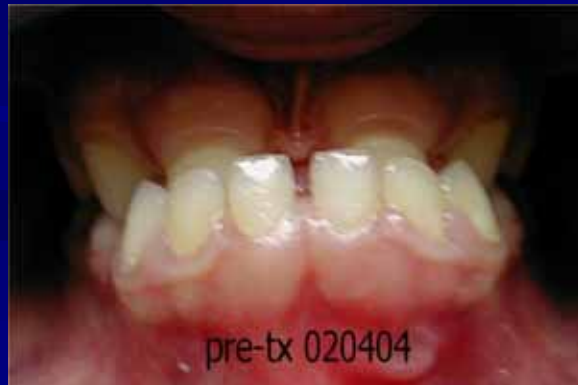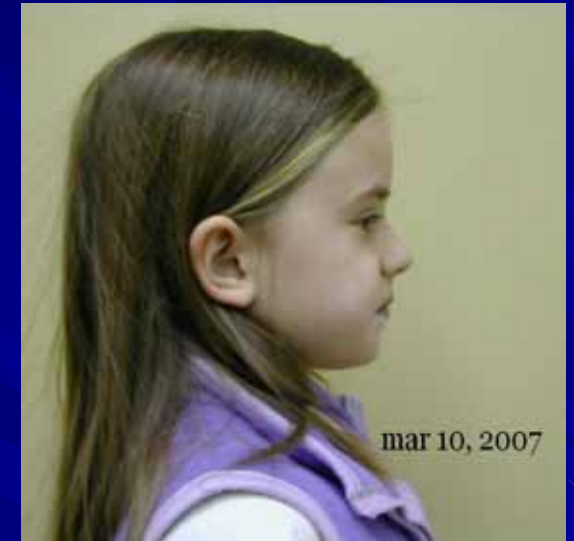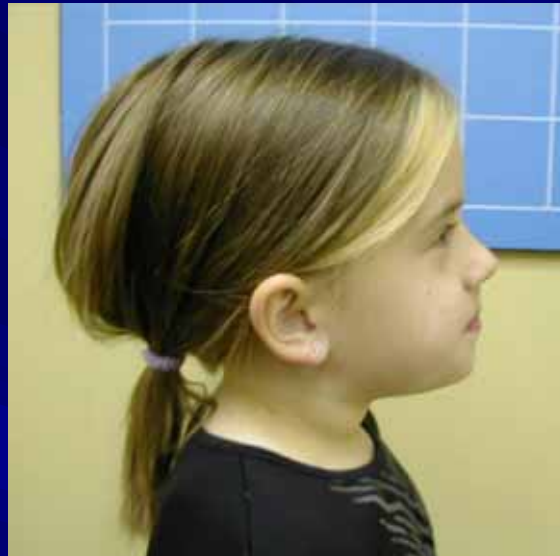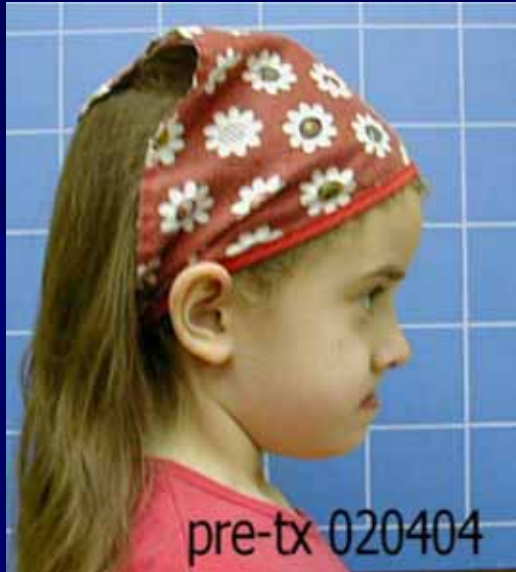Jazlyn: Post upper 3-way Sagittal 7 months of active wear



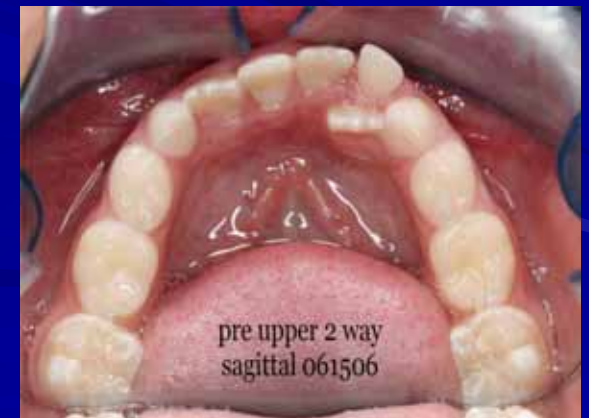
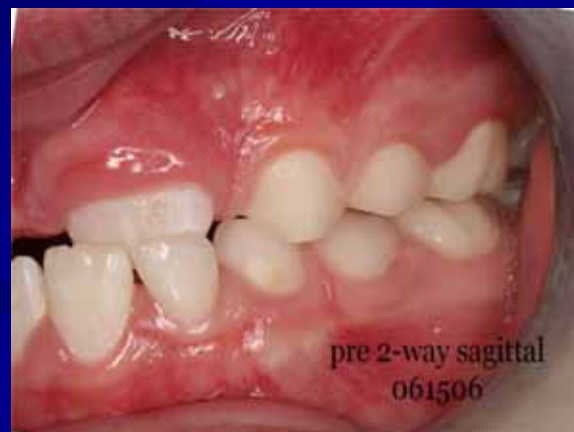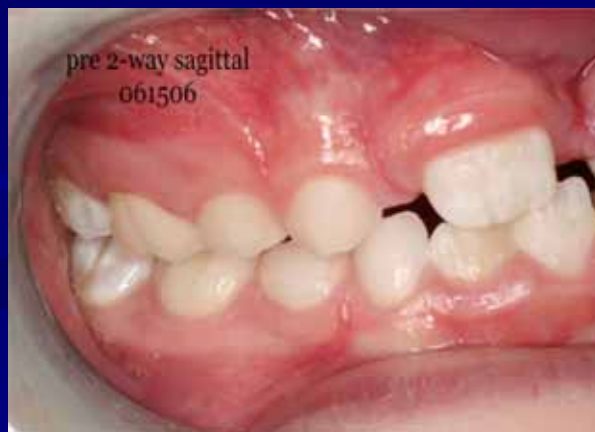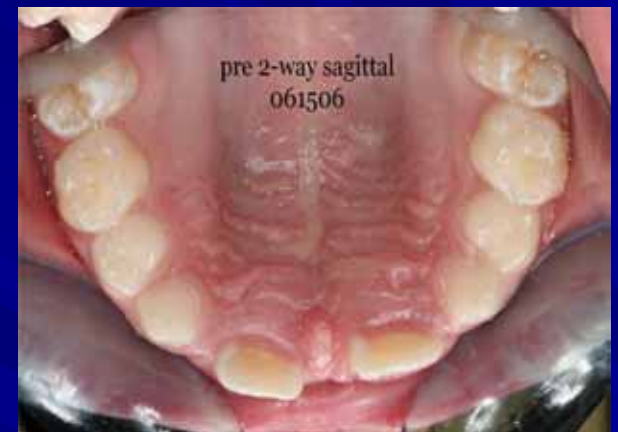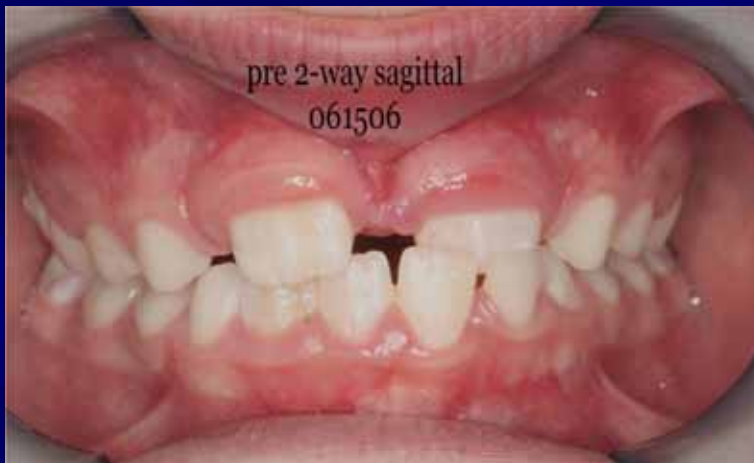Jazlyn: Pre & Mid treatment



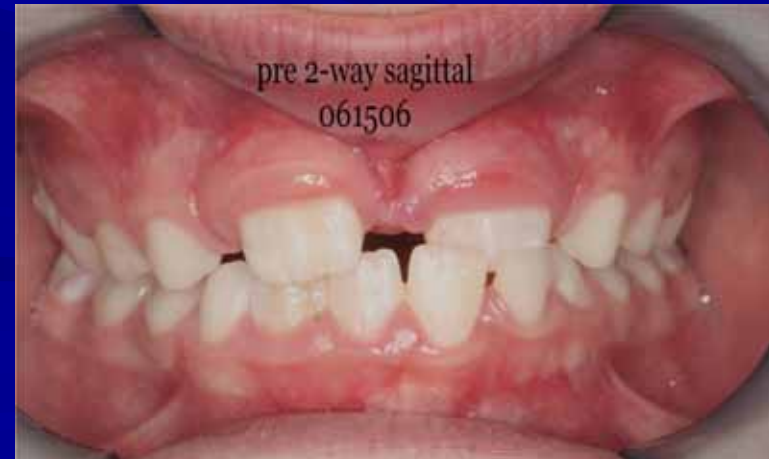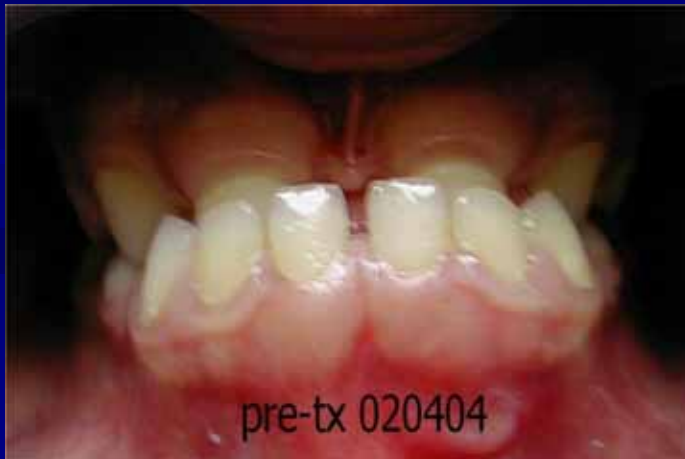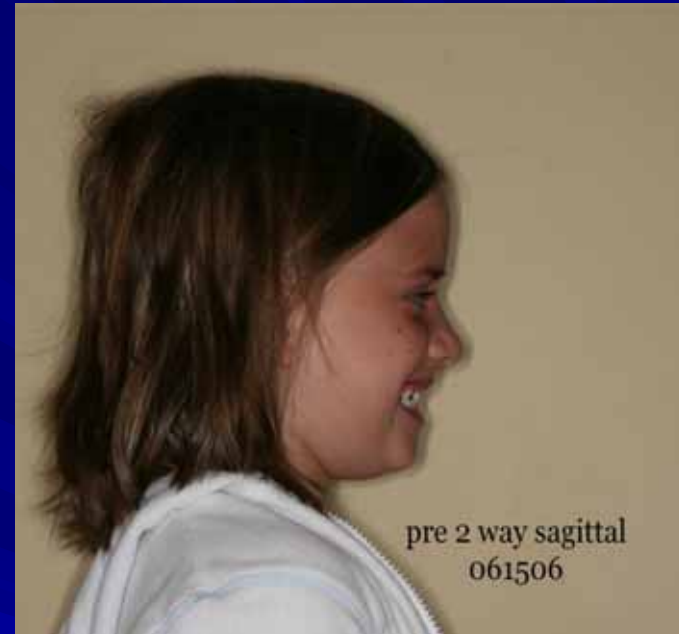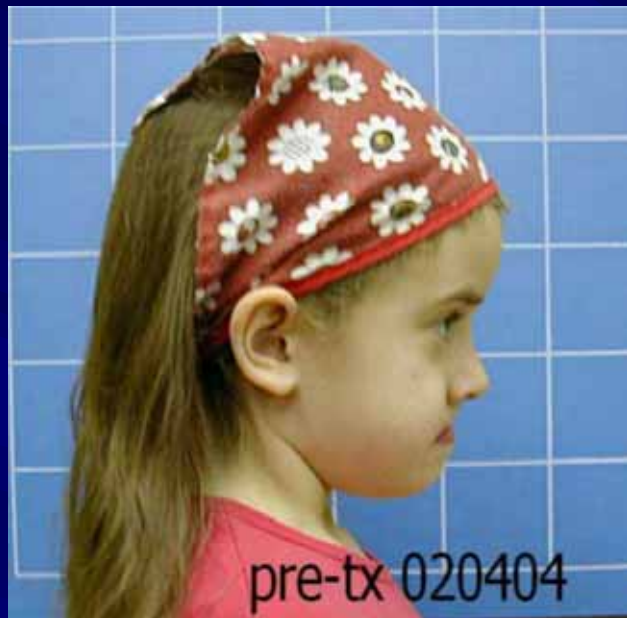Jazlyn: 12 months of active Tx



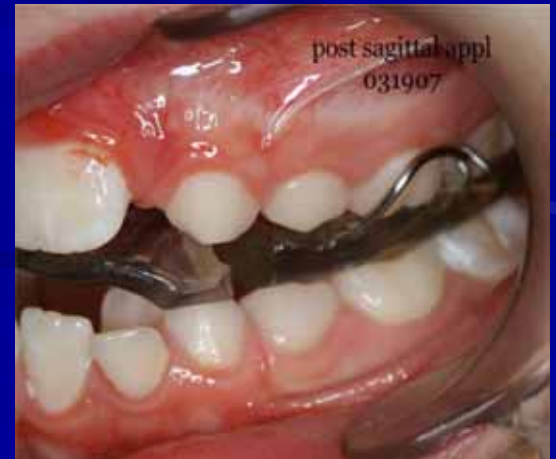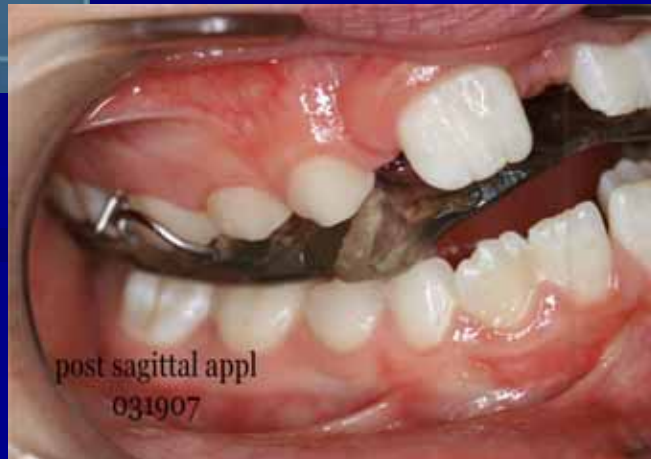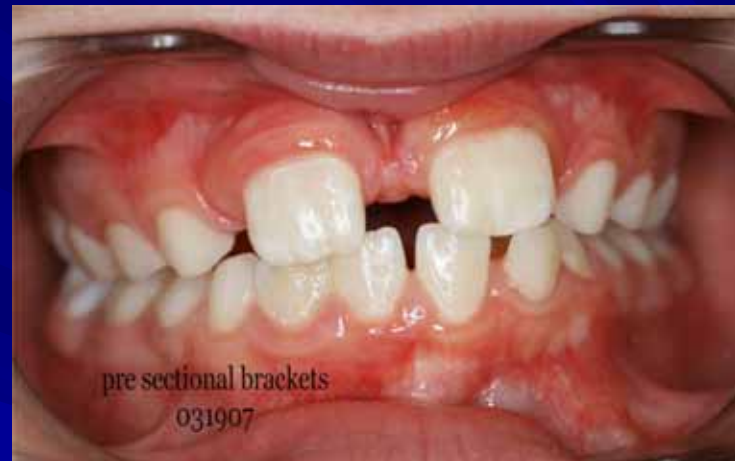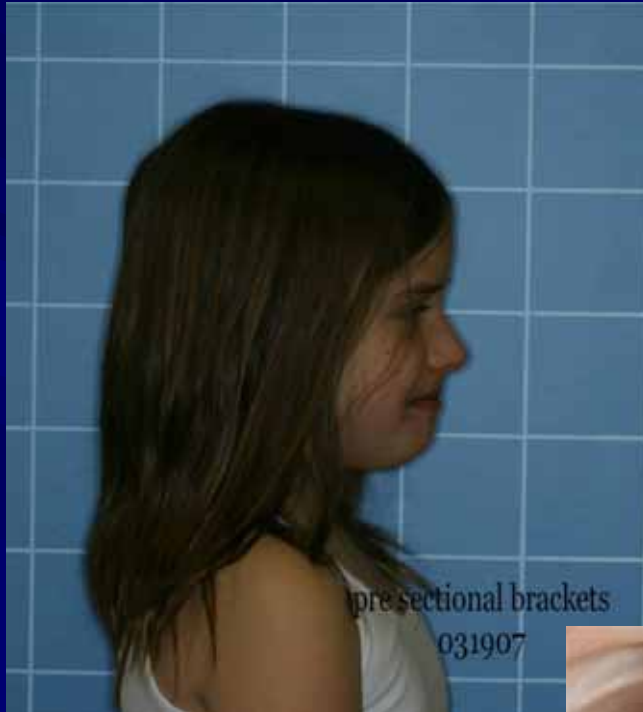Jazlyn: Upper 2-way Sagittal to correct crossbite



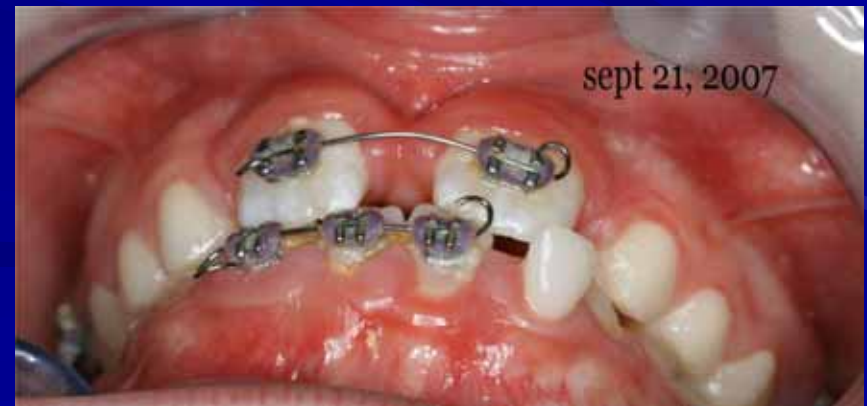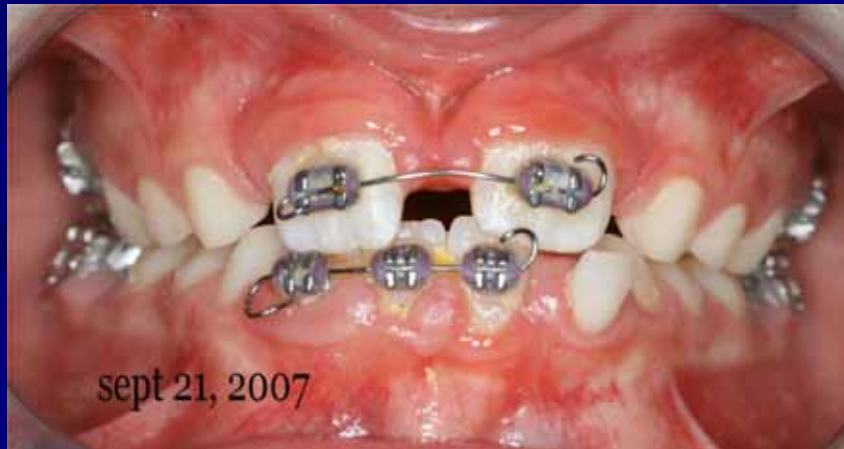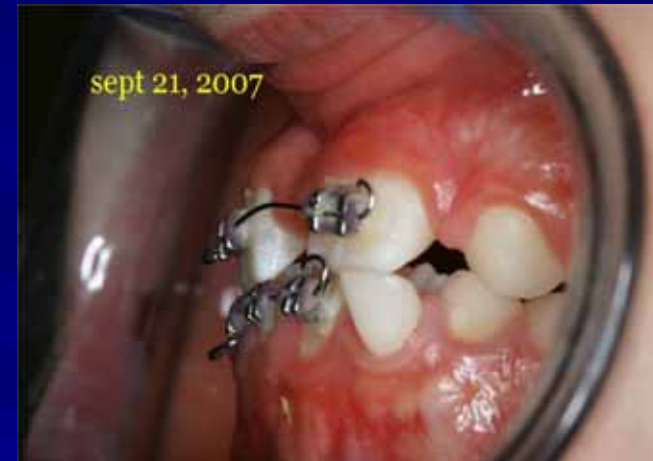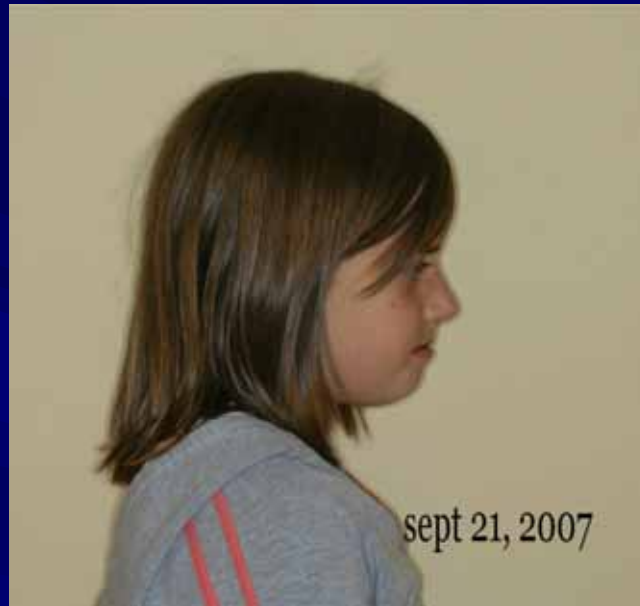Jazlyn: 28 months of Tx



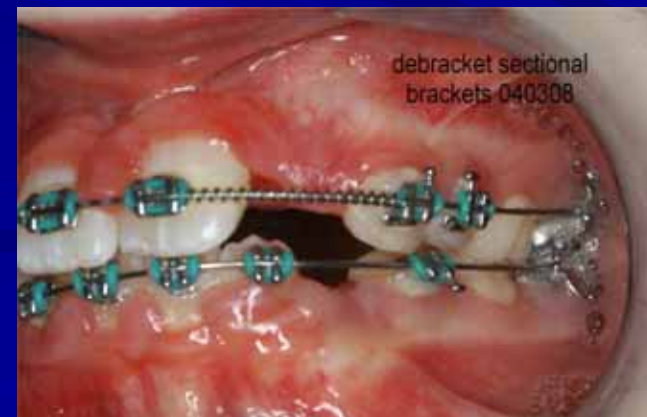
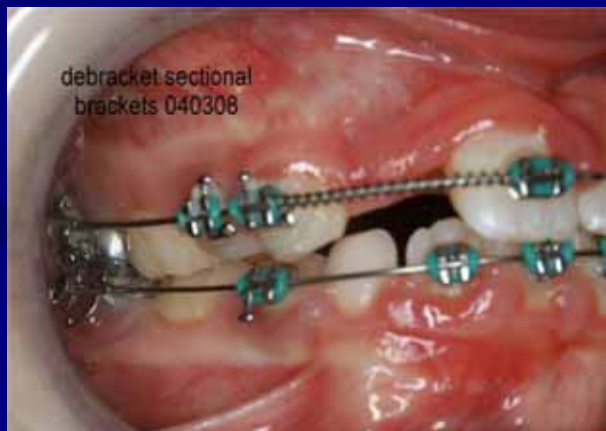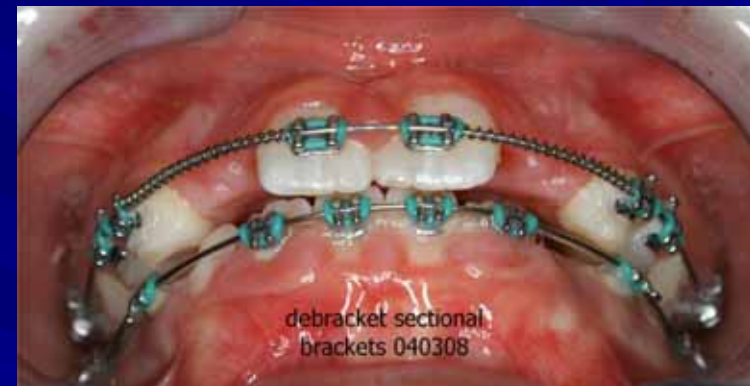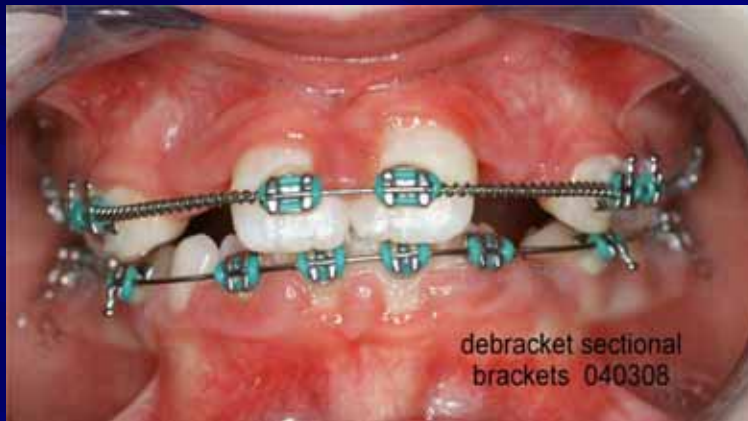Jazlyn: Post upper 2nd Sagittal 9 months active wear



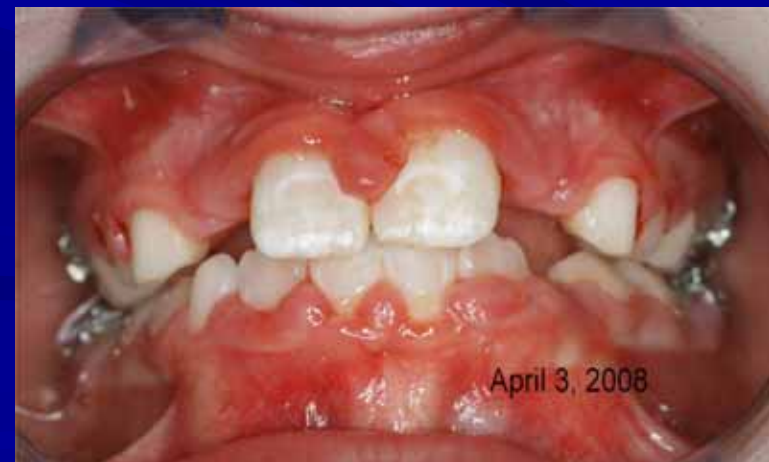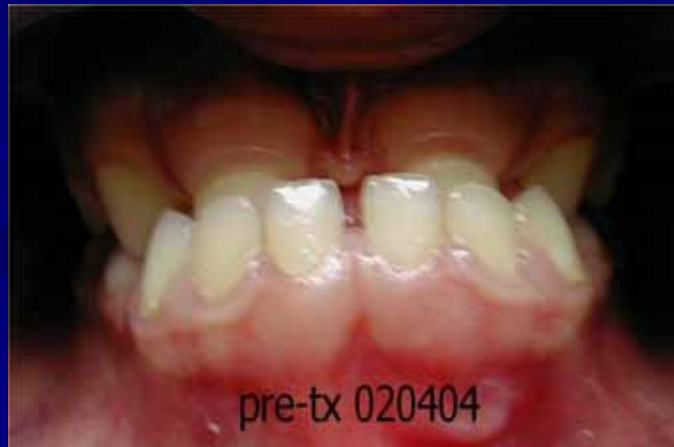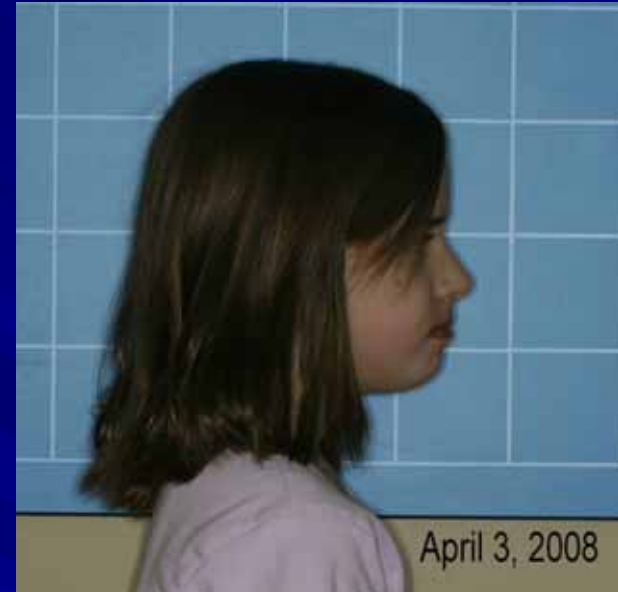
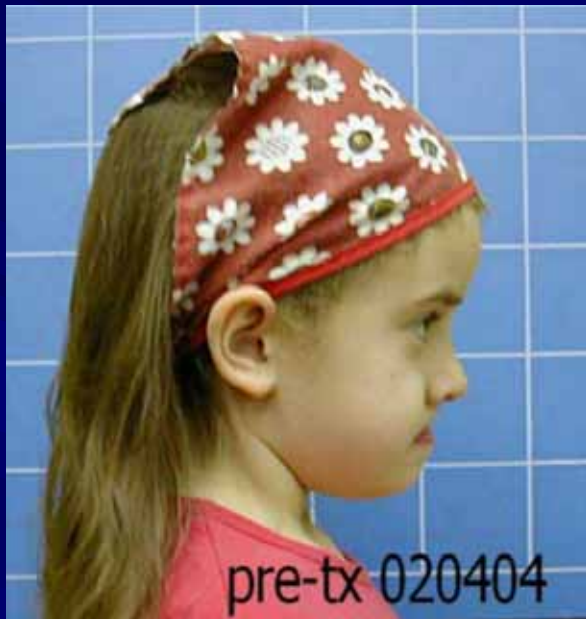Jazlyn: 6 months sectional bracket Tx



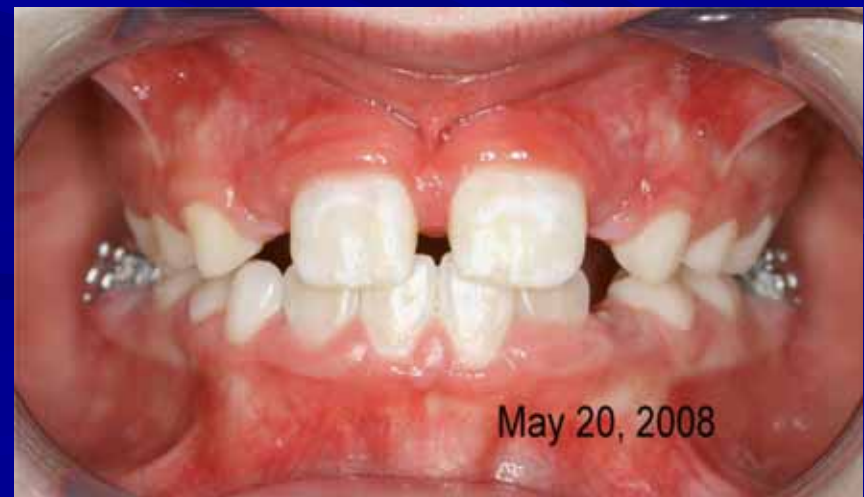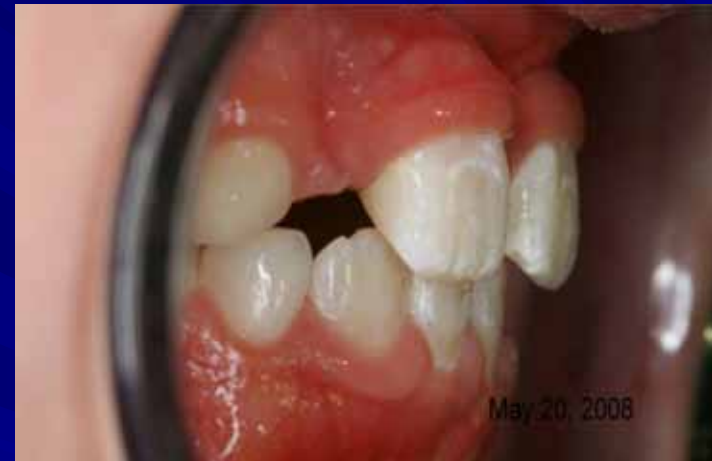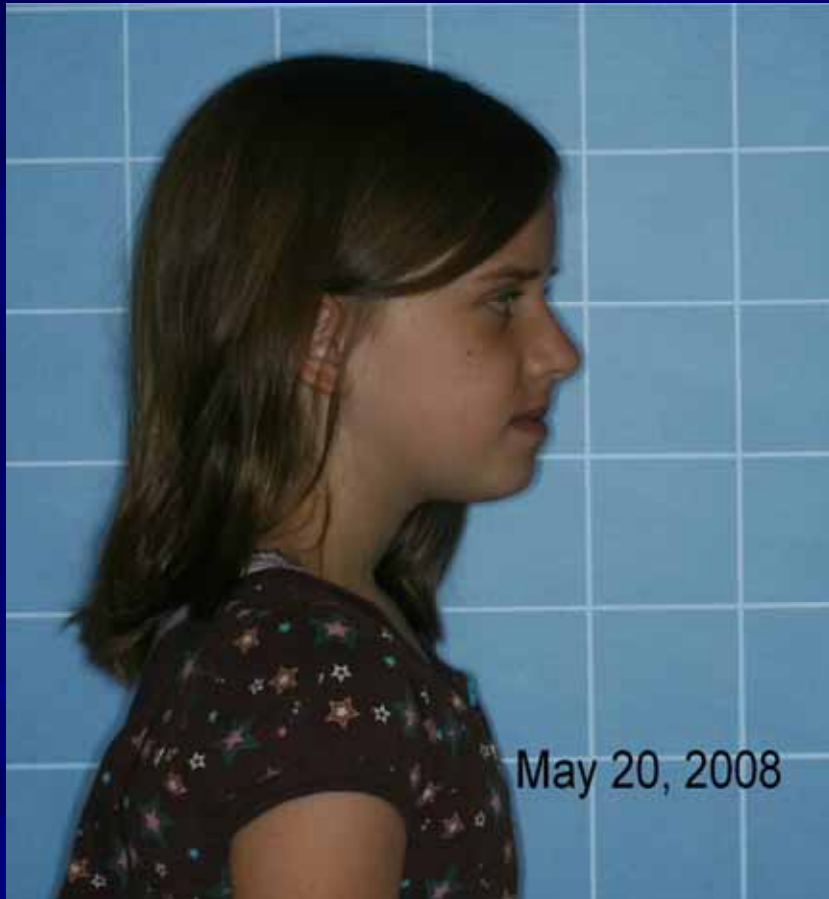Jazlyn: 13 months sectional bracket Tx



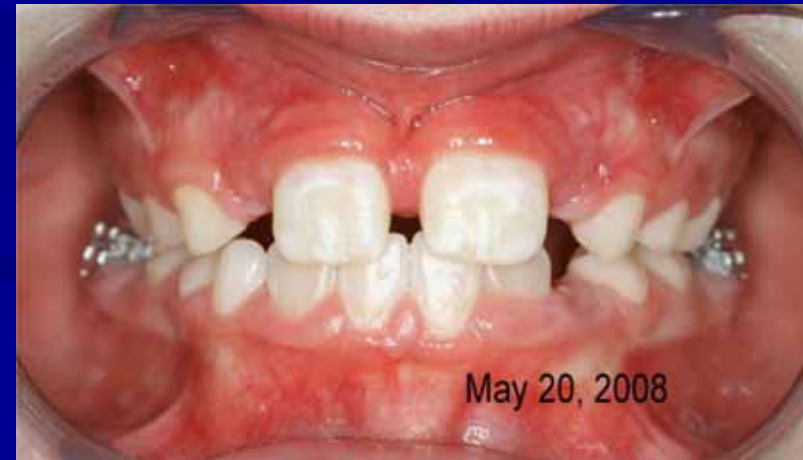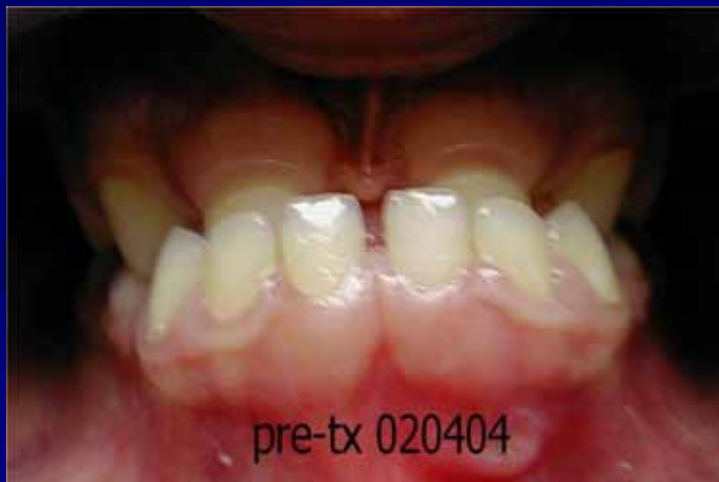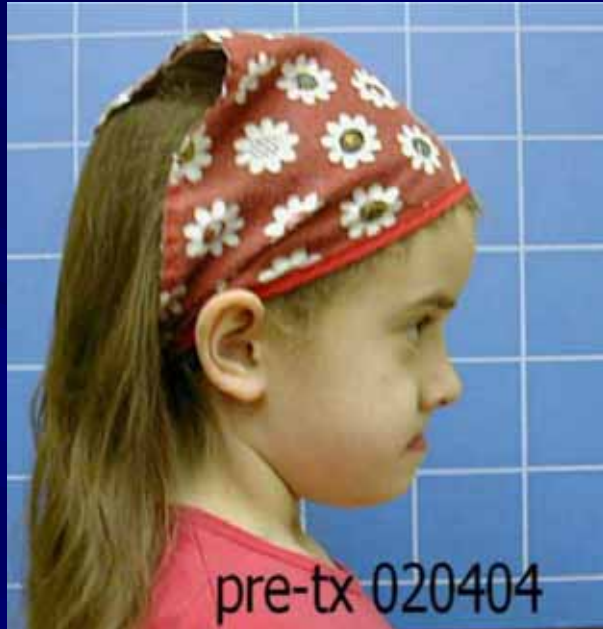Jazlyn: 48 months



Jazlyn: 1 month after de-bracket

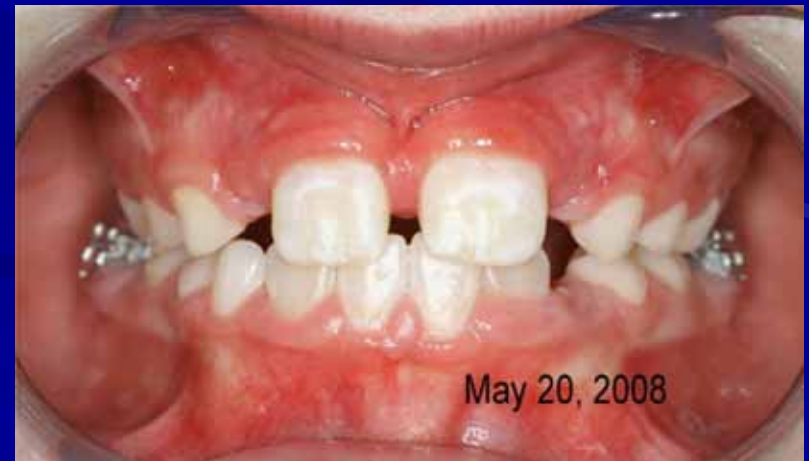

Jazlyn: Pre & Present



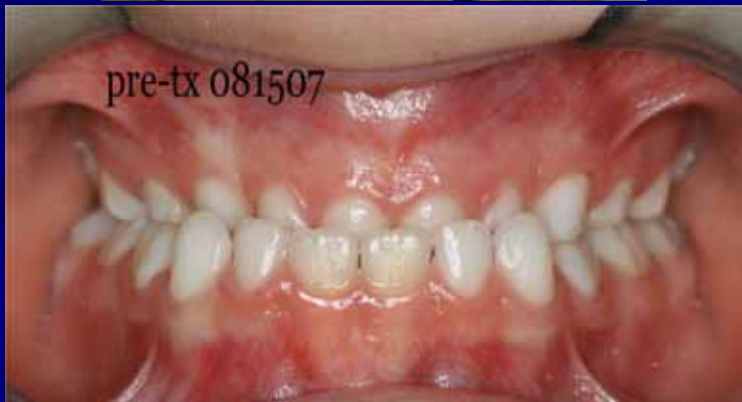Jazlyn

- Upper 3-way Sagittal with facemask hooks 6 months
- Reverse pull facemask with 8oz 5/16 elastics
- Fixed Bean appliance with facemask 13 months
- Upper frenectomy
- 2nd 2-way Sagittal to correct 21 in crossbite 9 months
- Upper/lower sectional brackets 13 months
- Upper Hawley with 12/22 for retention



Class III/I

Luke: 7 years of age

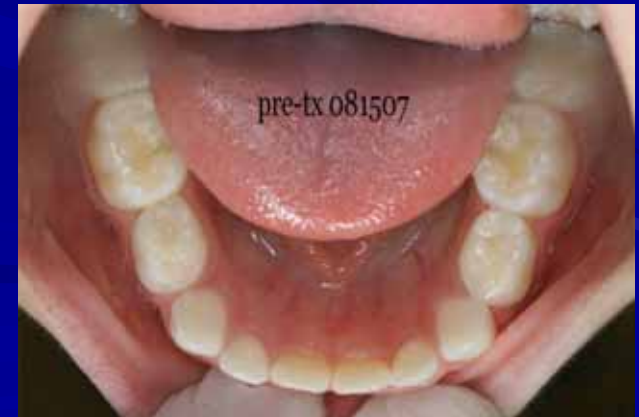
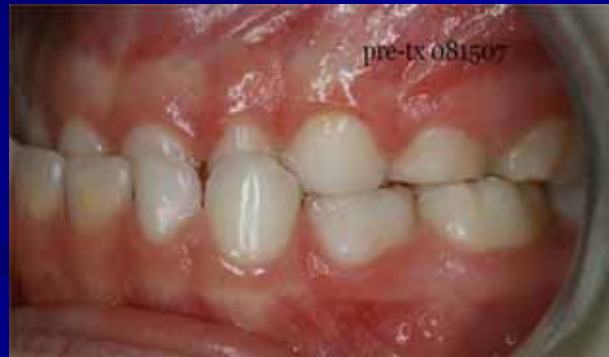
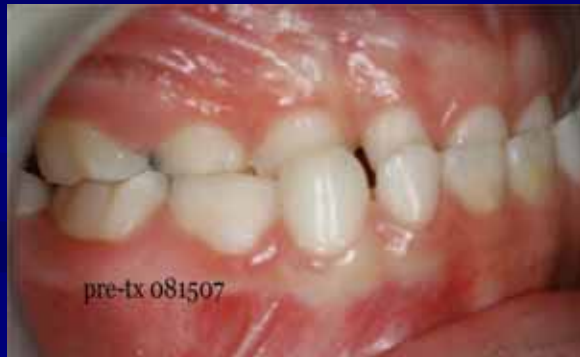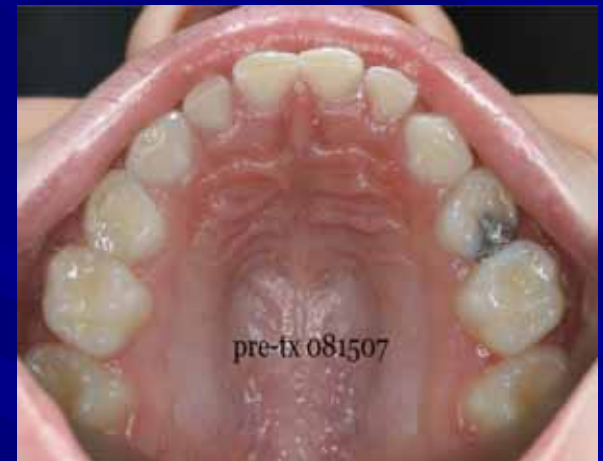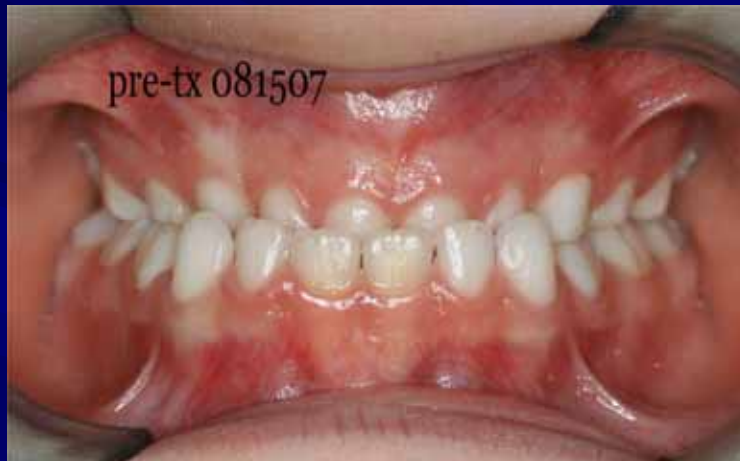- Class III ½ left
- Class I right
- Overjet -3
- Overbite 80%
- Anterior crossbite
- Class I facial profile
- Concern:
Anterior crossbite

Class III/I

Luke: 7 years of age

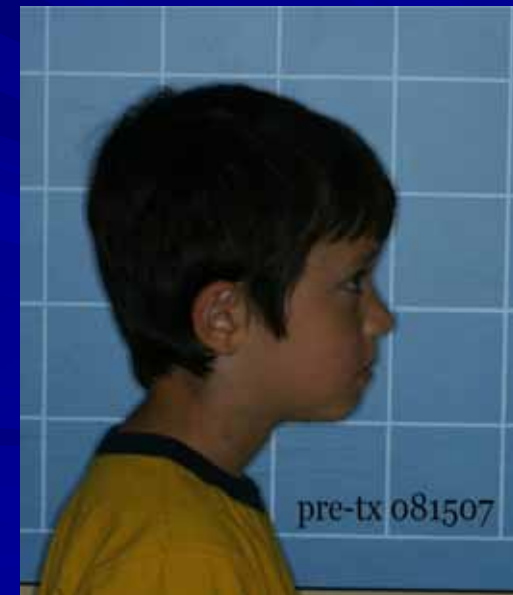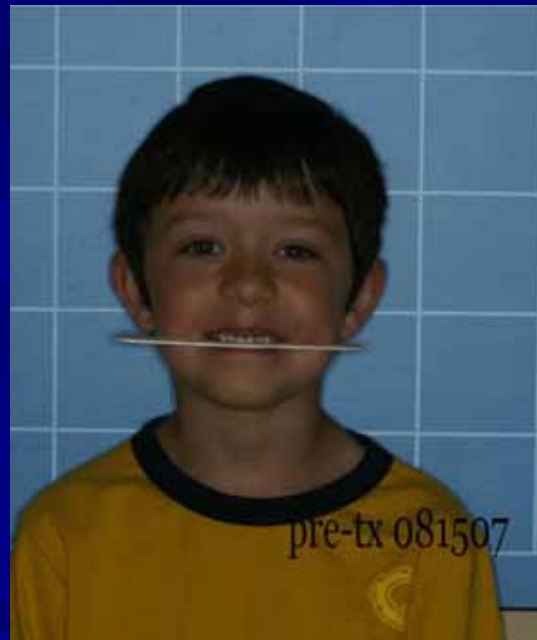Pre-treatment



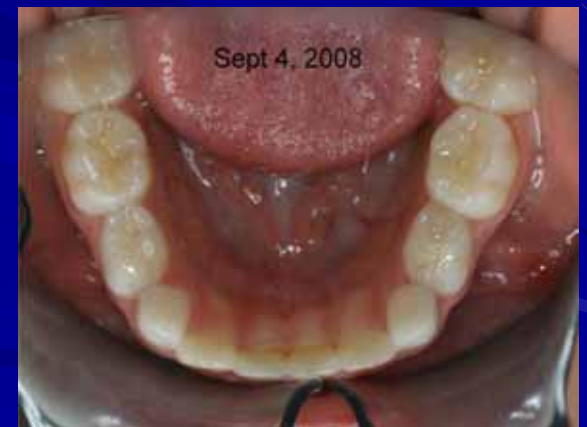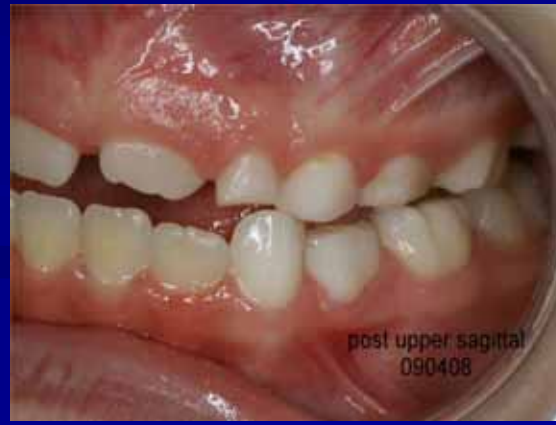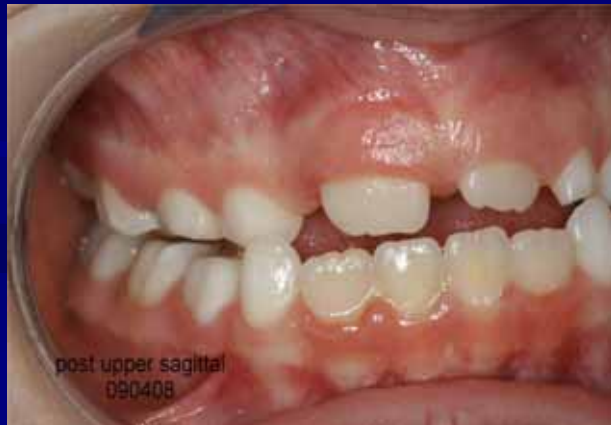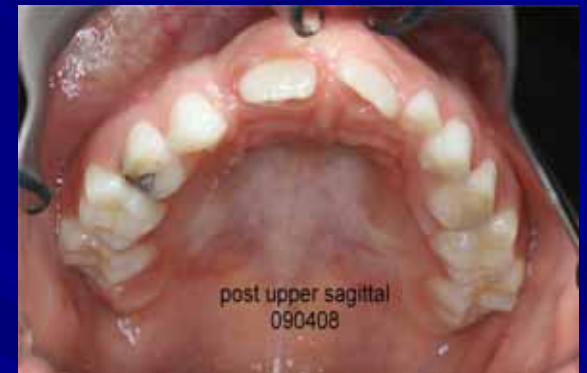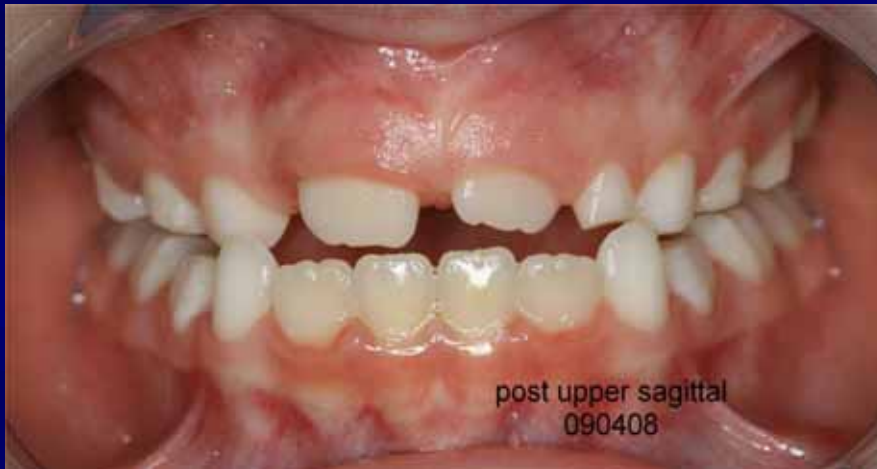Class III/I

Luke: 7 years of age

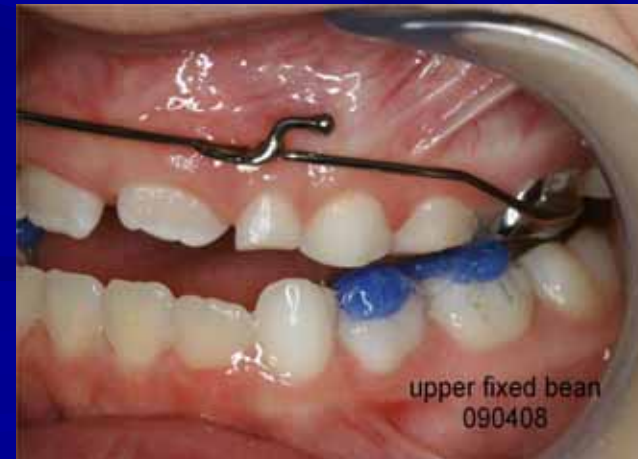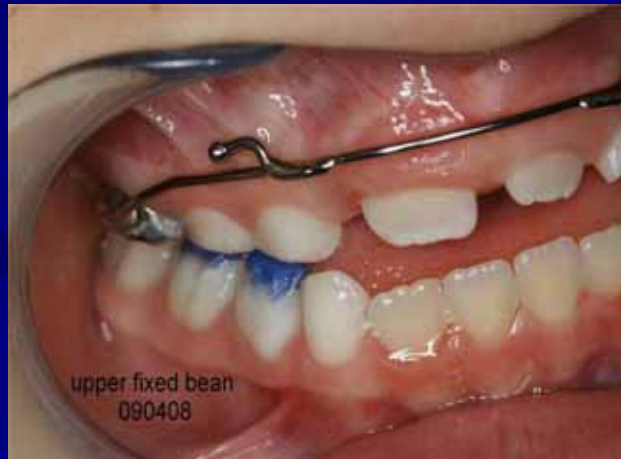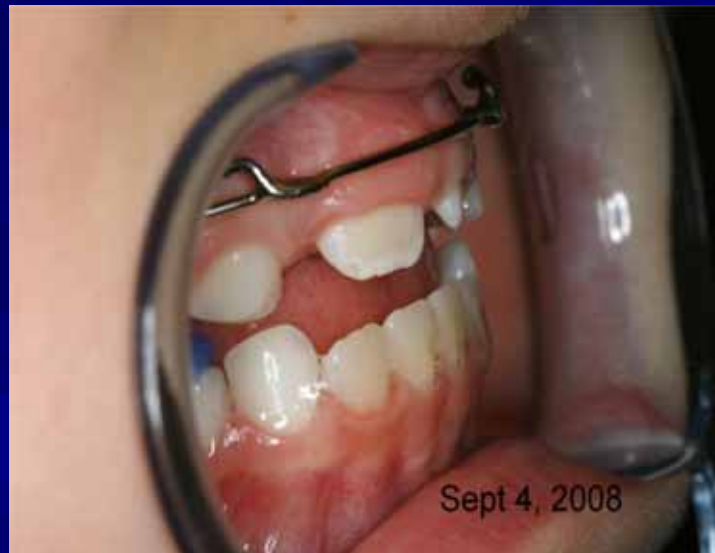Pre-treatment



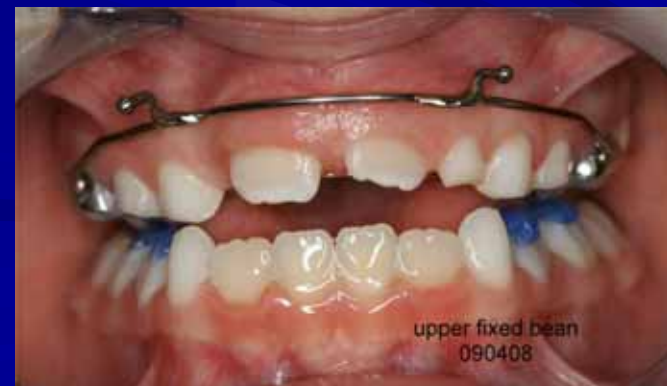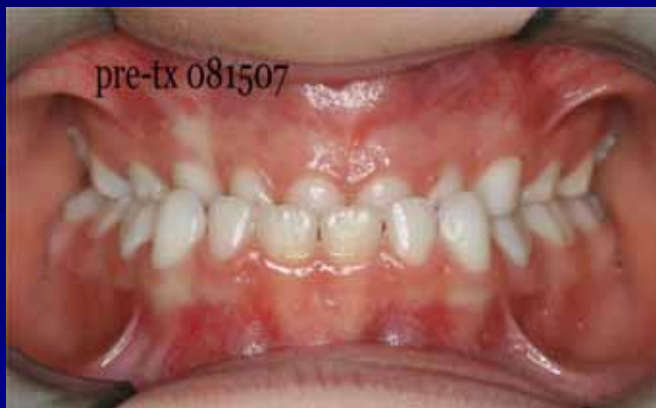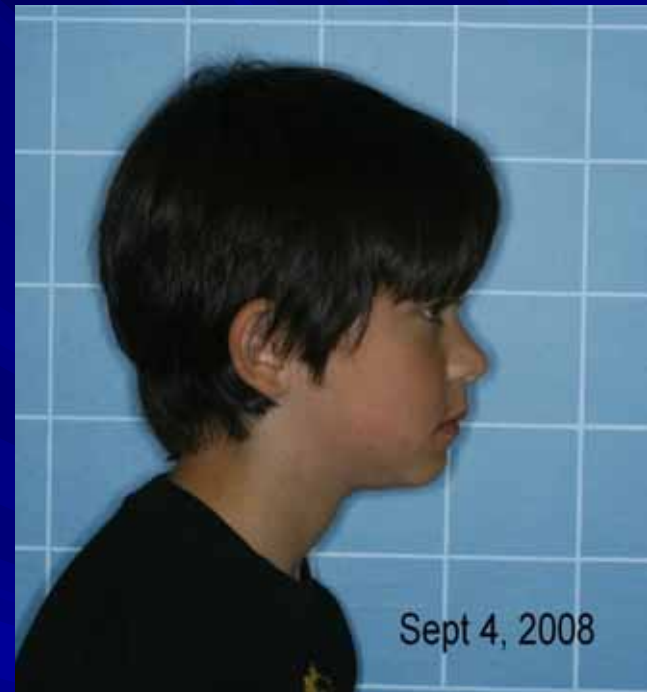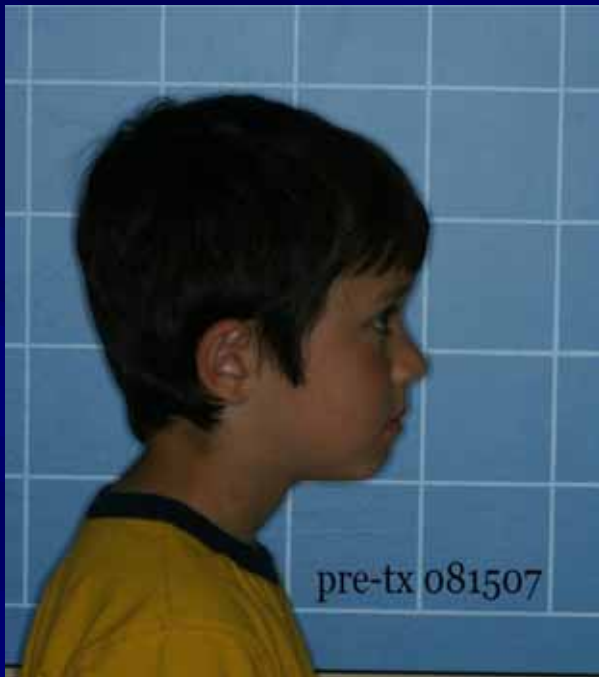Luke: Post upper Sagittal 11 months active wear



Luke: Upper fixed Bean (Presently wearing)

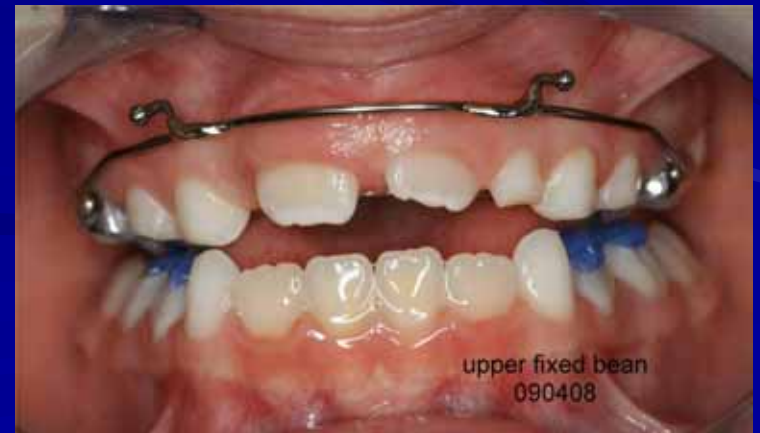
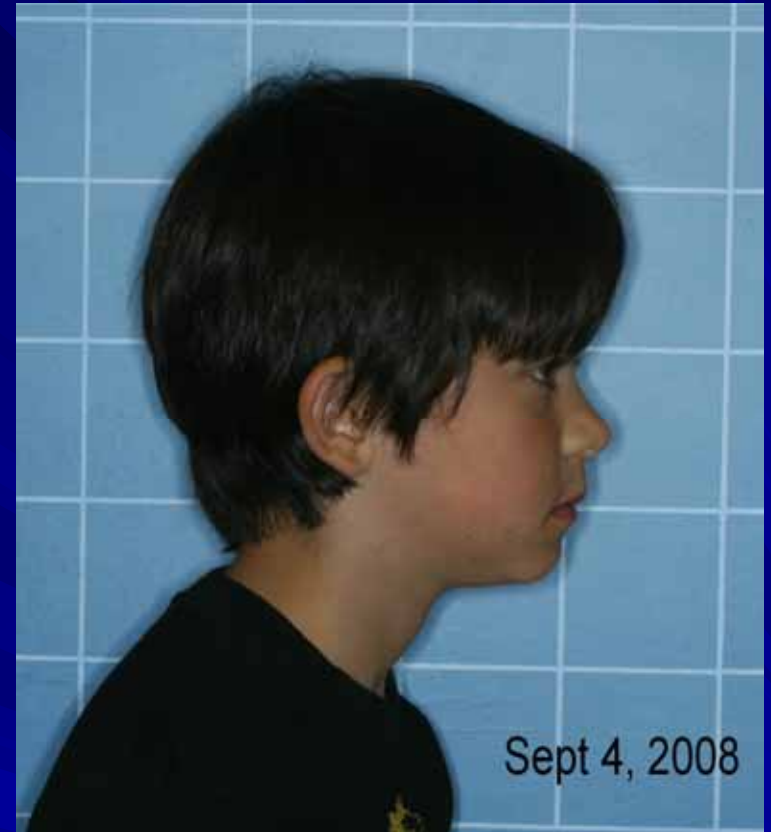
Luke: Pre & Mid treatment



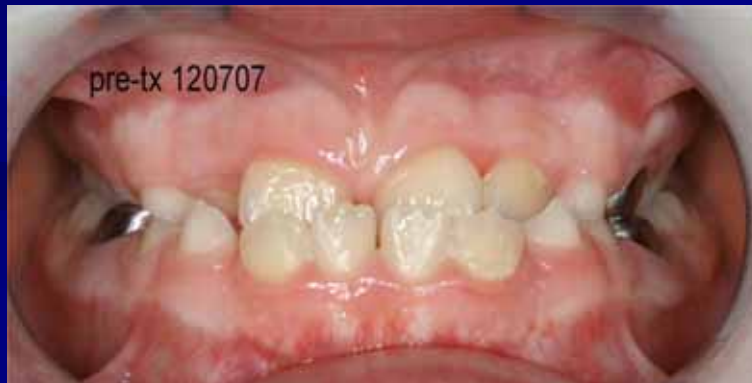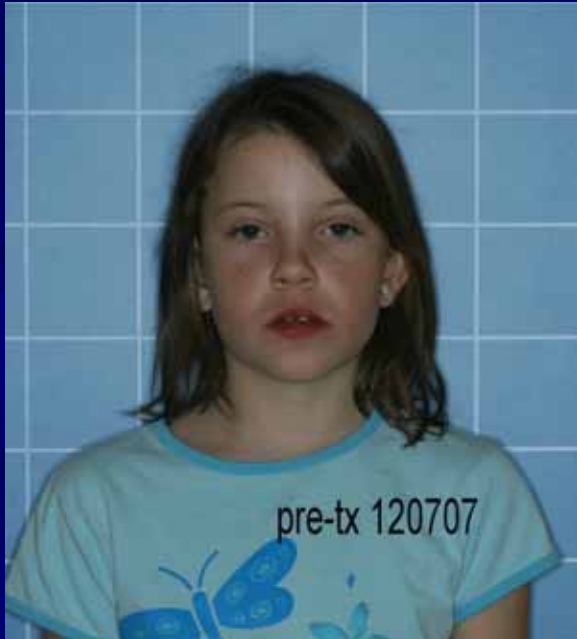Luke

- Upper 3-way Sagittal with facemask hooks 11 months
- Reverse pull face crib with 8oz 5/16 elastics 6 months
- Luke broke upper appliance several times which delayed treatment
- Presently wearing a fixed Bean appliance with build ups to clear crossbite



Class III

Megan: 10 years of age

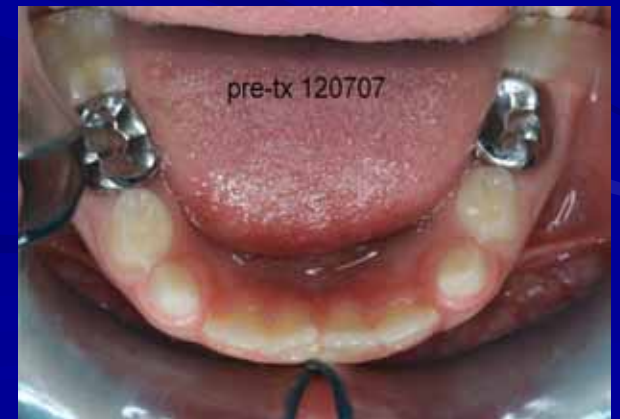
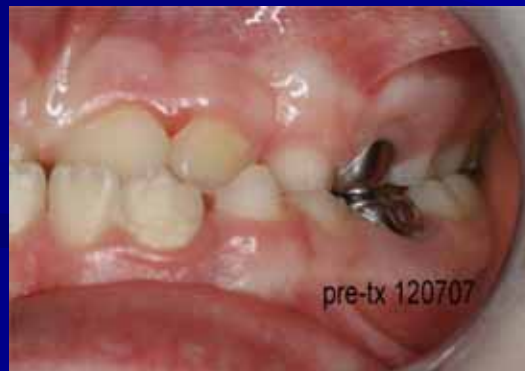
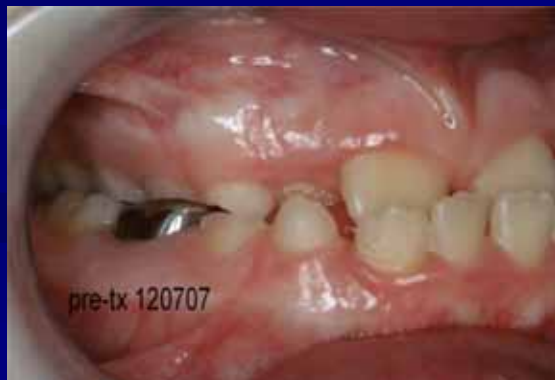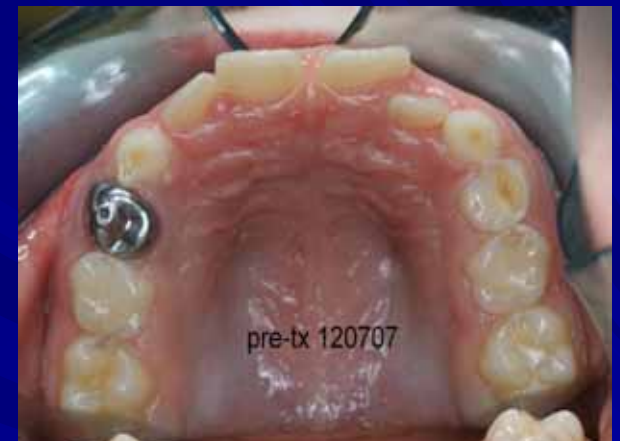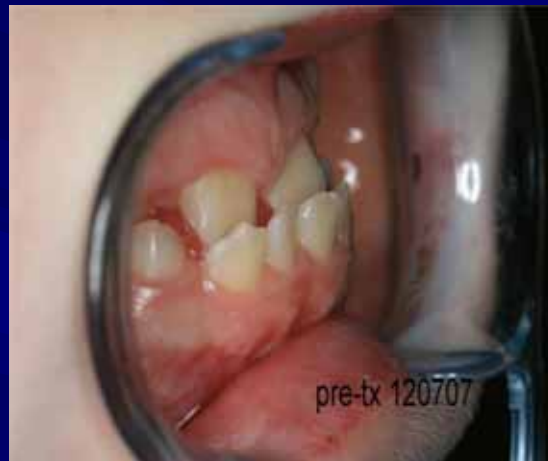- Class III ½ tooth
- Reverse crossbite
- Overjet -2
- Overbite -50%
- Deficient mid face
- Class I facial profile
- A lot of headaches
- Concerns:
Headaches/bite

Class III

Megan: 10 years of age

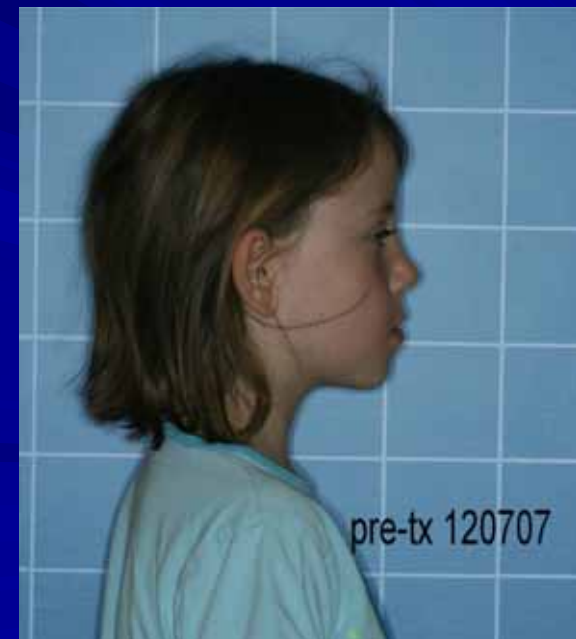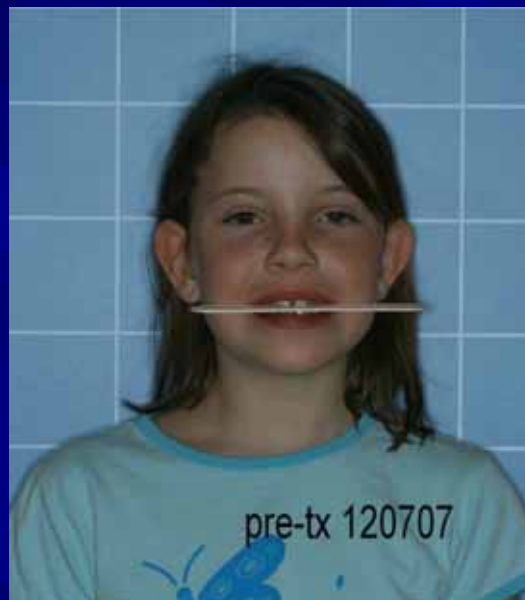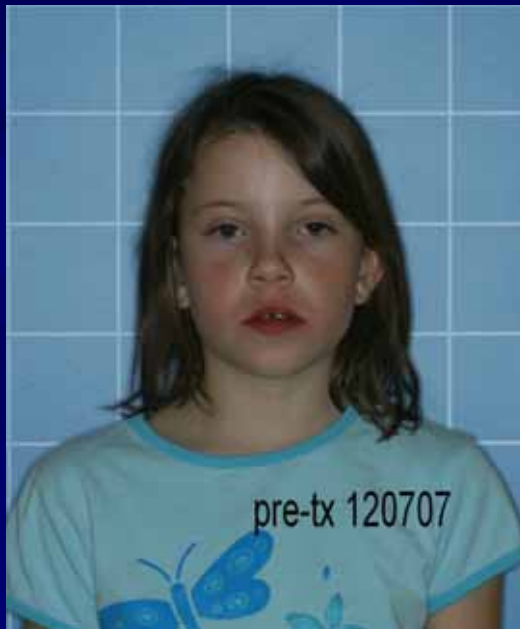Pre-treatment



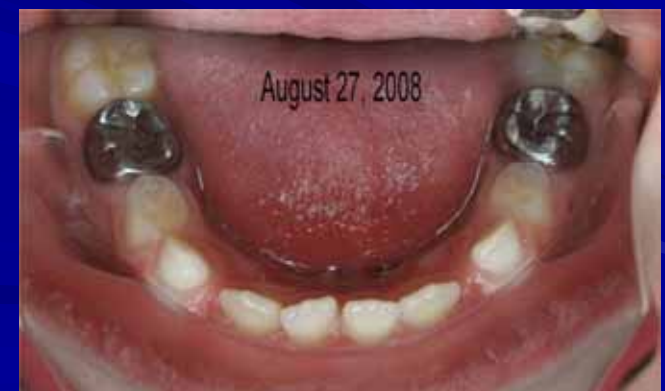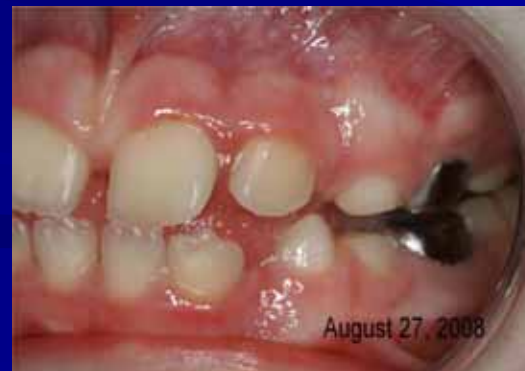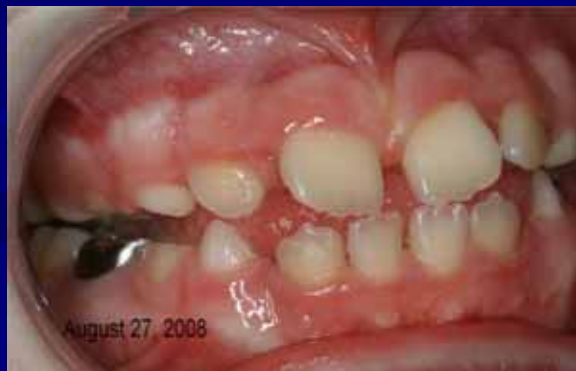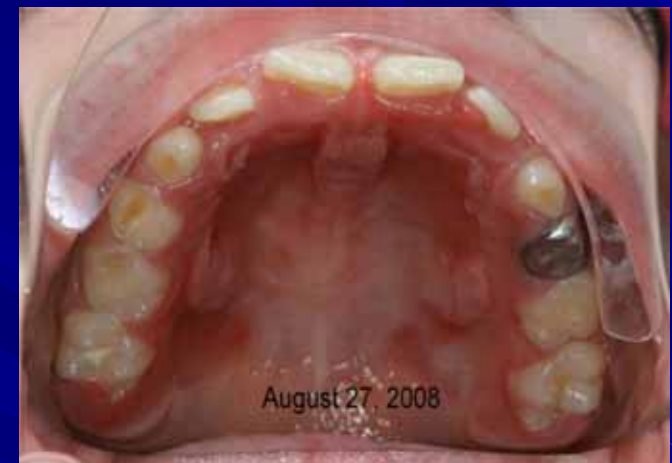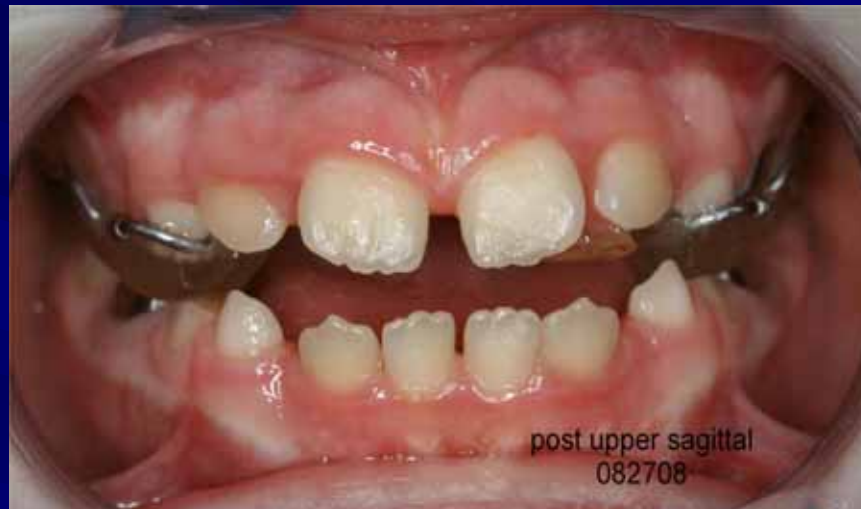Class III

Megan: 10 years of age

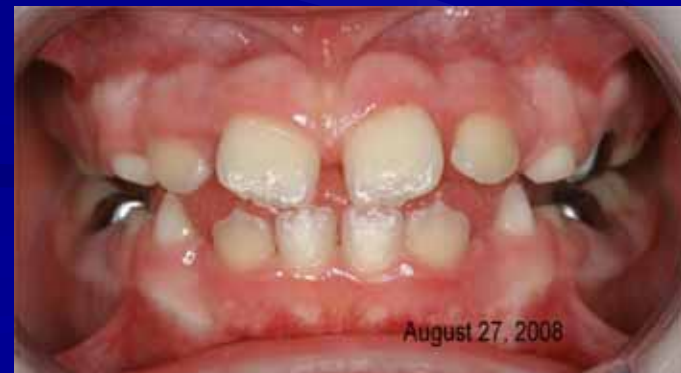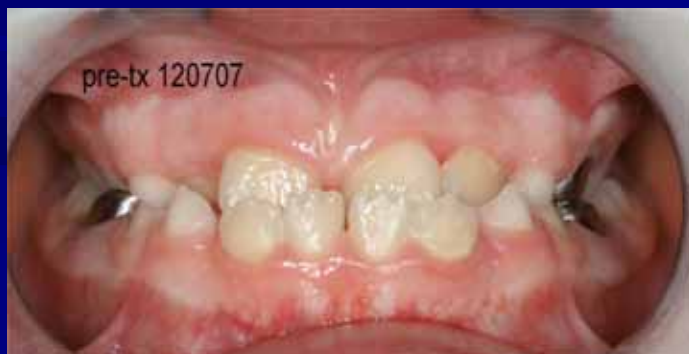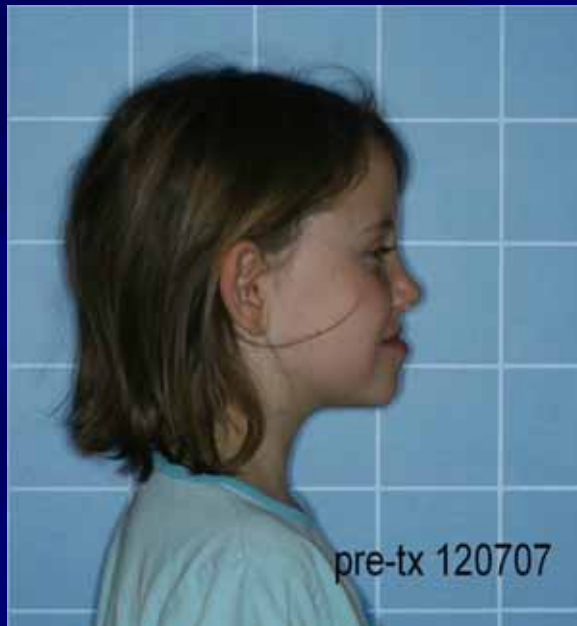Pre-treatment



Megan: Post upper Sagittal 8 months active wear

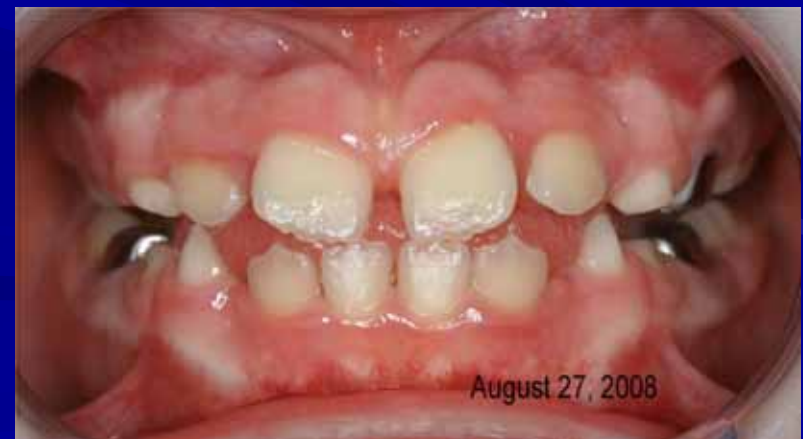

Megan: Pre & Mid treatment



Megan

- Upper 3-way Sagittal with facemask hooks 8 months
- Reverse pull face crib with 8oz 5/16 elastics
- Presently wearing upper fixed Bean appliance in conjunction with the facemask



Self-Instruction Continuing Education Video Programs

Visit www.orthodontic.ca
under **EDUCATION** for complete details.
or Call 1-800-267-9225
E-mail: bonarch@orthodontic.ca



50 % DISCOUNT OFF ALL PROGRAMS

✓ Cost-effective ✓ No Hotel or Travel ✓ Share with a colleague ✓ Motivate staff ✓ Invaluable reference material



Dr. James Broadbent
Orthodontist

Learn the keys of diagnosis of the face, TMJ, dentition and biomechanics to obtain excellent orthodontic results in your practice.

23 hours of integrated Functional Jaw Orthopedics (FJO) and Orthodontic Concepts; Exclusive Clinical "Pearls"; Current and Systematic Techniques; Practical and Substantiated Treatment Methods. Includes 480 Page Manual

Regular Price \$995

NOW \$497.⁵⁰



Dr. Merle Bean
Pediatric Dentist

Pioneer of the Reverse Face Mask Treatment for Maxillary Advancement in the USA

12 hours of detailed Orthopedic/Orthodontic/TMJ/D Instruction on Class I, II, III

Logical treatments you can implement into your practice immediately.

Chapter Reference Booklet

Regular Price \$495

NOW \$247.⁵⁰



Dr. Brendan Stack
Orthodontist

Past President and Founder of the American Academy of Cranial Facial Pain (AACP)

Specialist in Orthodontics, TMJ, Snoring & Sleep Apnea

41.5 hours of TMJ/TMD Dysfunction, Occlusion and Craniofacial Pain Diagnosis and Treatment.

Bonus Video on The Treatment of Complex TMD Problems, Movement Disorder and Body Tremor Patients Included

Regular Price \$3,688

NOW \$1,844.⁰⁰

10 HOUR BONUS DVD WITH YOUR PURCHASE
Functional Jaw Orthopedics (FJO), Orthodontics and
Temporomandibular Joint Dysfunction (TMJD)

Dr. Brendan Stack, Dr. James Broadbent, Dr. James May, Dr. Merle Bean, Mr. Emmett Griffiths

OFFER EXPIRES December 31, 2011 EA-06 2011



Rideau Orthodontic Mfg. Ltd.

ALL DENTAL DEVICES NOW LASER WELDED

NEW



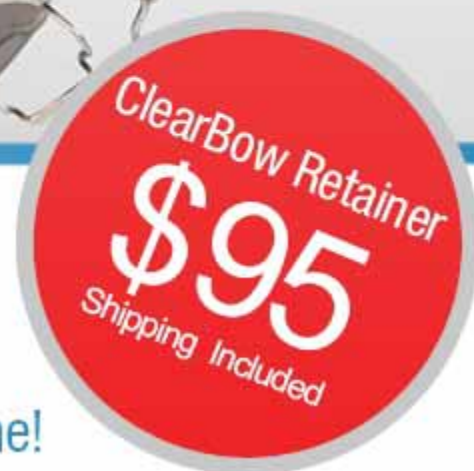GUARANTEED

The ClearBow will not break during normal retainer wear.

Redefining Durability

Introducing the new ClearBow retainer from Rideau Orthodontic Mfg. Ltd. The plastic stain resistant ClearBow has been tested over a time span of three years on more than 4,000 patients without a single breakage.

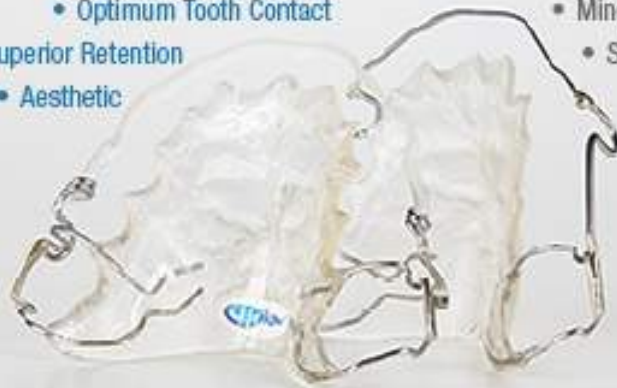The Choice is a Clear One!



LASER WELDED – No Discoloration OR Erosion

ClearBow Retainer

- Optimum Tooth Contact
- Superior Retention
- Aesthetic



Steel Wire Retainer

- Minor Tooth Contact
- Scratches Teeth
- "Unsightly (solder joints turn black over time)".

Rideau Orthodontic Mfg. Ltd.

69 Beckwith Street, North
Smiths Falls, Ontario, K7A 2B6
1-800-267-7982
www.orthodontic.ca
orthodontic@orthodontic.ca



SCAN THE QR CODE TO VIEW CLEARBOW VIDEO

NEW

ADVANTAGES



- Superior aesthetics = Increased patient compliance
- Optimum tooth contact = Superior retention
- Virtually unbreakable labial bow = More durable retainer
- Free from BPA = Healthier patients
- Gentle on teeth = The ClearBow does not scratch the teeth
- Unaffected by hot water = Easy to clean retainer
- Full labial contact = No relapse
- More hygienic = Happier patients
- 3 prong plier adjustable bow = Minor tooth movement



RIDEAU ORTHODONTIC MFG. LTD.

69 Beckwith Street North • Smiths Falls, ON • K7A 2B6

(613) 283-6841 • (800) 267-7982

www.orthodontic.ca • orthodontic@orthodontic.ca



NEXT DAY Courier
service provided by

 ***Purolator***

1-888-744-7123

Ship COLLECT under

Acct#3575071