



**Dr. Merle Bean
Pediatric Dentist
Des Moines, Iowa**

Dr. Merle D. Bean, DDS, is a graduate of the University of Iowa College of Dentistry and practiced for more than 35 years including orthodontics for two decades and TMJD therapy for fourteen years.

Dr. Bean studied under Dr. H. Wilson of London, England, Dr. David Liddle of the USA and Dr. Pierre Verdon of Paris, France.

Dr. Bean pioneered the reverse face mask treatment for maxillary advancement in the USA and CANADA.

**Dr. Merle Bean
12 hour Self-Instruction
CE Presentation**

\$495.00 U.S.

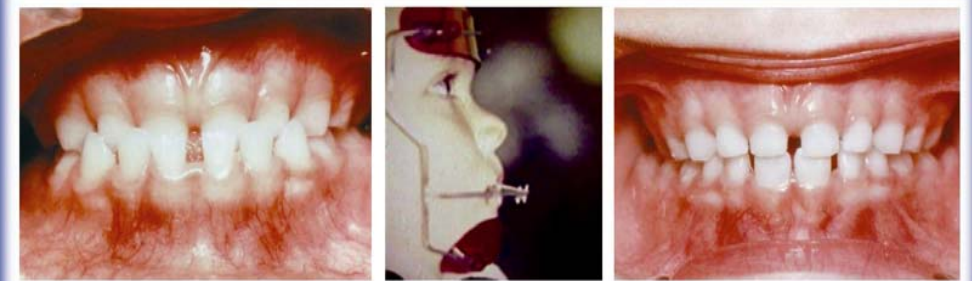
Dr. Merle Bean's detailed Orthopedic presentation is an invaluable educational and reference tool.

DVD includes a Chapter Reference Booklet to assist in case selection.

"MERLE'S PEARLS"

with Dr. Merle D. Bean
Pediatric Dentist
Des Moines, Iowa

Pioneer of the Reverse Face Mask Treatment
for Maxillary Advancement in the United States



"Merle's Pearls" with Dr. Merle D. Bean Pediatric Dentist Des Moines, Iowa

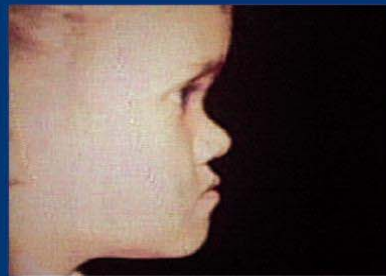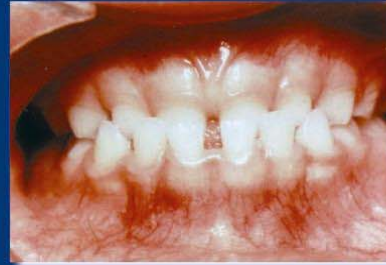Pioneer of the Reverse Face Mask Treatment for Maxillary Advancement in the United States

Over 12 Hours of Detailed Orthopedic Instruction:

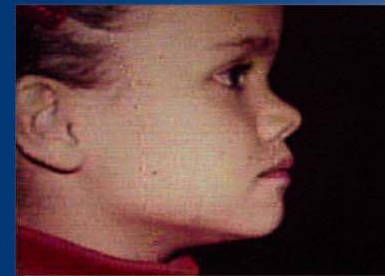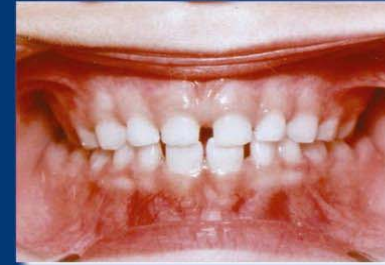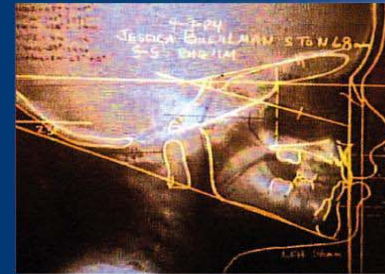
- Class I, II, and III Cases
- Pediatric, Youth and Adult Treatment
- TMJD
- Reverse Face Mask
- Functional Jaw Orthopedics
- Fixed Bracket Therapy
- Congenitally Missing Teeth
- Traditional vs. Functional Treatment
- Cephalometric Analysis
- 2nd Molar Replacement
- Surgical Extraction Techniques
- Uprighting of Wisdom Teeth
- Ectopic Surgical Corrections

And much more...

BEFORE:
SELLA TO NASION = 63mm



AFTER:
SELLA TO NASION = 68mm



Patient: Age 4 yrs 8 months, Class III

Treatment: Reverse Head Gear Labial/Lingual Fixed Appliance, 11 months

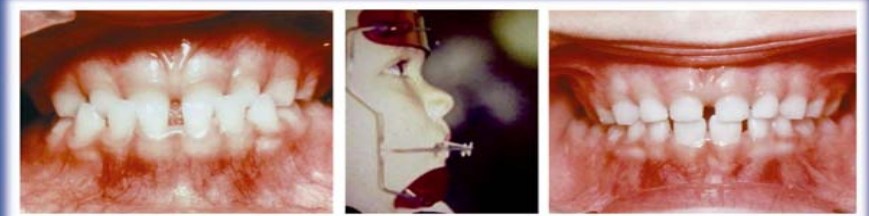
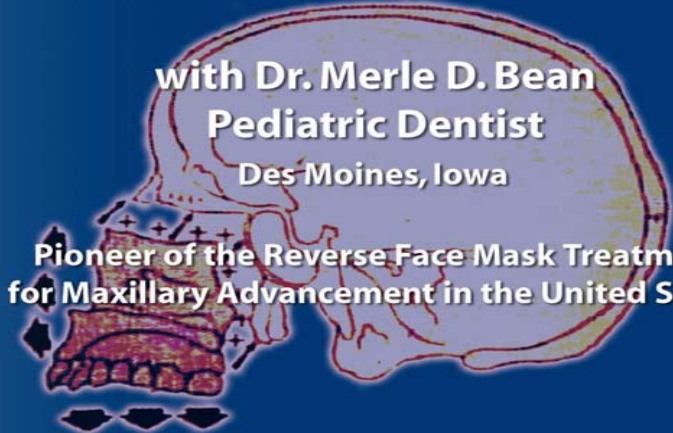
Please Contact
**Bonarch Supply
Canada Ltd.**
1-800-267-9225
Serving North America
bonarch@orthodontic.ca



"MERLE'S PEARLS"

with Dr. Merle D. Bean
Pediatric Dentist
Des Moines, Iowa

Pioneer of the Reverse Face Mask Treatment
for Maxillary Advancement in the United States



**This Self-Instruction video program is eligible for
12 Continuing Education Points upon completion of a Theory Test.**

"MERLE'S PEARLS"

Dr. Merle D. Bean
Pediatric Dentist
Des Moines, Iowa

A Pioneer of the Reverse Face Mask Treatment
for Maxillary Advancement in North America



DISC #1

- 1.01** Introduction of Dr. Merle Bean
- 1.02** **Pearl:** Facial Forms – Faces Before & After
- 1.03** **Pearl:** Sassouni “Plus” Cephalometric Analysis: Importance of determining the position of the Mx & Md
- 1.04** **Pearl:** Bowbeer Facial Analysis: The Five Keys to Facial Beauty & TMJ Health
- 1.05** **Pearl:** Dr. James McNamara: “82% of all Maxillas Retrude”
- 1.06** **Pearl:** Dr. R. T. Beistle: “The Maxilla is the Diagnostic Arch”
- 1.07** **Pearl:** Dr. Larry Funt: “The Maxilla is the Criminal. The Mandible is the Victim”
- 1.08** **Pearl:** The Size and Position of the Mx Relative to the Cranium hold the Secret to a Healthy TMJ and Good Face
- 1.09** **Pearl:** Best Time to Treat
- 1.10** **Patient:** Curtis 3yr 2mths
Classification: Class III
Treatment: Reverse Head Gear & 3 Screw Sagittal
- 1.11** **Pearl:** Henry Petite Facemask & Tongue Position is Critical to Mx retention.
- 1.12** **Patient:** Stephanie 5yrs 7 mths
Classification: Class III
Complication: Missing Mx anterior teeth due to sleeping with a bottle of milk
Treatment: Reverse Head Gear & Mx Schwartz

DISC #1

- 1.13 Pearl:** Reduce treatment time in Class III treatment by reducing cusp tips of lower cuspids
- 1.14 Patient:** Sybil 4yrs 7 mths
Classification: Class III
Complication: Four Md anterior teeth extracted
Treatment: Reverse Head Gear, Labial/Lingual Fixed Appliance
- 1.15 Pearl:** Cleft Palate
- 1.16 Pearl:** Function of a Facemask (Dr. Verdon & Delaire)
- 1.17 Patient:** Danielle 5 yrs 4 mths
Classification: Class III
Treatment: Reverse Head Gear, Labial/Lingual Fixed Appliance
- 1.18 Patient:** Kelly 9 yrs 5mths
Classification: Class III
Treatment: Reverse Head Gear, Mx Sagittal
- 1.19 Patient:** Josh 10 yrs 6mths
Classification: Class II
Complications: Poor tongue posture & swallowing habits
Treatment: Twin Block & Bionator
- 1.20 Patient:** Jessica 4 yrs 8 mths
Classification: Class III
Treatment: Reverse Head Gear, Labial/Lingual Fixed Appliance
- 1.21 Pearl:** Dr. Broadbent: Sella to Nasion Growth Measurements Ages 9-15

DISC #1

- 1.22 Patient:** Cyrus 5 yrs 2 mths
Classification: Class III
Treatment: Reverse Head Gear & Mx Sagittal
- 1.23 Pearl:** Wear facets on teeth is a diagnostic signal of TMJD
- 1.24 Pearl:** Class III Malocclusion: Types and Studies
- 1.25 Patient:** Lori 6 yrs 7mths
Classification: Class III
Treatment: Reverse Head Gear, Labial/Lingual Fixed Appliance
- 1.26 Pearl:** Precautions about Skin Irritations with Reverse Head Gear
- 1.27 Pearl:** Elastic Gauge Force
- 1.28 Treatment of Siblings:**
Patient: Suzanne 16yrs 2 mths
Classification: Class II Tendency
Treatment: 1st Bicuspid Removal & Straightwire
- Patient:** Mark 14 yrs 3 mths
Classification: Class I
Treatment: 2nd Molar Replacement, Sagittal & Reverse Head Gear
- 1.29 Patient:** Nick 11 yrs 7 mths
Classification: Class I Crowded
Complication: Congenitally Missing Mx & Md 8's in Right Quadrants

DISC #1

- 1.30 Pearl:** Evolution of Benefits of FJO: "The phenomenon of FJO will not disappear."
- 1.31 Patient:** Heather 10 yrs 3 mths
Classification: Class II Division II
Treatment: Mx Sagittal, Mx Split Hawley, Mx Sagittal, 2nd Molar Replacement
- 1.32 Patient:** Tracie 11 years
Classification: Class I Crowded
Treatment: Sagittal, Straightwire, Mx 2nd Molar Replacement
- 1.33 Pearl:** Benefits of 2nd molar replacement as a form of retention to eliminate the mesial force of their eruption.
- 1.34 Pearl:** Dr. David Liddle, December 1977 American Journal of Orthodontics: Second Molar Extraction in Orthodontic Treatment
- 1.35 Patient:** Christy 13 yrs 6 mths
Classification: Class II
Complication: Arrived with prior Mx 1st and 2nd bicuspid extractions & Md 1st bicuspid extractions performed at a specialist's office.
Treatment: Md Lower Wisdom Tooth Removal
- 1.36 Patient:** Jana 17 yrs 1 mth
Classification: Class I
Complication: Arrived with prior four 1st bicuspid extractions performed at a specialist's office.
Treatment: No treatment – records only

DISC #1

- 1.37 Patient:** Female 18 yrs
Classification: Class II
Complication: Arrived at office at end of treatment performed by an orthodontist. 3 years of Headgear and 4 Bicuspid removed
Treatment: No Treatment - Records Only
- 1.38 Pearl:** Reconstruction of deciduous teeth with ramped caries.
- 1.39 Pearl:** Tongue Frenectomy
- 1.40 Patient:** Patty 10 yrs 4 mths (Continued on Disc 2)
Classification: Class I Crowded
Treatment: 2nd Molar Replacement, Sagittals & Straightwire
- - DISC #2 -
- 2.01 Patient:** Shane 11 yrs 4 mths
Classification: Class I
Complication: Impacted Lateral, Cyst, Impacted 2nd Molar
Treatment: Hawley with Steel Ligature Wire
- 2.02 Patient:** Jessica 10 yrs 3 mths
Classification: Class I Crowded – Mixed Dentition
Treatment: Mx Sagittals, 2nd Molar Replacement
- 2.03 Pearl:** Timing of 2nd Molar Replacement and Benefits of a Mx Sagittal

DISC #2

- 2.04** Patient: Julie 9 yrs 5 mths
Classification: Class I Crowded
Complication: Blocked Out Cuspids
Treatment: Mx Sagittal, Md Lingual Arch, Md Sagittal, Straightwire, 2nd Molar Replacement
- 2.05** Patient: Brett 15 yrs 5 mths
Classification: Class I
Complication: Poor Eruption of Wisdom Teeth following 2nd Molar Replacement
Treatment: Uprighting Wisdom Teeth
- 2.06** Patient: James 13 yrs 2 mths
Classification: Class I
Complication: Impacted Lower 2nd Molars
Treatment: Sagittals, Uprighting of Md 2nd Molars
- 2.07** Patient: Tami 11 yrs 4 mths
Classification: Class I
Treatment: Rapid Palatal Expansion, 2nd Molar Replacement, Bionator, Schwartz
- 2.08** Patient: Gail 10 yrs 6 mths
Classification: Class I
Complications: Impacted Upper Left Central
Treatment: Expansion, Hawley with elastic
- 2.09** Patient: Elizabeth 10 yrs 3 mths
Classification: Class I
Complications: Supernumerary, Impacted Upper Right Central & Cyst
Treatment: Expansion, Hawley with Steel Ligature Wire

DISC #2

- 2.10** Patient: Mat 8 yrs
Classification: Class I
Complications: Supernumerary, Impacted Upper Left Central and Lateral
Treatment: Expansion, Hawley with Steel Ligature Wire
- 2.11** Patient: Donna 11 yrs
Classification: Class II
Treatment: 2x4 Mechanics, Mx Sagittal, Bionator, 2nd Molar Replacement
- 2.12** Pearl: Eruption of Wisdom Teeth – Twins Study – 14 yrs
- 2.13** Patient: Lori 10 yrs 10 mths
Classification: Class I Crowded
Treatment: Md 2x4 Mechanics, Mx Sagittal, Bionator, 2nd Molar Replacement
- 2.14** Patient: Allison 6 yrs 5 mths
Classification: Class II – Severe
Treatment: Bionator
- 2.15** Patient: Alan 14 yrs
Classification: Class I Crowded
Treatment: 2nd Molar Replacement, Mx&Md Sagittals, Straightwire
- 2.16** Patient: Jennifer 14 yrs 9 mths
Classification: Class I Crowded
Treatment: 2nd Molar Replacement, Mx Sagittal, Md Jackson, Hawley, Tooth Positioner

DISC #2

- 2.17** Patient: Billy 11 years 11 mths
Classification: Class II
Complication: Blocked out cuspids
Treatment: Mx Sagittal, Md Utility Arch, BioFinisher, Straightwire
- 2.18** Patient: Kim 14 yrs 8 mths
Classification: Class I Crowded
Complication: Congenitally missing lower right wisdom tooth
Treatment: Rapid Palatal Expansion, 2nd Molar Replacement in Three Quadrants, Facemask, Straightwire, Bionator
- 2.19** Pearl: Construction Bite for a Bionator
- 2.20** Patient: Jade 7 yrs 6 mths
Classification: Class I - Open Bite
Complication: Tongue Thrust
Treatment: Bionator II, Md Lip Bumper
- 2.21** Patient: Erica 8 yrs 3 mths
Classification: Class I
Treatment: Mx Sagittal, Bionator to Close, Mx Utility Arch, Straightwire, 2nd Molar Replacement
- 2.22** Patient: Amy 9 yrs
Classification: Class II
Treatment: Lower Lingual Arch, Mx Schwartz, Mx Sagittal, 2nd Molar Replacement, Straightwire, Bionator

DISC #2 - DISC #3

- 2.23** Patient: Stephanie 8 yrs 5 mths
Classification: Class I
Complication: Open Bite
Treatment: Rapid Palatal Expansion, Hawley, 2nd Molar Replacement (Surgical technique)
- 2.24** Pearl: Spontaneous Eruption of Wisdom Teeth following 2nd Molar Replacement Treatment - 3 Case Studies

----- - DISC #3 -

- 3.01** Patient: Alicia 4 yrs 7 mths
Classification: Class III
Complication: Tongue Thrust
Treatment: Rapid Palatal Expansion, Reverse Head Gear
- 3.02** Patient: Hillary 11 yrs 8 mths
Classification: Class III
Complication: Requires future Md Surgery
Treatment: Reverse Head Gear, Straightwire
- 3.03** Patient: Rebecca 28 yrs 7 mths
Classification: Class III
Complications: TMJD, Missing Lower Right 1st Molar
Treatment: Mx Sagittal, Reverse Head Gear, Straightwire, BioFinisher, Wisdom Tooth Removal
- 3.04** Pearl: How does Vertical Dimension effect A-Point?

DISC #3

- 3.05** Patient: Rick 30 yrs
Classification: Class III
Complication: Wore reverse head gear faithfully and created 8mm overjet and class II malocclusion (Dramatic Changes)
Treatment: Straightwire, Reverse Head Gear
- 3.06** Patient: Trevor 8 yrs 5 mths
Classification: Class III
Complication: Laterals in Crossbite
Treatment: Hyrax, Reverse Head Gear, Lip Bumper
- 3.07** Patient: Marcus 11 yrs 5 mths
Classification: Class I Crowded – Class III Tendency
Treatment: Mx Sagittals, Reverse Head Gear, Future Wisdom Tooth Removal
- 3.08** Patient: Cathy 5 yrs 5 mths
Classification: Class III
Treatment: Mx Sagittal with Labial Flange, Reverse Head Gear, Assisted Guidance of Md
- 3.09** Pearl: Reverse Head Gear & Elastic Forces
- 3.10** Pearl: Merle's Philosophy of Orthodontics
- 3.11** Patient: Kinseth 11 yrs 4 mths
Classification: Class I Crowded
Treatment: Mx & Md Sagittals, 2nd Molar Replacement, Straightwire
- 3.12** Pearl: Effects of Sagittal Treatment combined with Timing of 2nd Molar Replacement

DISC #3

- 3.13** Patient: Kris 11 yrs 3 mths
Classification: Class II Half Tooth
Complication: Open Bite
Treatment: Lower Lingual Holding Arch, 2nd Molar Replacement
- 3.14** Pearl: Surgical Technique for 2nd Molar Removal
- 3.15** Pearl: 2nd molar roots are many times inferior to 3rd molar roots.
- 3.16** Patient: Tami 13 yrs 10 mths
Classification: Class I Crowded
Complication: Compromise Treatment
Treatment: Mx Sagittals, 2nd Molar Replacement
- 3.17** Patient: Lisa 12 yrs 10 mths
Classification: Class I Crowded
Complication: Compromise Treatment
Treatment: 2nd Molar Replacement, Mx Sagittal, Straightwire, Bionator
- 3.18** Pearl: Caution regarding removal of a retained deciduous tooth: Hemangioma
- 3.19** Pearl: Distalization of 1st Molars following 2nd Molar Replacement
- 3.20** Pearl: 2nd Molar Removal vs. Bicuspid Removal
- 3.21** Patient: Gina 10 yrs 8 mths
Classification: Class I Crowded
Complication: TMJD, Deep Bite
Treatment: Mx Sagittal, Straightwire, Bionator, Future 2nd Molar Replacement

DISC #3

- 3.22** Patient: Ruth 12 yrs 4 mths
Classification: Class I Crowded
Treatment: Mx Sagittal, Md 2nd Molar Replacement, Straightwire, Mx 2nd Molar Replacement
- 3.23** Patient: Stephanie 17 yrs 8 mths
Classification: Class I Crowded
Complication: Patient did not return for completion of treatment
Treatment: Right Quadrant 2nd Molar Replacement
- 3.24** Pearl: Decayed 2nd Molars
- 3.25** Patient: Bobby 14 yrs 2 mths
Classification: Class II
Treatment: BioFinisher, Bionator, 2nd Molar Replacement
- 3.26** Patient: Annette 10 yrs 8 mths
Classification: Class II
Treatment: 2nd Molar Replacement, Mx Sagittal, Bionator to Open, Bionator to Close
- 3.27** Pearl: Effects of the Herbst Appliance
- 3.28** Patient: Jackie 13 yrs 2 mths
Classification: Class III
Complication: Received prior orthodontic treatment with a Dual Block
Treatment: Mx Split Hawley, Md Fixed, Reverse Head Gear, Md 2nd Molar Replacement
- 3.29** Pearl: Uprighting of Impacted 3rd Molars
- 3.30** Pearl: Long-term Results following 2nd Molar Replacement

DISC #3 - DISC #4

- 3.31** Patient: Mike 10 yrs
Classification: Class II
Complication: Mouth Breather
Treatment: Chin Cup, Removal of Deciduous Anterior Teeth, Mx Split Hawley, 2x4 Mechanics, Reverse Head Gear, Straightwire
- 3.32** Pearl: Facemask Designs
- 3.33** Patient: Melissa 9 yrs 8 mths
Classification: Class II
Complications: Medical Complications and Strong Md Frenum
Treatment: Schwartz, Reverse Head Gear, Twin Block
- 3.34** Patient: Valerie 8 yrs 11 mths
Classification: Class II
Treatment: Twin Block
- 3.35** Patient: Emily 7 yrs 3 mths (Continued on Disc 4)
Classification: Class II
Complication: Fractured Both Condyles
Treatment: Mx Sagittal & Twin Block

----- - DISC #4 -

- 4.01** Patient: J.D. 13 yrs
Classification: Class II
Complications: Poor Enamel, Congenitally missing lower centrals
Treatment: Bionator

DISC #4

- 4.02** Patient: Chrissie 11 yrs 4 mths
Classification: Class II
Complications: Congenitally missing lower laterals , Peg Upper right lateral
Treatment: Orthopedic Corrector, Twin Block
- 4.03** Pearl: Comparison between the Twin Block & Bionator
- 4.04** Patient: Curtis 13 yrs
Classification: Class II Deep Bite
Complication: Handicapped/Seizures
Treatment: Bionator, Removal of deciduous molars, Twin Block
- 4.05** Patient: Katie 13 yrs 7 mths
Classification: Class II
Complications: TMJD, Congenitally missing Mx lateral, Md central, Peg Md lateral
Treatment: Straightwire & Bionator
- 4.06** Patient: Michael 14 yrs 6 mths
Classification: Class I
Complication: Arrived with four cuspids removed
Treatment: 2nd Molar Replacement, Straightwire, Wisdom Tooth Removal
- 4.07** Patient: Jon 10 yrs 2 mths
Classification: Class I
Treatment: 2nd Molar Replacement, Mx Sagittal, Md Straightwire
- 4.08** Pearl: Mandibular Cyst

DISC #4

- 4.09** Patient: Kevin 18 yrs 1 mth
Classification: Class I
Complication: Prior 2nd Molar Replacement – Lower left wisdom tooth impacted
Treatment: Surgical uprighting of wisdom tooth
- 4.10** Patient: Carl 16 yrs 8 mths
Classification: Class III
Complication: Prior case finished in Class I. Patient's mandibular arch grew resulting in Class III
Treatment: Lower 1st molar removal to allow 2nd molars to move mesial, Md Straightwire, Retraction of bicuspid
- 4.11** Patient: Francisca 34 yrs (Remarkable Changes)
Classification: Class II
Complication: Severe TMJD
Treatment: Splint, Bionator, surgery of coronoid process, removal of left disk and right disk arthroplasty.
- 4.12** Patient: Lisa 10 yrs 3 mths
Classification: Class II
Complication: TMJD
Treatment: Sagittal, Bionator, Straightwire, Surgical removal of Coronoid Process
- 4.13** Patient: Gina 8 yrs 6 mths
Classification: Class II Division II
Complication: TMJD
Treatment: Hawley, Bionator

DISC #4

- 4.14** Patient: Robin 8 yrs 7 mths
Classification: Class II
Complication: Congenitally missing numerous teeth, peg teeth
Treatment: Twin Block
- 4.15** Patient: Jessica 11 yrs 4 mths
Classification: Class I
Complication: Congenitally missing 23 teeth
Treatment: Transverse development, Reverse Head Gear
- 4.16** Patient: Denise 36 yrs
Classification: Class II
Complications: TMJD, U/R 2nd Bicuspid Removed
Treatment: Remove Md 1st Bicuspids, Mx Sagittal, Straightwire, Reverse Head Gear, Air Rotor Slenderizing
- 4.17** Patient: Diane 17 yrs 6 mths
Classification: Class III
Complication: Requires Orthognathic Surgery
Treatment: Straightwire, Md Surgical Advancement
- 4.18** Patient: Kyla 13 yrs 6 mths
Classification: Class I (Class III Skeletal)
Complication: Slightly blocked out Cuspids
Treatment: Mx Sagittal, Reverse Head Gear, Straightwire
- 4.19** Pearl: Mandibular Growth Direction

DISC #4

- 4.20** Patient: Craig 11 yrs 10 mths
Classification: Class III
Treatment: Mx Sagittal, Reverse Head Gear, Straightwire
- 4.21** Patient: Katie 7 yrs 4 mths
Classification: Class III
Treatment: Rapid Palatal Expansion, Reverse Head Gear
- 4.22** Patient: Charlie 9 yrs 7 mths
Classification: Class III
Treatment: Rapid Palatal Expansion, Reverse Head Gear, Mx Sagittal, Mx Straightwire, 2nd Molar Replacement, Frankel III
- 4.23** Patient: Amy 9 yrs 9 mths
Classification: Class II Division II – Skeletal Class III
Complication: Congenitally missing lower 2nd Bicuspids
Treatment: Mx Sagittal, Reverse Head Gear, Mx 2x4 Mechanics, 2nd Molar Replacement
- 4.24** Pearl: Fathers of Functional Orthopedics: Drs. Frankel, Stockfish, Planas, Bimler and Petrovic
- 4.25** Patient: Julie 17 yrs 3 mths
Classification: Class III
Complication: Open Bite, Large Tongue
Treatment: Mx 2nd Molar Replacement, Md 1st Molar Replacement, Mx Sagittal,

DISC #4

- 4.26** Patient: Angela 16 yrs 9 mths
Classification: Class III
Complications: TMJD & Open Bite
Treatment: Rapid Palatal Expansion, Reverse Head Gear, Mx Sagittal, Straightwire, Md 1st Molar Replacement, Mx 2nd Molar Replacement, Frankel III
- 4.27** Patient: Rob 14 yrs 6 mths
Classification: Class III
Complication: TMJD
Treatment: Sagittal, Reverse Head Gear, Utility Arch, Straightwire
- 4.28** Pearl: Wits Analysis
- 4.29** Pearl: Healthy Temporomandibular Joint Position
- 4.30** Patient: Ray 41 yrs
Classification: Class II – Closed Bite
Complication: TMJD
Treatment: Mx Sagittal, Straightwire, Bionator
- 4.31** Patient: Heather 19 yrs 3 mths
Classification: Class II
Complication: TMJD Post Orthodontic Treatment by a Specialist
Treatment: 2nd Molar Removal, Mx Schwartz, Md Sagittal, Straightwire
- 4.32** Patient: Daniel 19 yrs 3 mths
Classification: Class II
Complications: TMJD, Compromised Enamel, Prior treatment by Orthodontist & Oral Surgeon
Treatment: Rapid Palatal Expansion, Orthopedic Corrector, Jackson Appliance

DISC #4

- 4.33** Pearl: Dr. Donald Woodside, Orthodontist, University of Toronto
- 4.34** Patient: Kate 31 yrs
Classification: Class II
Complication: TMJD
Treatment: BioFinisher
- 4.35** Patient: Lori 23 yrs 6 mths
Classification: Class II Division I
Complications: Had four bicuspids removed early in life, TMJD
Treatment: Twin Block
- 4.36** Patient: Jana 34 yrs
Classification: Class II Division II
Complication: TMJD, Prior removal of all four 2nd bicuspids.
Treatment: Mx Sagittal, Md Gelb Splint, Mx Fixed, BioFinisher
- 4.37** Patient: Vickie 37 yrs
Classification: Class I
Complication: TMJD, L/R 1st molar and U/L 1st molar removed
Treatment: Mx Sagittal
- 4.38** Pearl: Research on Condylar Change

“MERLE’S PEARLS”


Presented by Dr. Merle D. Bean
Pediatric Dentist

12 Hour Video Presentation Order Form

BILLING AND SHIP TO ADDRESS:

Dr. _____ Specialty: _____
Office Address: _____
City: _____ State/Province: _____
Zip/Postal Code: _____ Country: _____
Office: (_____) _____ - _____ Fax: (_____) _____ - _____
E-mail Address: _____ Office Contact: _____

PAYMENT DETAILS:

Credit Card:  

Card#: _____ Expiry Date: ____/____/____

Cardholder Name: _____

Cardholder Signature: _____

Authorized Distributor:

Bonarch Supply Canada Ltd.

71 Beckwith Street, North Smiths Falls, ON K7A 2B6

Tel: 800-267-9225 Fax: 613-283-5386

bonarch@orthodontic.ca www.orthodontic.ca

ADAC•E•R•P®
CONTINUING EDUCATION RECOGNITION PROGRAM

