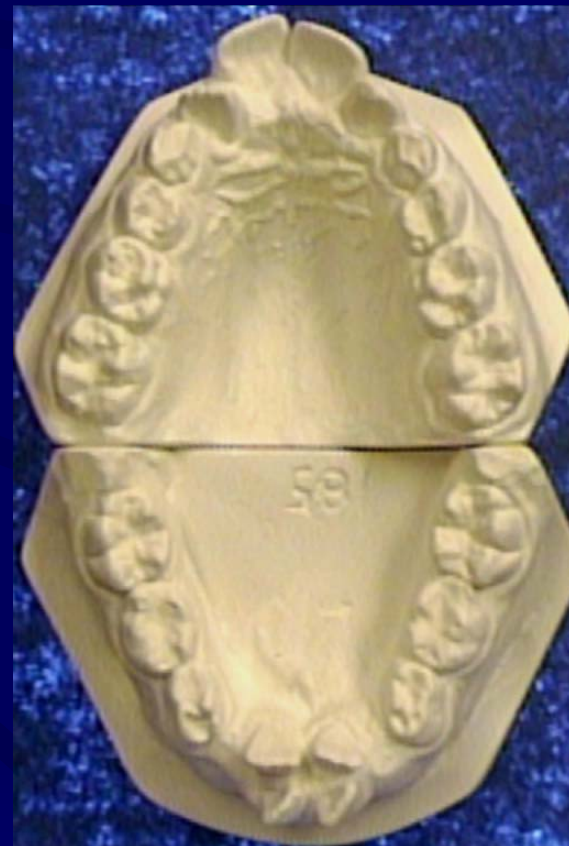
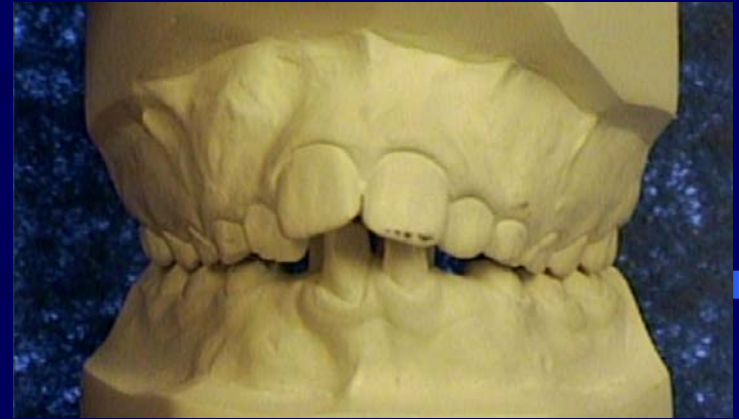
CASE PRESENTATION

**Provided by a General Dentist
from
Trinity Bay, Newfoundland**

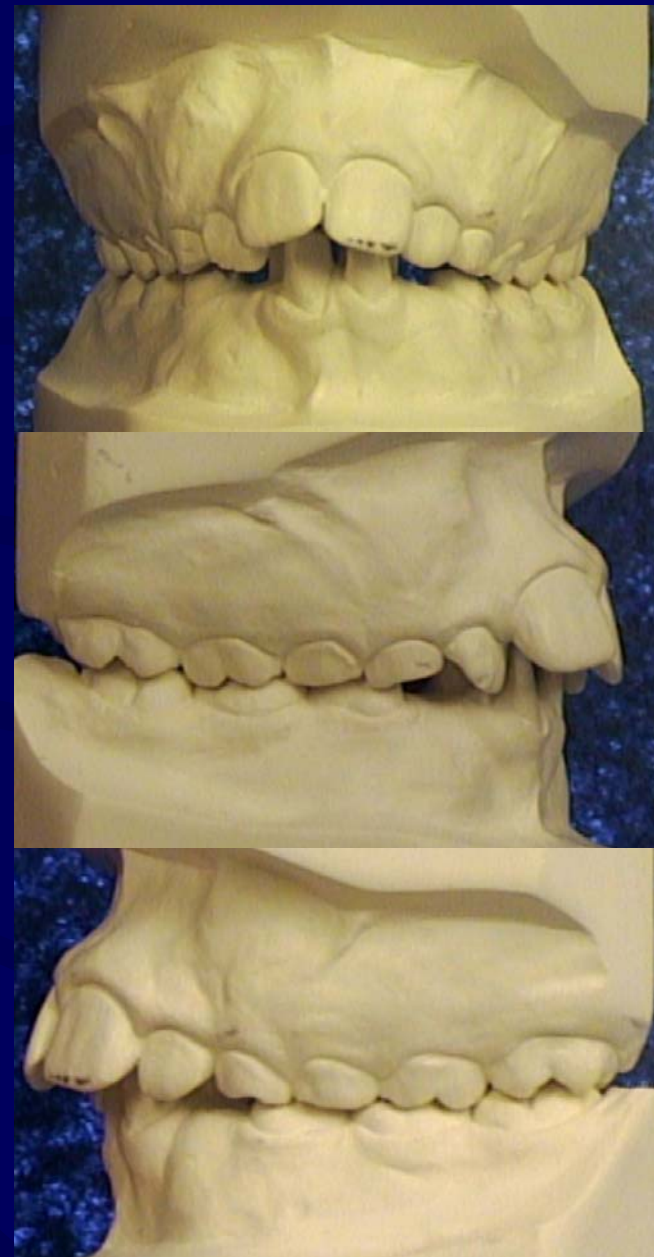Class I - Crowded

Ryan: 10 years of age

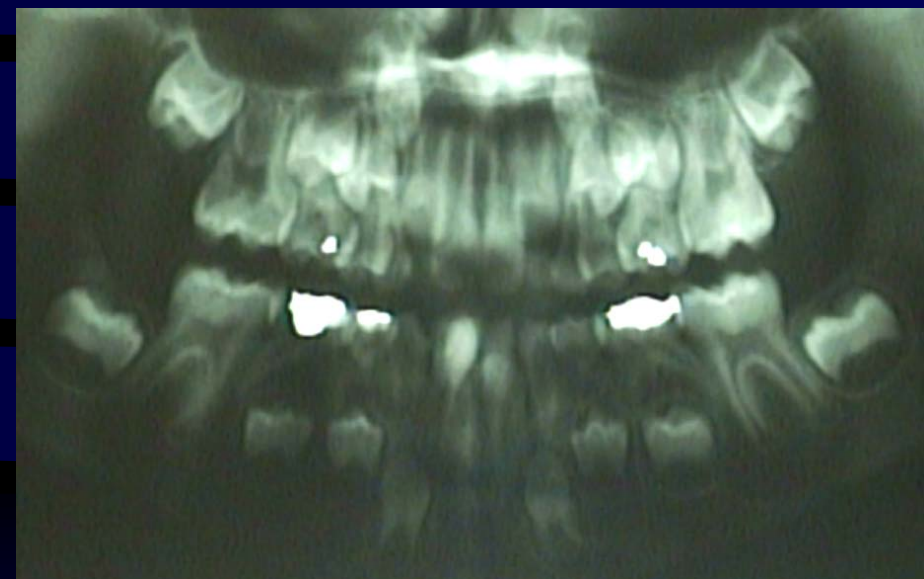


Pre-Treatment

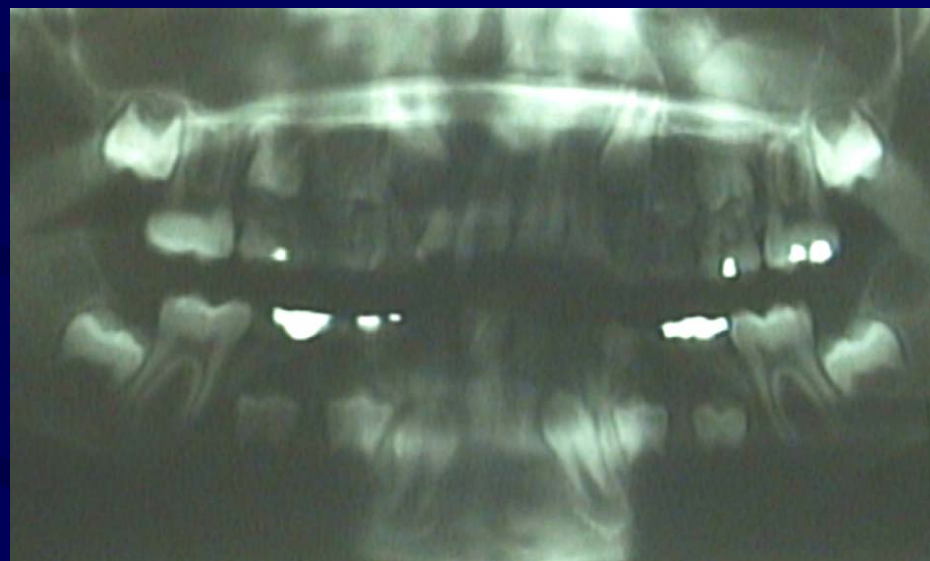- Dental:
 - Class I Crowded
 - Dentally Immature
 - Constricted Mx
 - V-shaped Maxilla
 - Deep Bite
 - Badly malaligned upper and lower incisors



Pre-Treatment Panorex

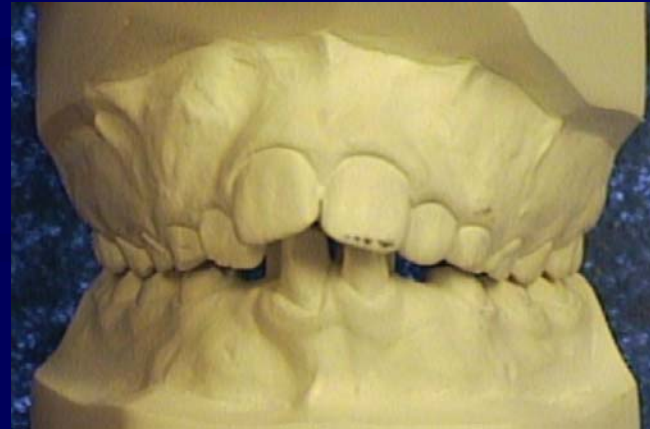

1998



1999

Treatment Objectives



- Develop the Mx and Md Arches transversely
 - Preserve the lower deciduous molar space
- Perform 2nd molar replacement to control vertical
 - Fixed Brackets to align the arches
 - Retention

Treatment Plan

Phase I:

- Mx & Md Schwartz

Phase II:

- 2nd Molar Replacement
- Mx 3-Screw Schwartz & Md Bowbeer appliance

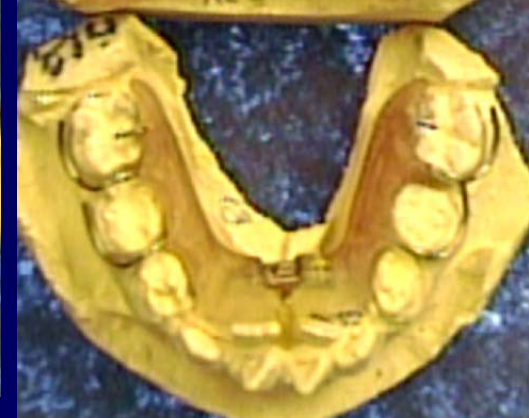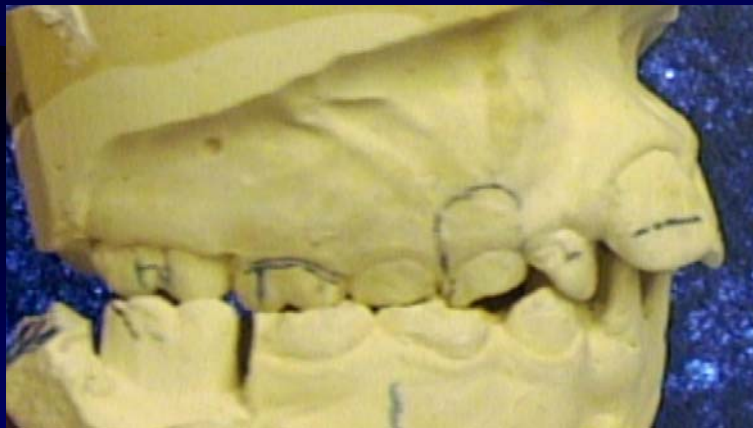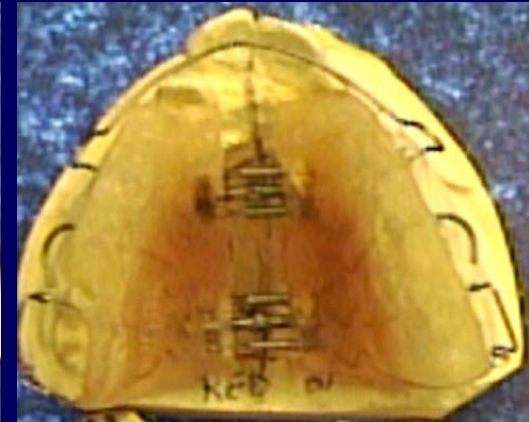
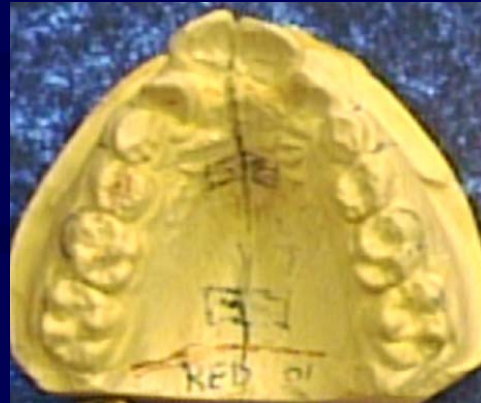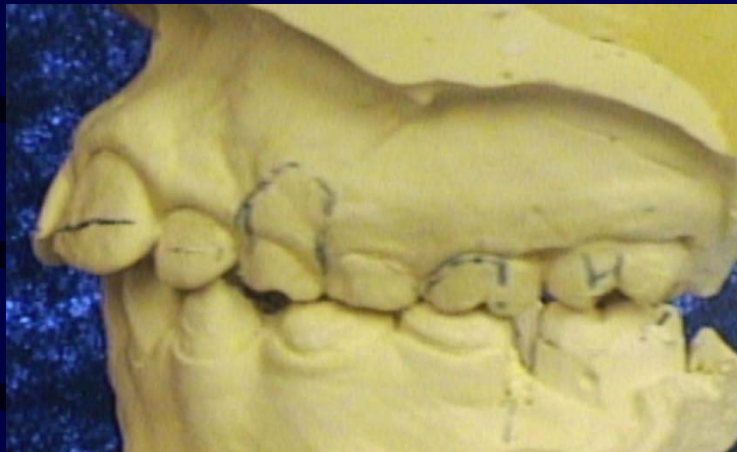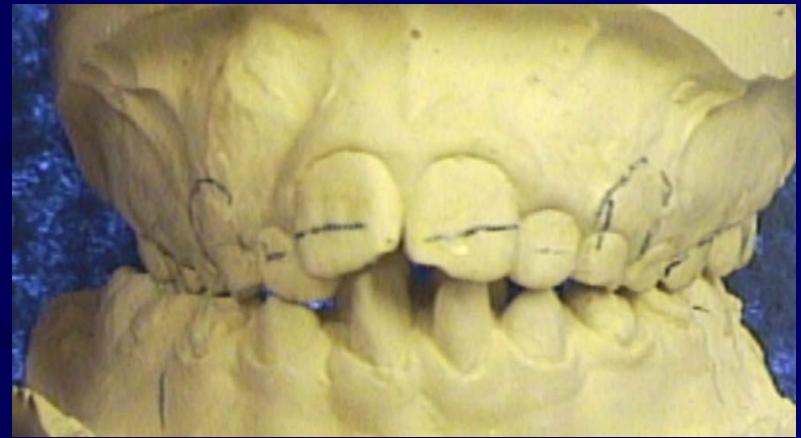
Phase III:

- Fixed Bracket Therapy

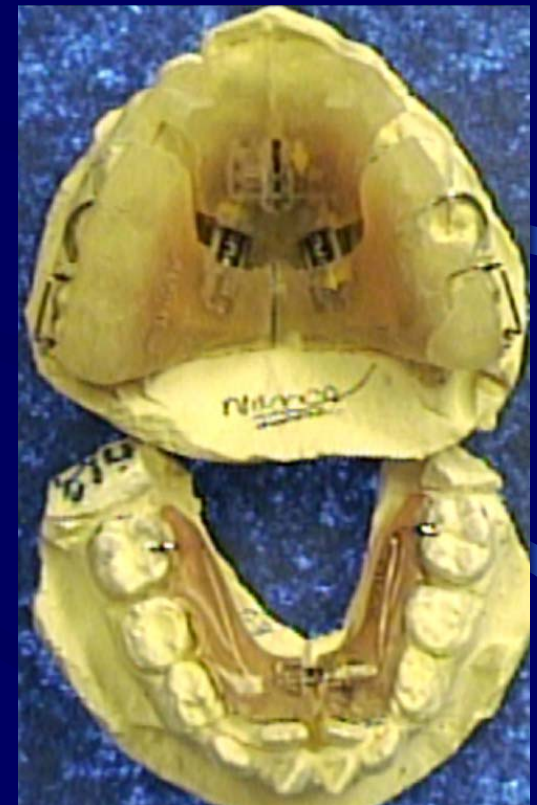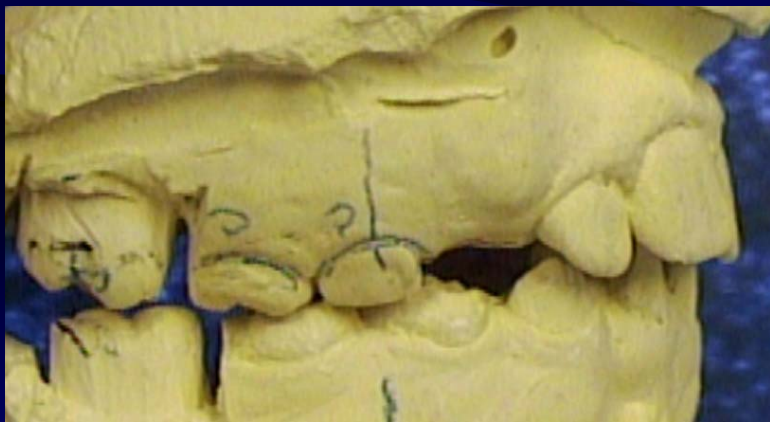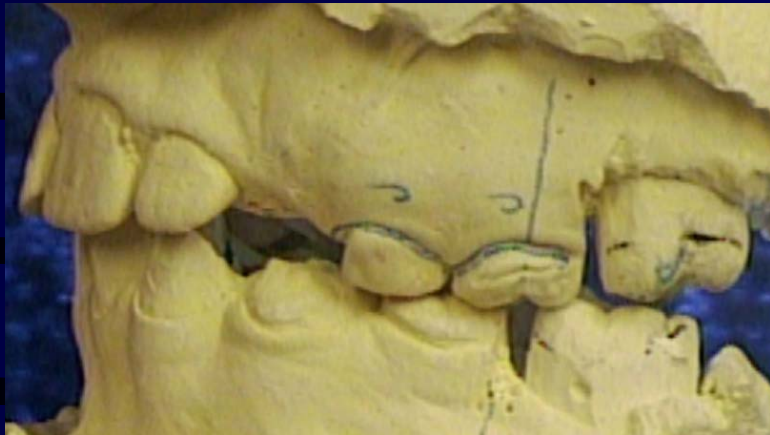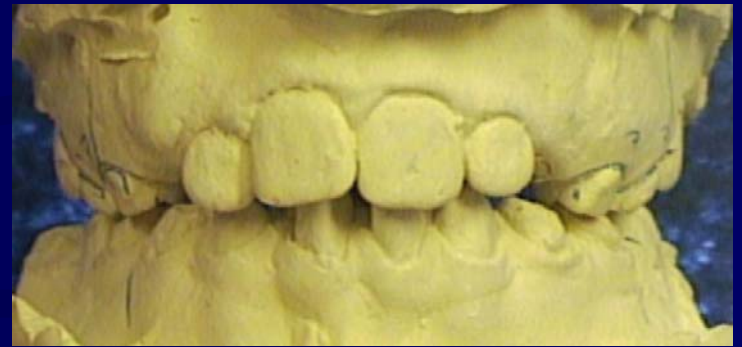Retention:

- Mx Hawley & Md 3x3 Retainer

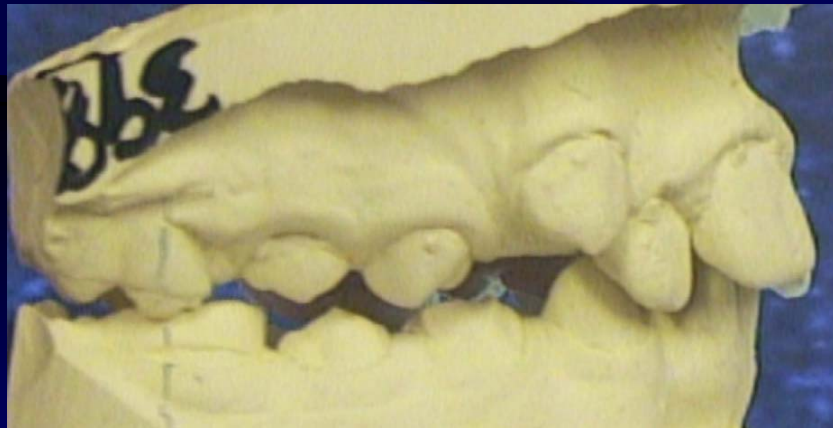
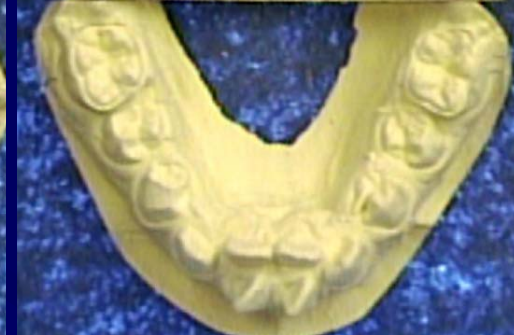
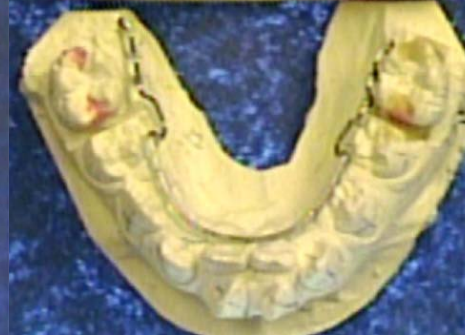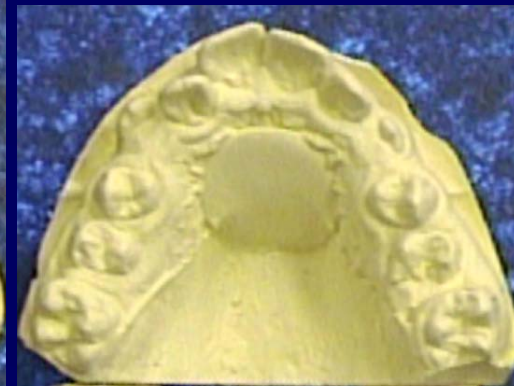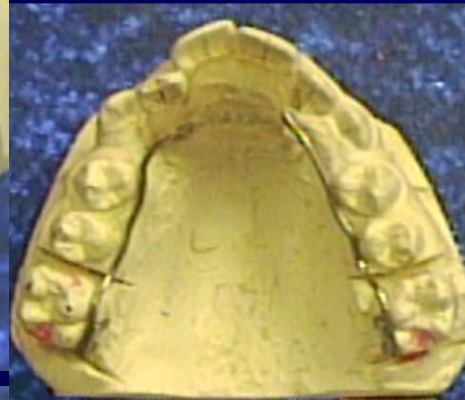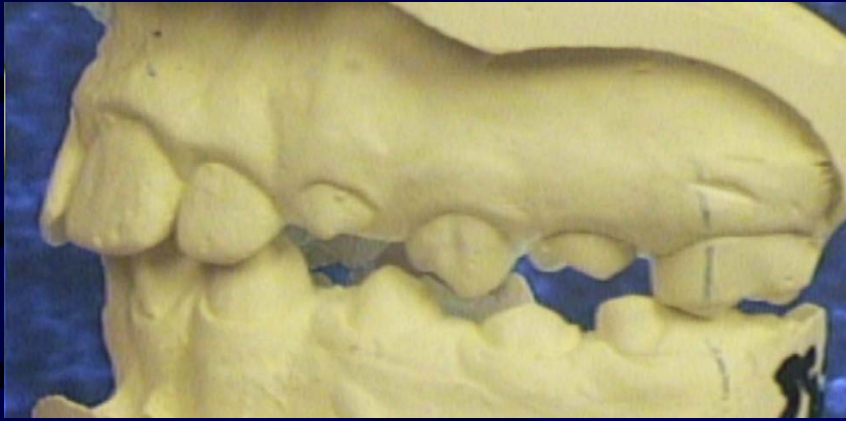
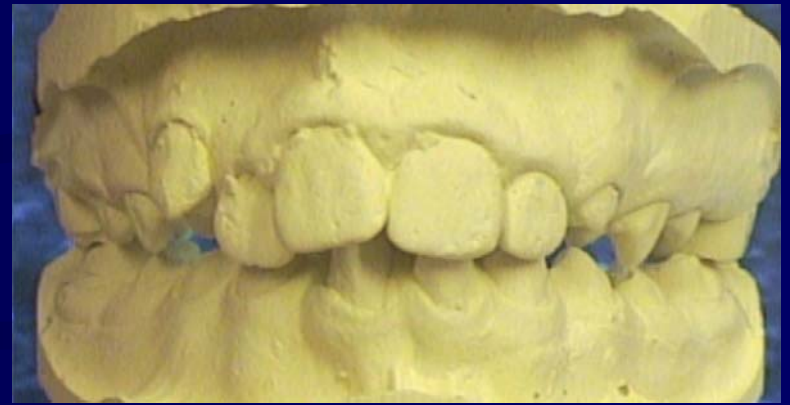Mx & Md Schwartz



Mx 3-Screw Sagittal & Md Bowbeer



Mx Nance Button & Md Lingual Arch



Case Treatment Summary

Ryan: 10 years of age

Phase I - 4 mths: Mx & Md Schwartz

Phase II - 6 mths: Mx 3-Screw Schwartz & Md Bowbeer

Phase III - 3 months: Mx Schwartz Plate

Phase IV: 9 months

Mx Nance Button & Md Lingual Arch

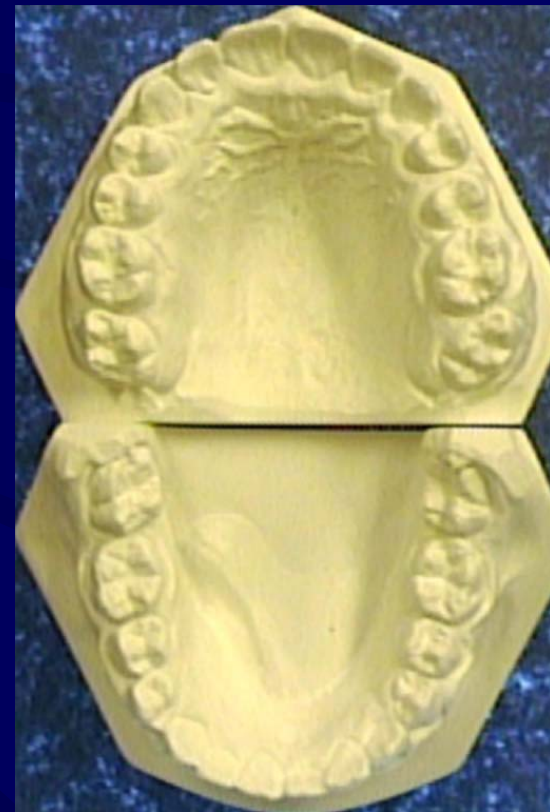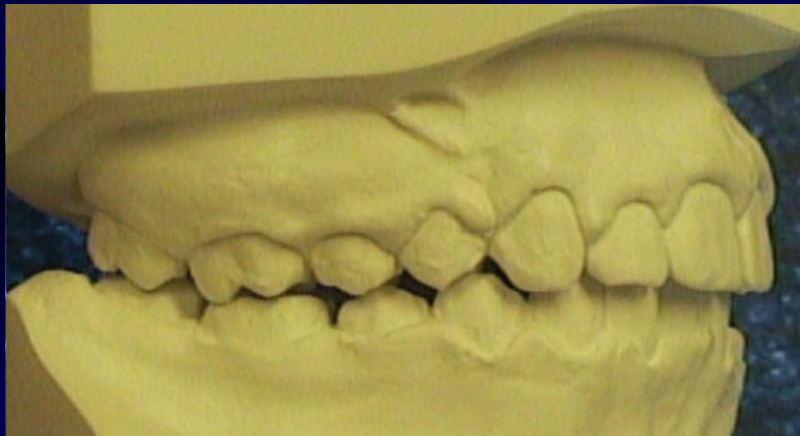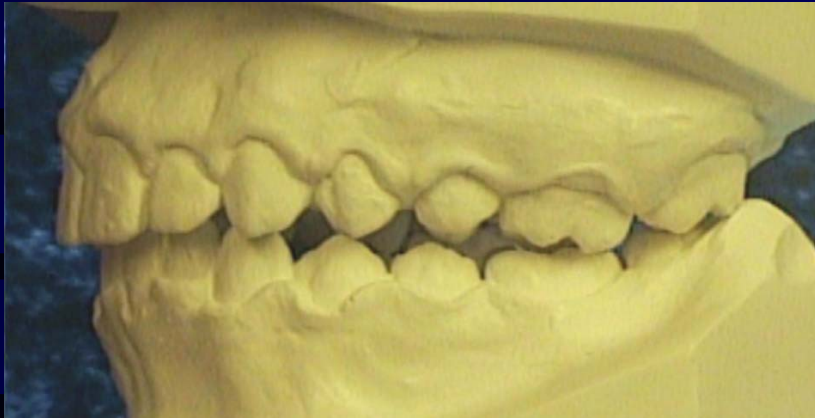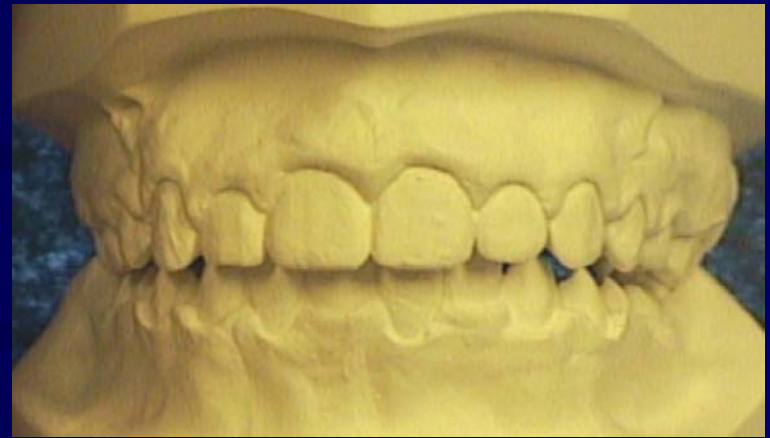Phase V: 8 months

Fixed Bracket Therapy, Wilson Lingual Arch & Wilson Bite Plane

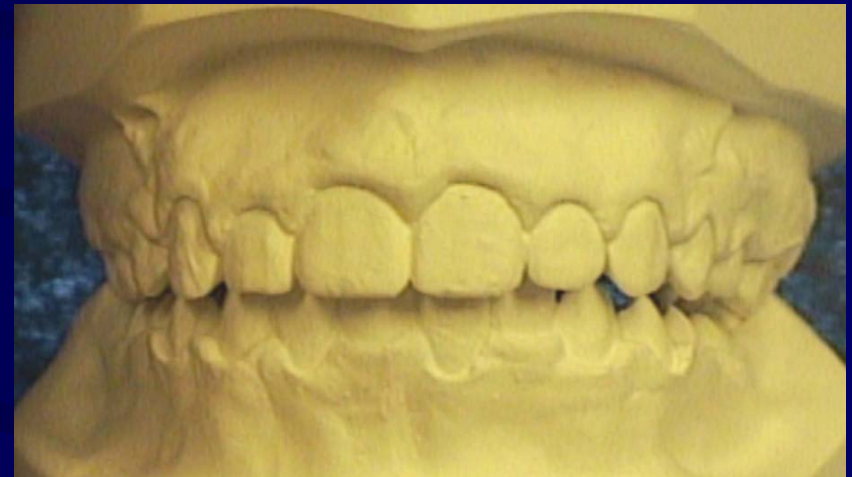
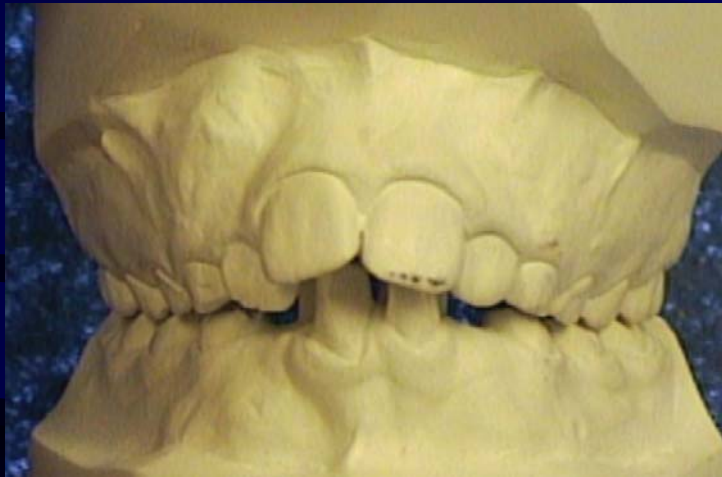Total Treatment Time - 31 months (2.4 yrs)

Retention: Mx Hawley with a flat anterior bite plane (5yrs to sleep)
& Md 3x3 Retainer (3yrs)

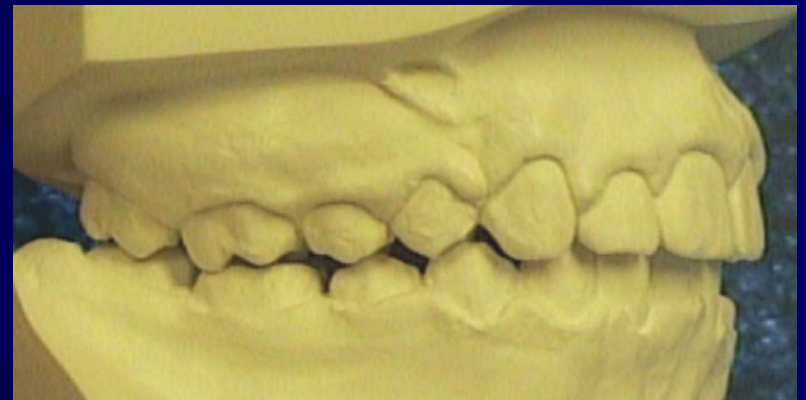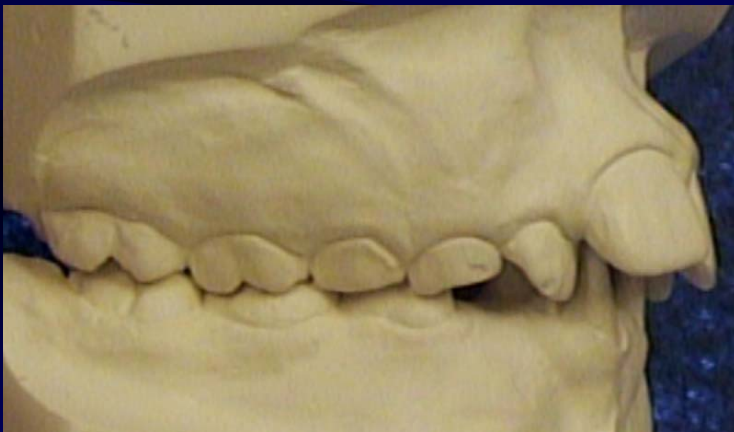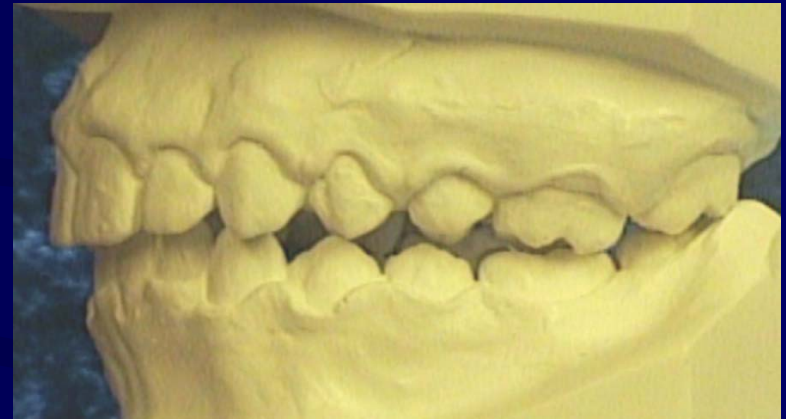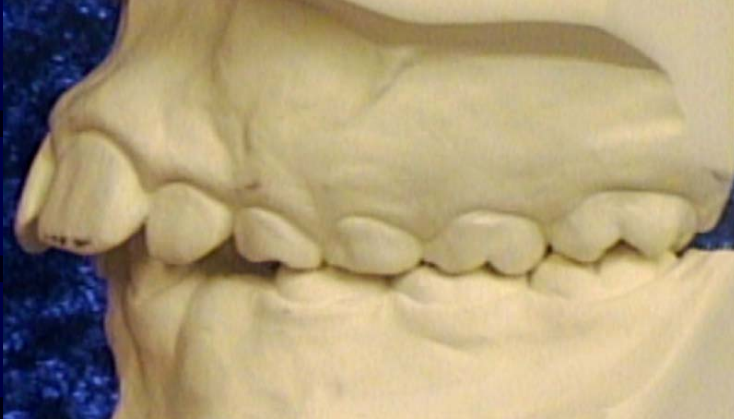Finished Treatment



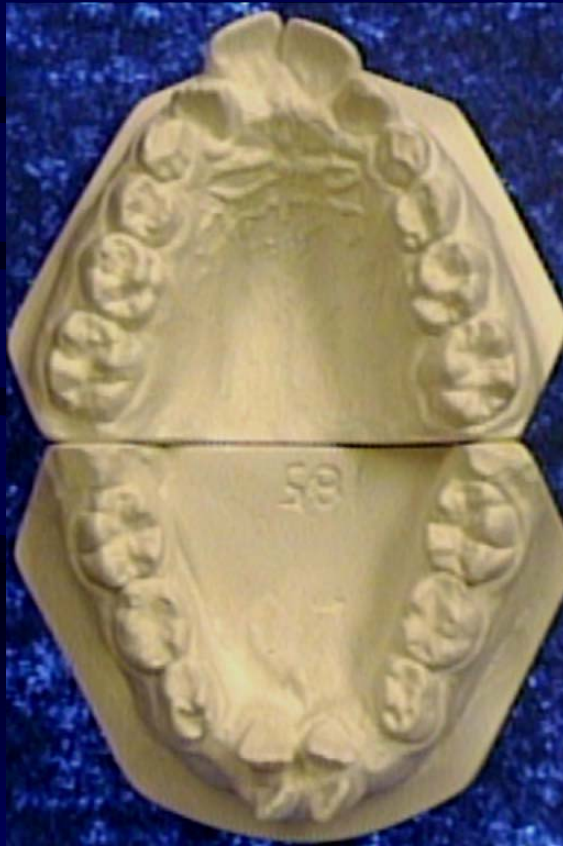Pre & Post Treatment



Pre & Post Treatment



Pre & Post Treatment



Doctor's Comments

Complications During Treatment:

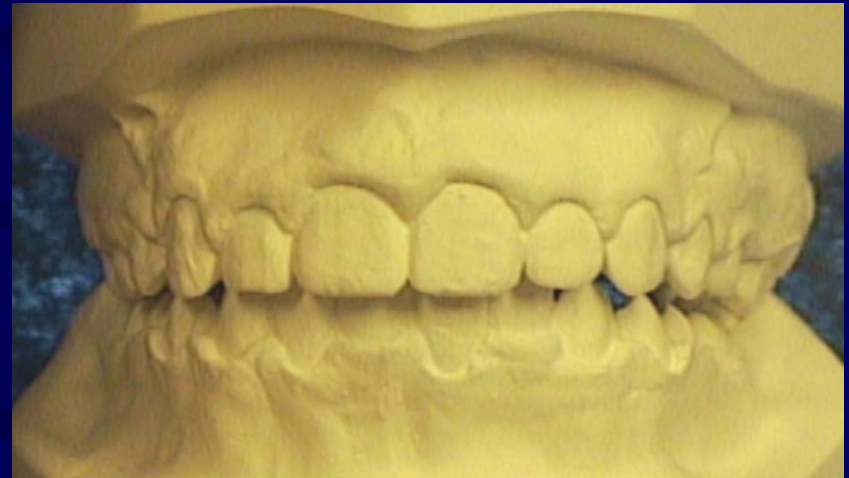
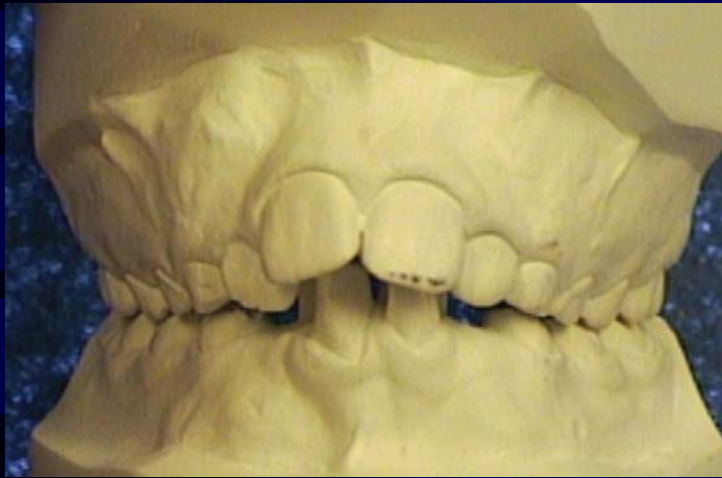
- Patient had poor oral hygiene
- Due to very thin cortical bone I had to transpose lower laterals for centrals and centrals for laterals

•Ryan was a true soldier throughout the long treatment.

•It all turned out excellent and he has a beautiful smile.

You will make decisions as treatment progresses.

Patient's Comment



Ryan was very pleased at all stages.
His family is very happy!