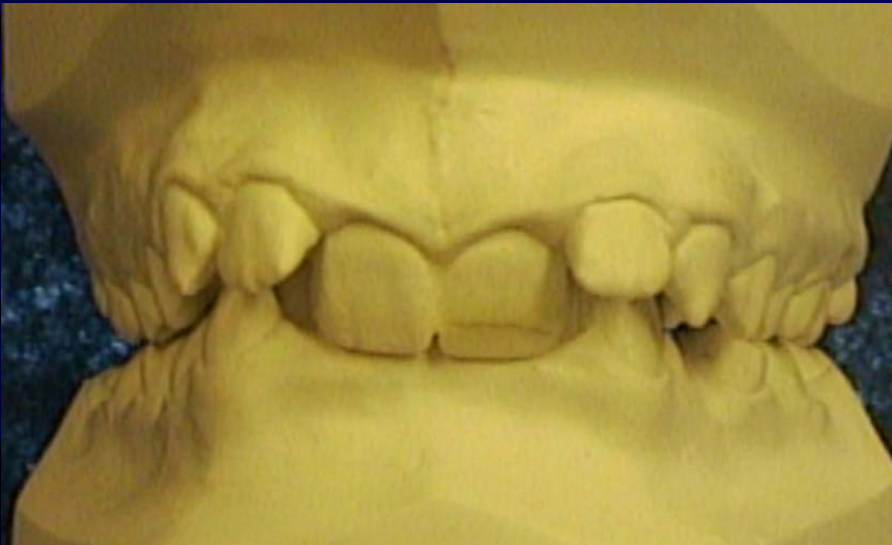

CASE PRESENTATION

**Provided by a General Dentist
from
Trinity Bay, Newfoundland**

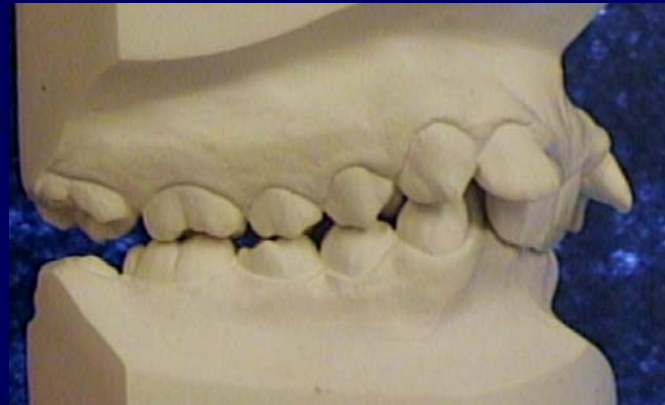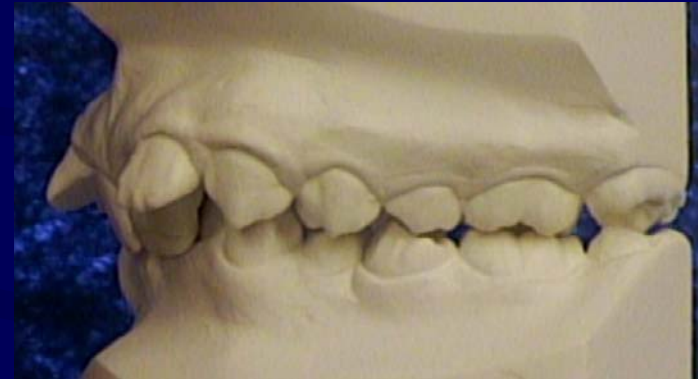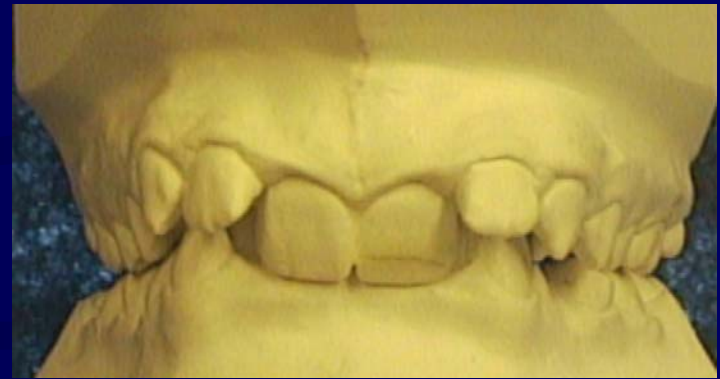Class II Division II

Shenise: 10 years of age



Pre-Treatment

- **Dental:**
 - Class II Division II
 - Retrusive Mx Centrals
 - 100% Deep Bite
 - Deflection into class II
 - Good Prognosis for Wisdom teeth

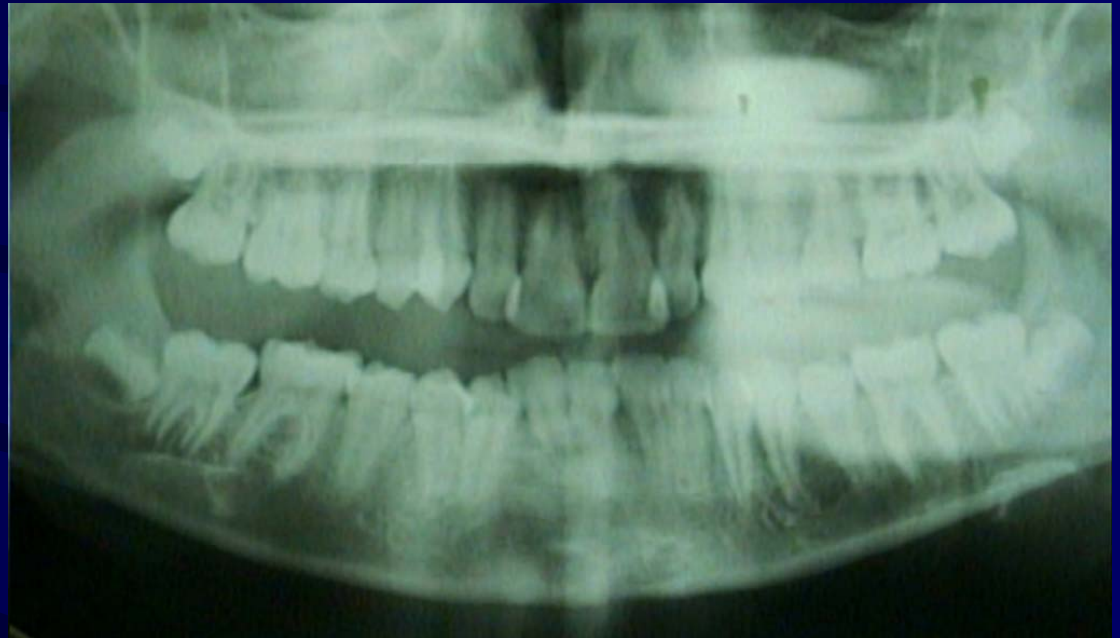

The Maxilla is the Criminal

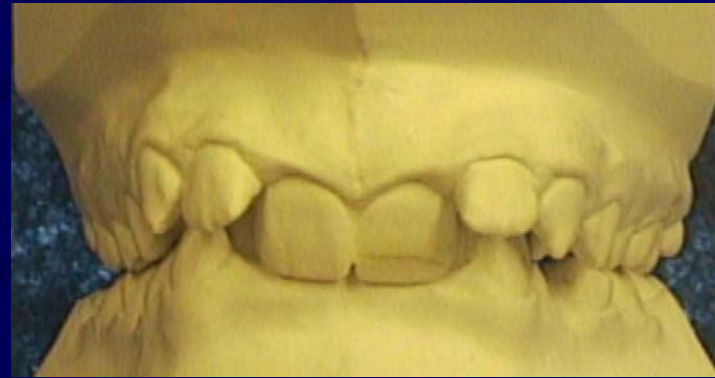The victim is the Mandible

Pre-Treatment Panorex

- The prognosis for 2nd molar replacement is good.
- The roots of the wisdom teeth have not formed and they are in good position.



Treatment Objectives



- Expand the Constricted Arches
- Torque the Retrusive Mx Central Incisors
 - Increase Vertical
 - Correct A-P
 - Retention

Treatment Plan

Phase I:

- 2nd Molar Replacement in all four quadrants
 - Mx 3-Screw Anterior Sagittal
 - Md Sagittal

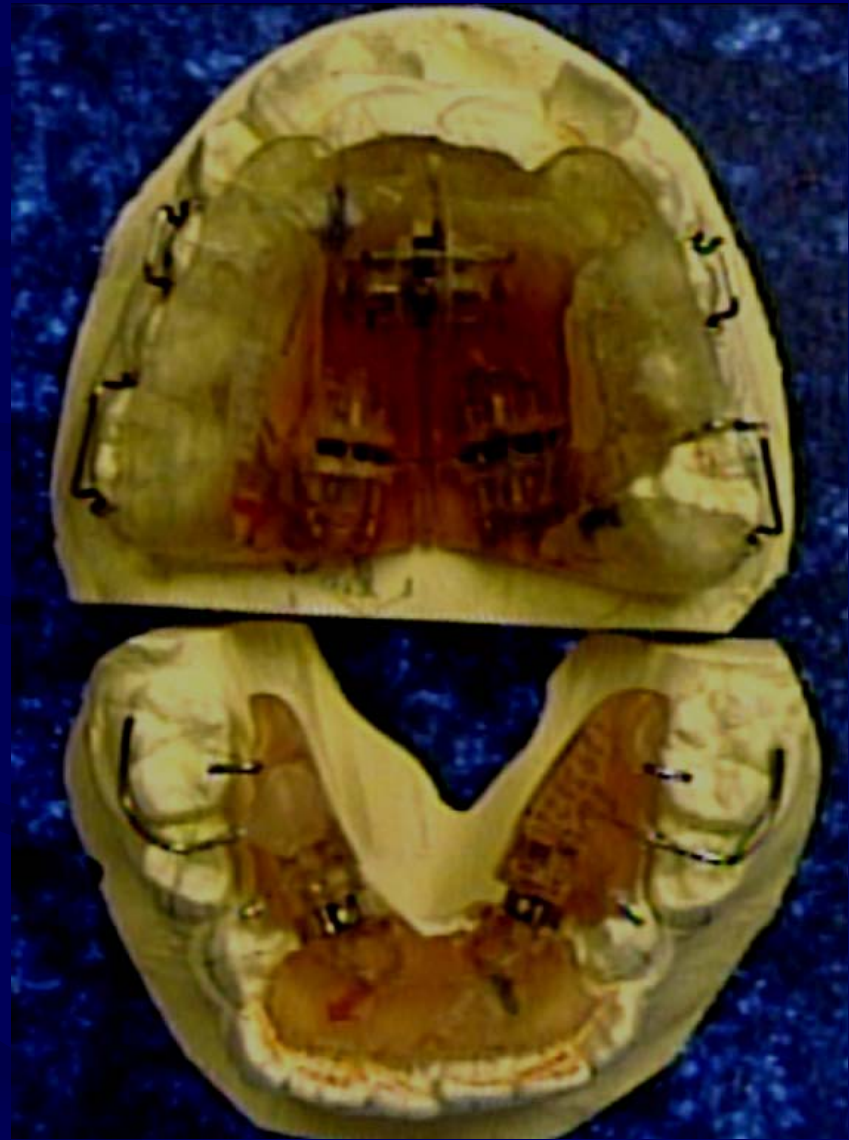Phase II:

- Fixed Bracket Therapy
 - Rick-a-nator

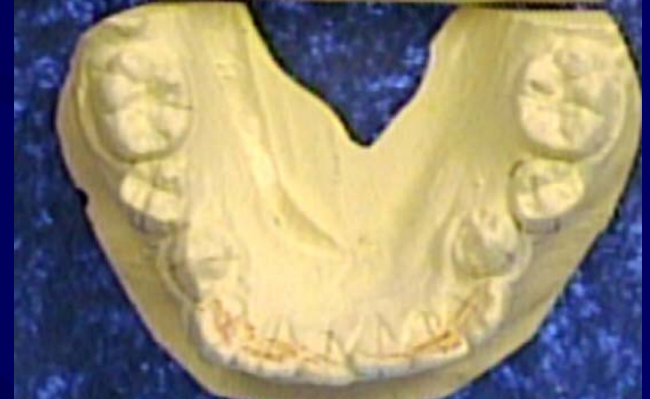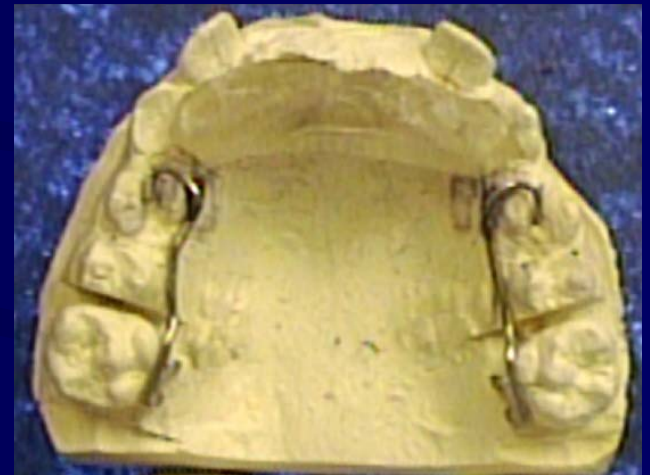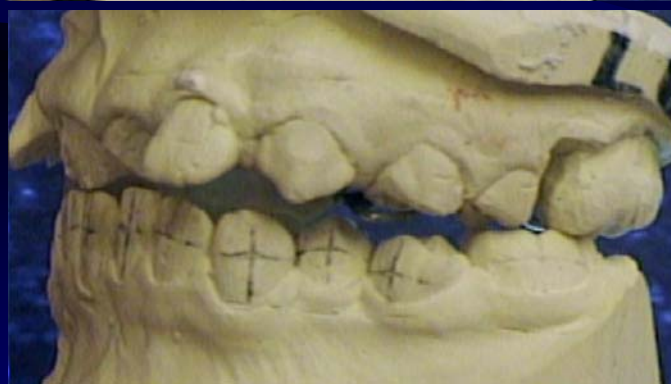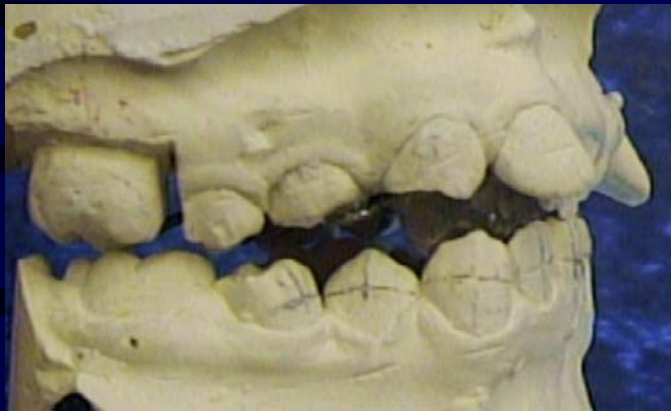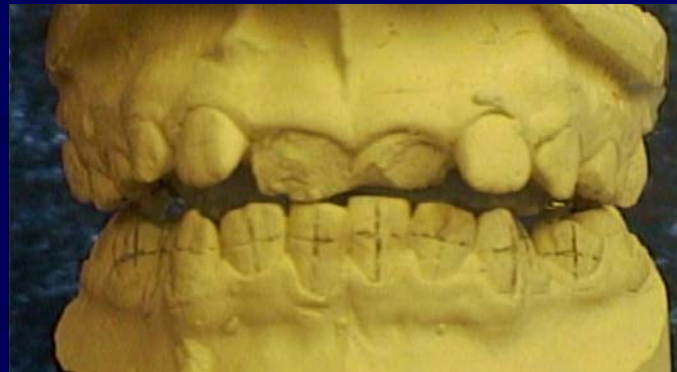Retention:

- Hawley Retainers or a Bionator I

Mx & Md
Sagittal



Fixed Bracket Therapy & Rick-a-nator



Case Treatment Summary

Shenise: 10 years of age

Phase I: 4 months

- 2nd Molar Replacement in all four Quadrants
 - Mx & Md Sagittal

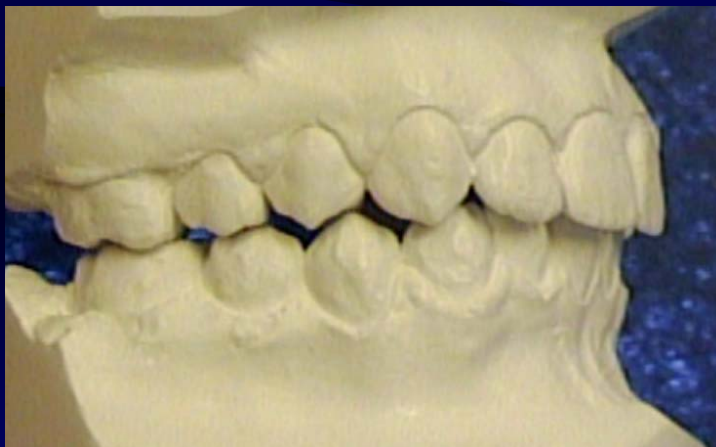
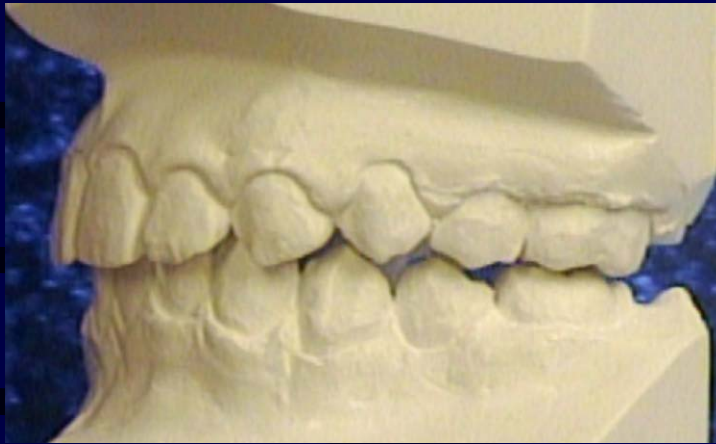
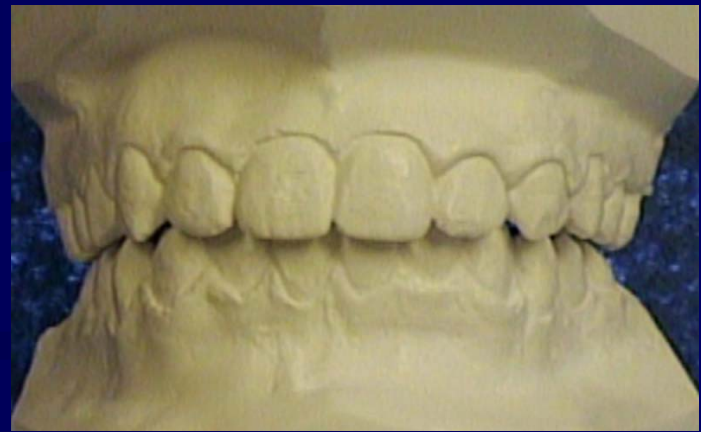Phase II: 8 months

- Fixed Bracket Therapy
 - Rick-a-nator

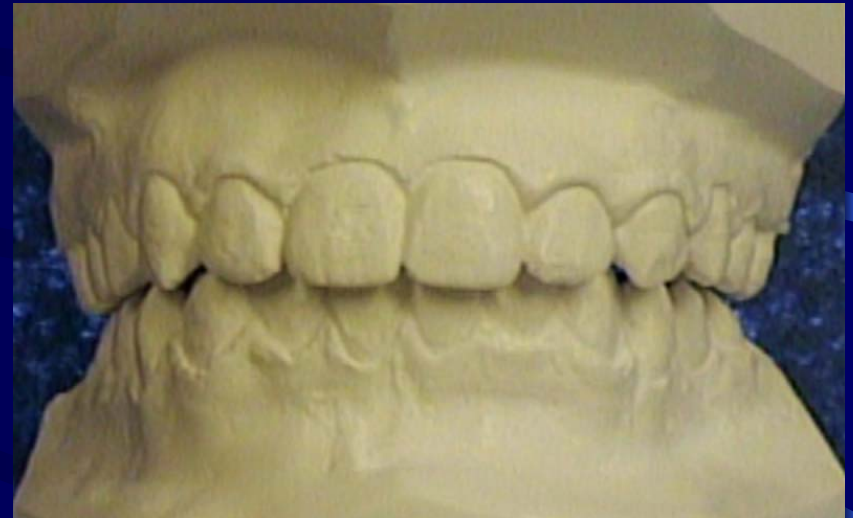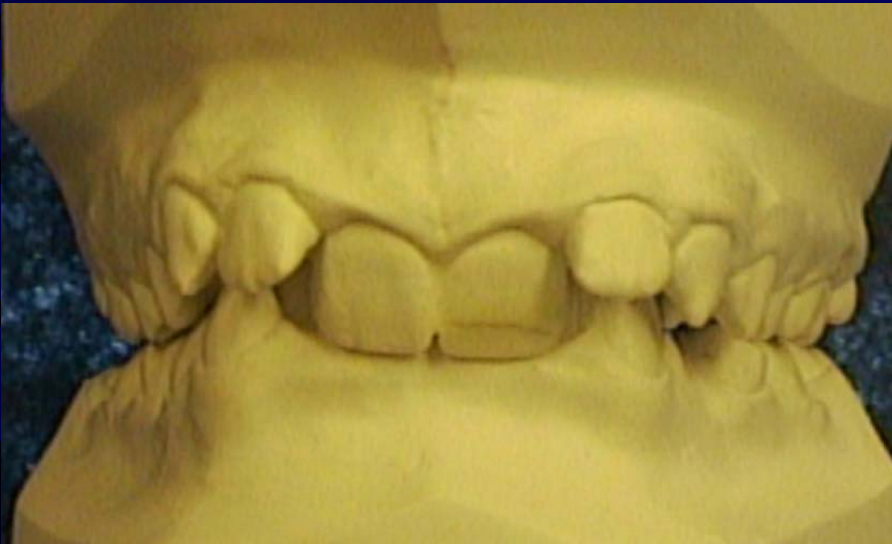Total Treatment Time: 12 months

Retention: Hawley Retainers

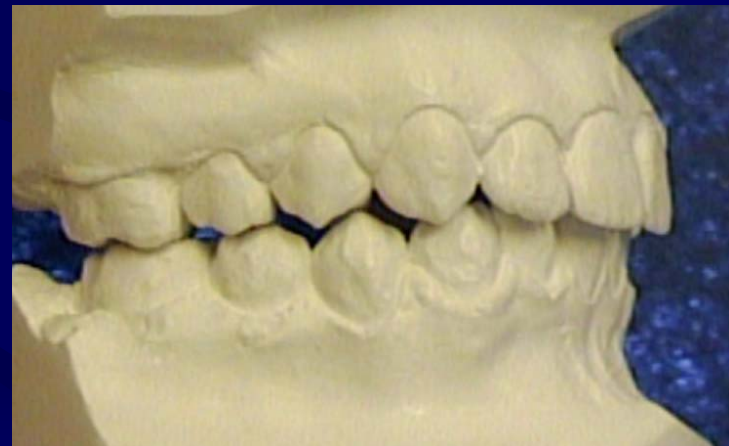
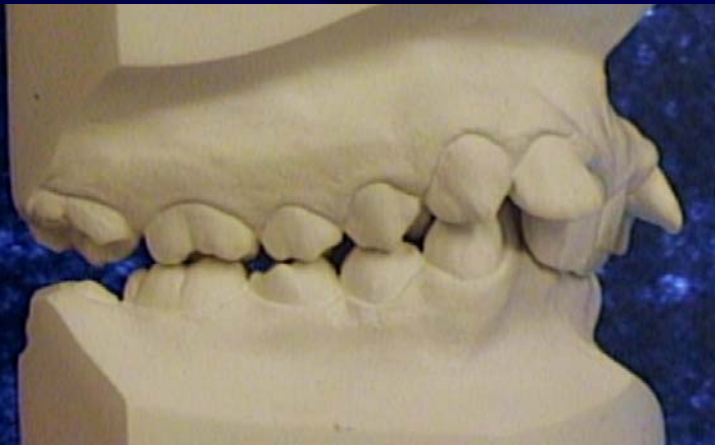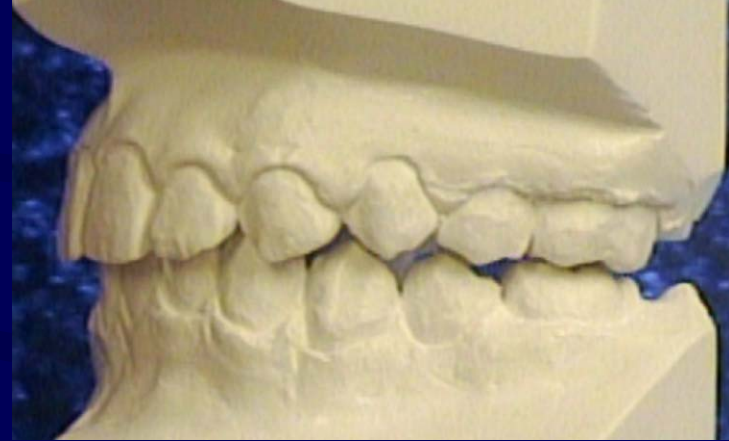
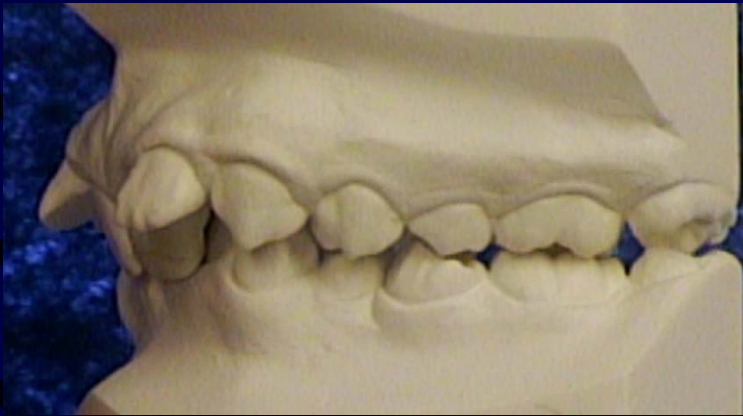Finished Treatment



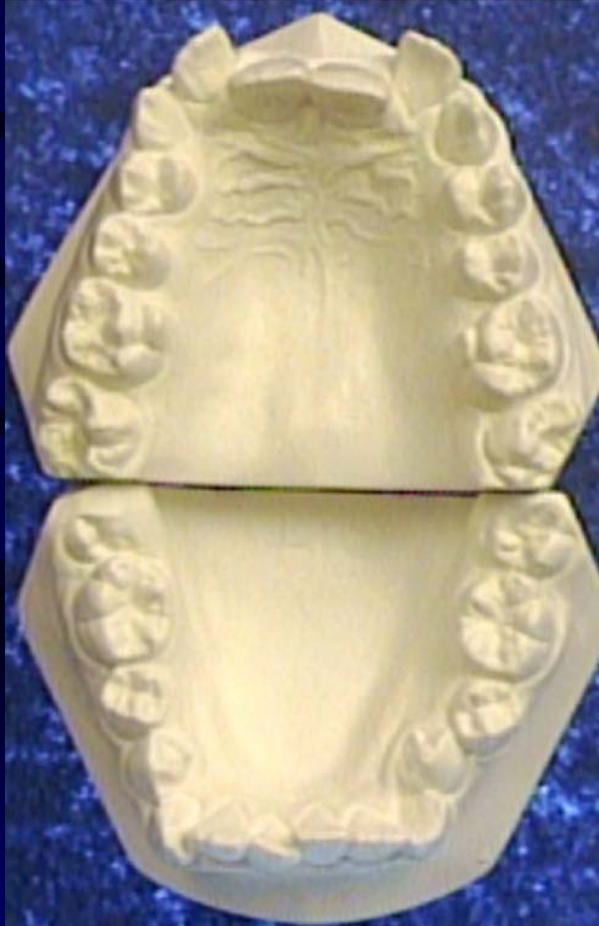Pre & Post Treatment



Pre & Post Treatment



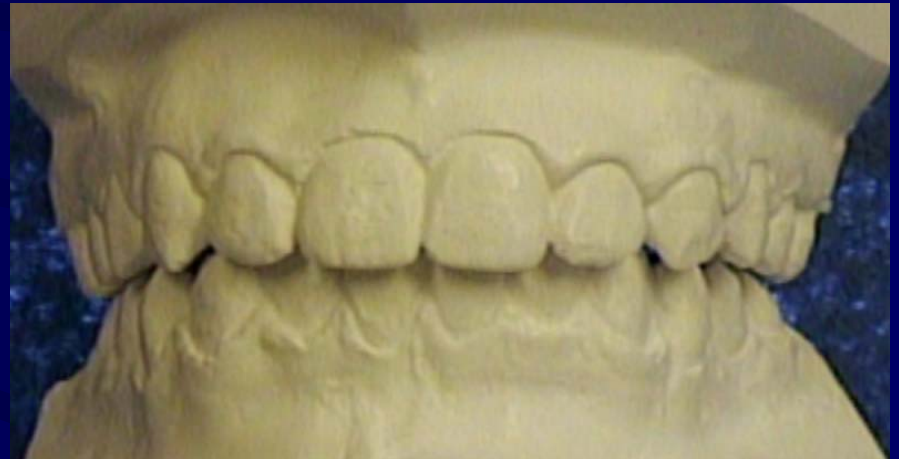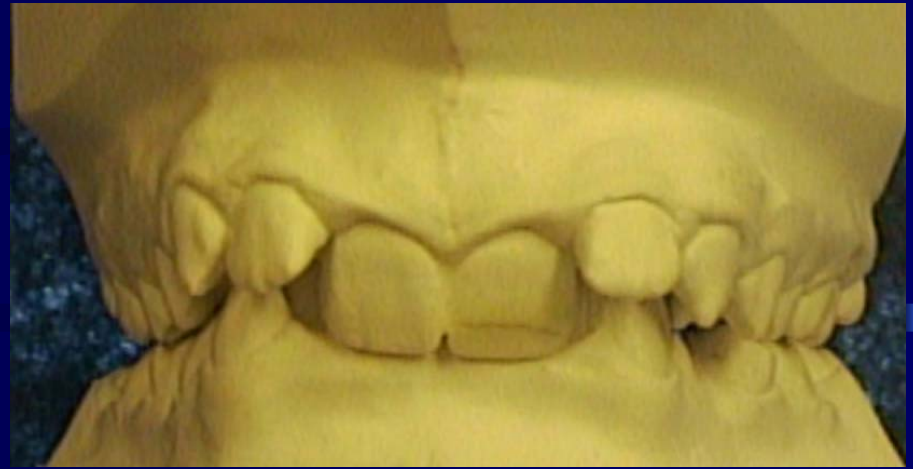Pre & Post Treatment



Doctor's Comments

- Shenise was a bit of a problem with removable appliances
- Not certain the patient was wearing or activating the appliance as prescribed - problems turning screw
- Patient was not very compliant at the beginning of fixed bracket therapy - brackets were coming off!
- Patient required a Root Canal on Upper Right Lateral
 - she bumped the tooth during treatment
- **Slow start but good results!**

Patient's Comments



Shenise was very happy and so
were her parents!